

**Ophthalmic
Photographers'
Society
2021 Exhibit**



OPHTHALMIC PHOTOGRAPHERS' SOCIETY
EYE IMAGING EXPERTS



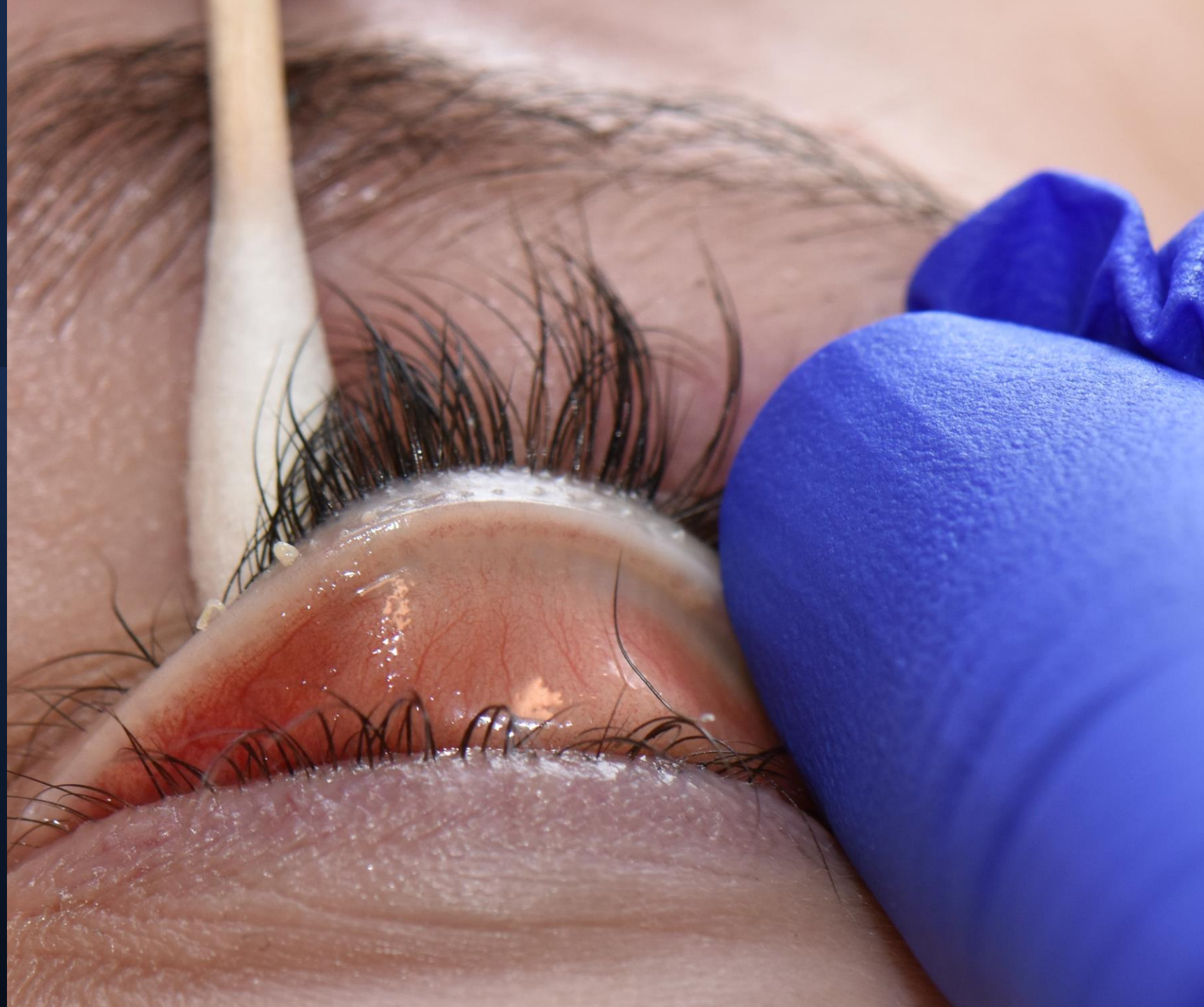Clinical Setting Photography



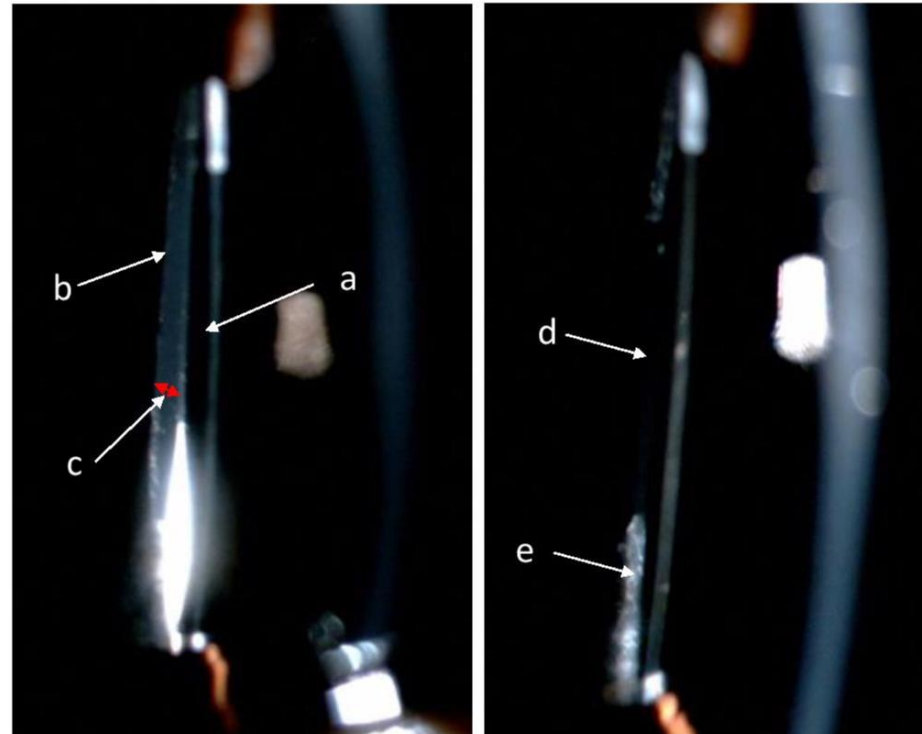
Meibomian Gland Dysfunction

Jessica Peterson CRA,
COA

Umass Eye Center



CAPSULAR BAG DISTENSION SYNDROME (CBDS) -DELAYED



CBDS (Phaco + PCIOL - 7 years ago):
a. PCIOL
b. Posterior capsule
c. Distended space between posterior capsule and posterior surface of PCIOL containing turbid fluid (red arrow heads)

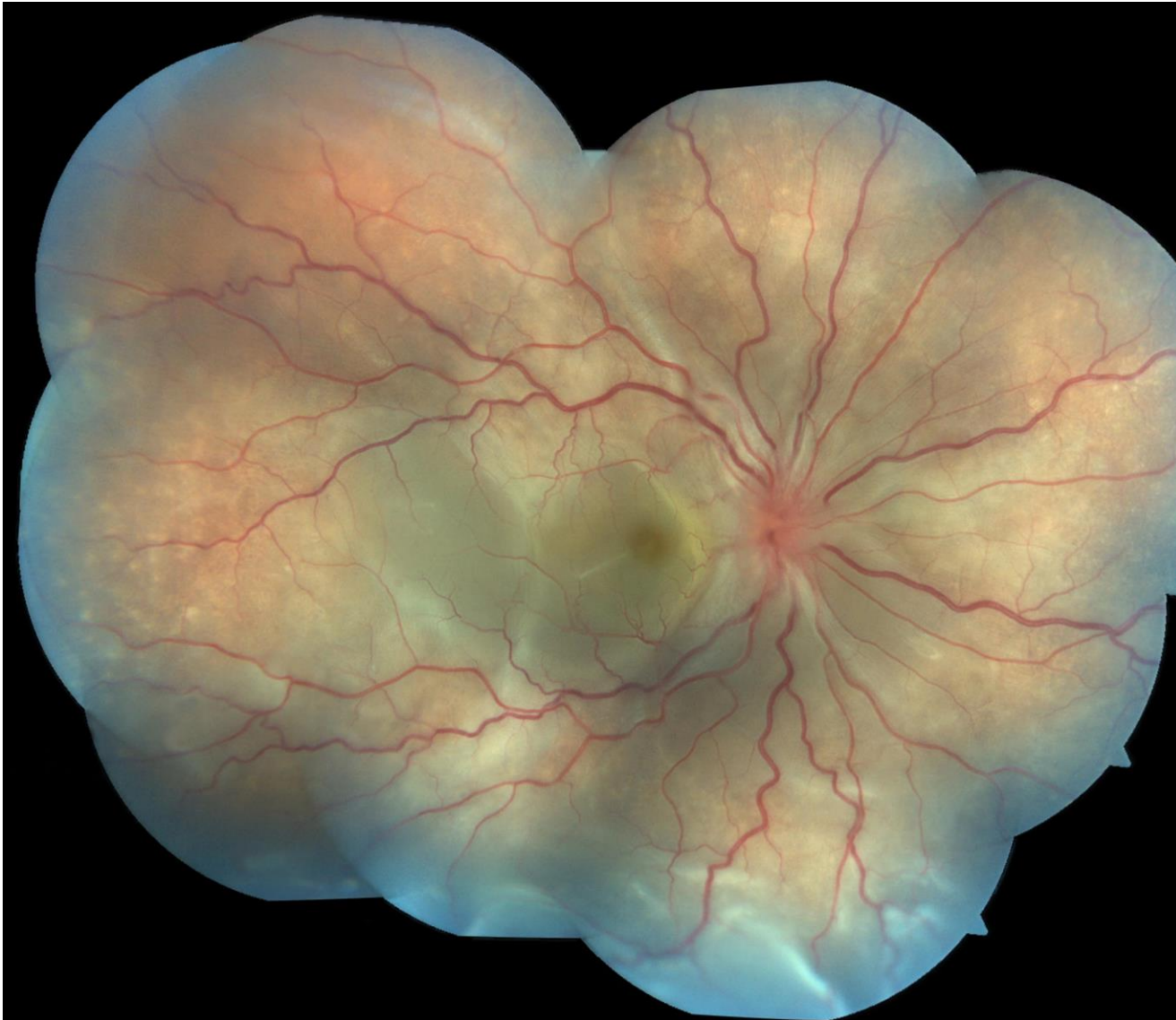Collapse of distended bag after YAG laser posterior capsulotomy:
d. Open posterior capsule, absent turbid zone
e. Posterior capsule sticking to posterior surface of IOL

Capsular Bag
Distension
Syndrome (CBDS)
Surinder Kumar
Haifa Eye Hospital



Composite

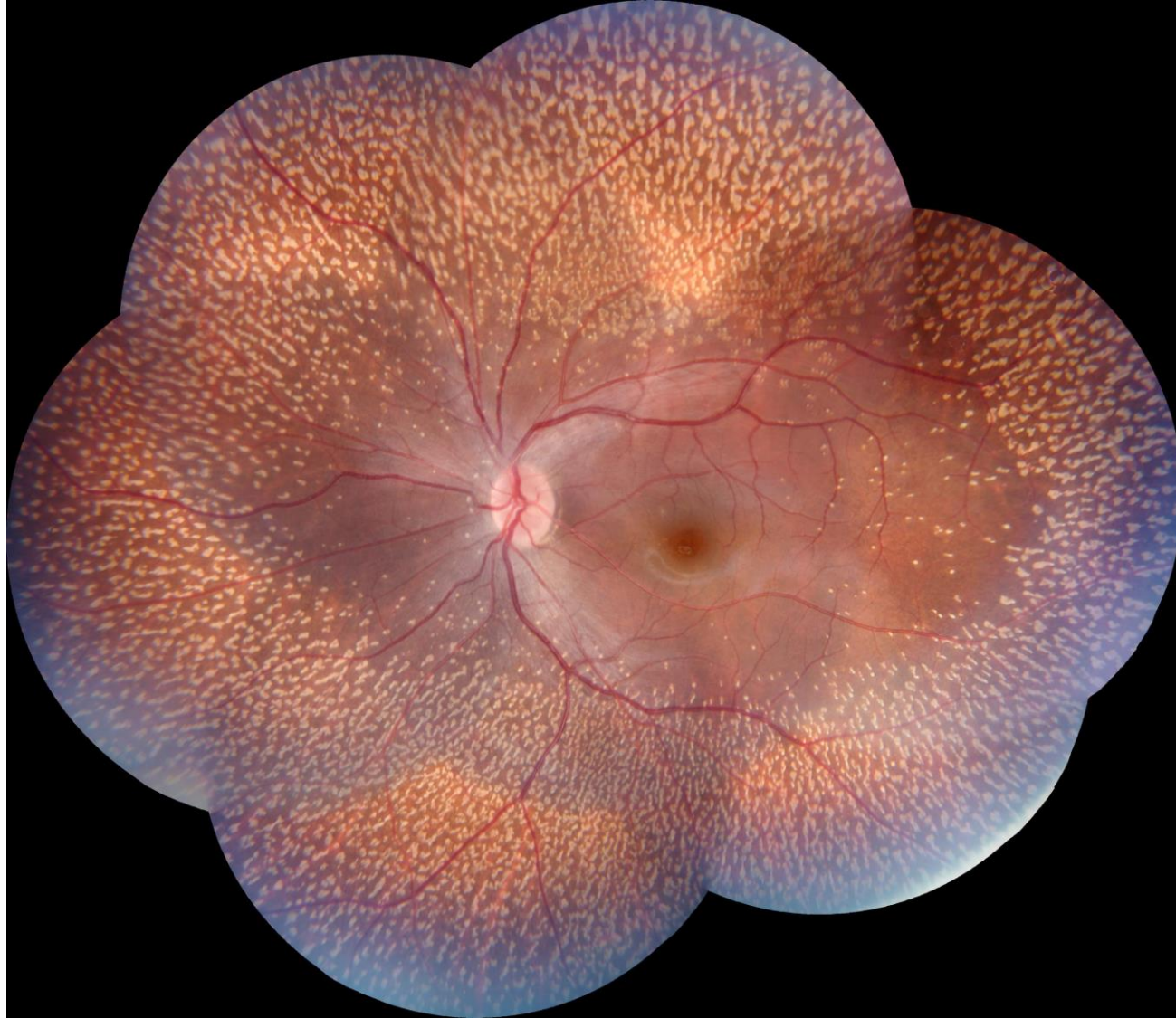



Vogt-Koyanagi-Harada Disease

Katie Lachut-Yevich
Virginia Commonwealth
University Health System





Benign Flecked Retina 2
John Leo
Rajan Eye Care Hospital Pvt Ltd

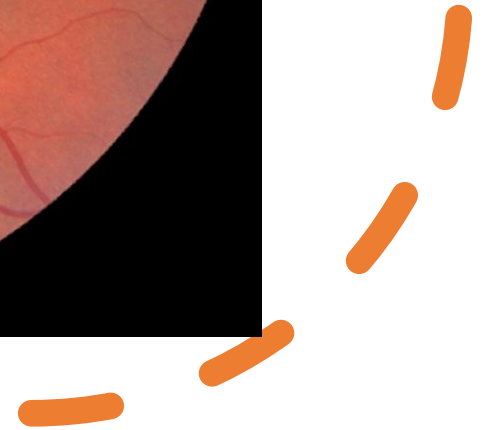
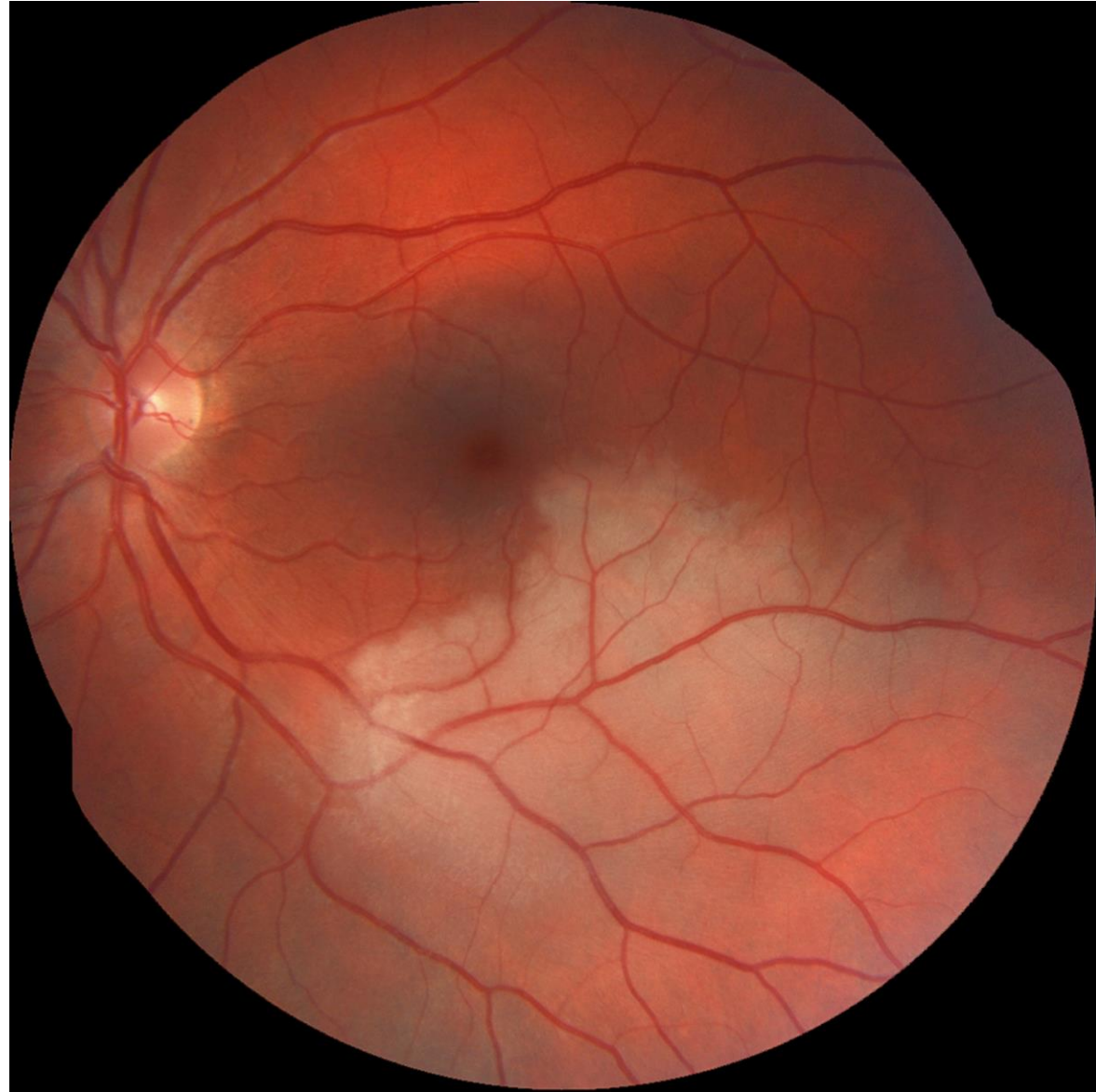

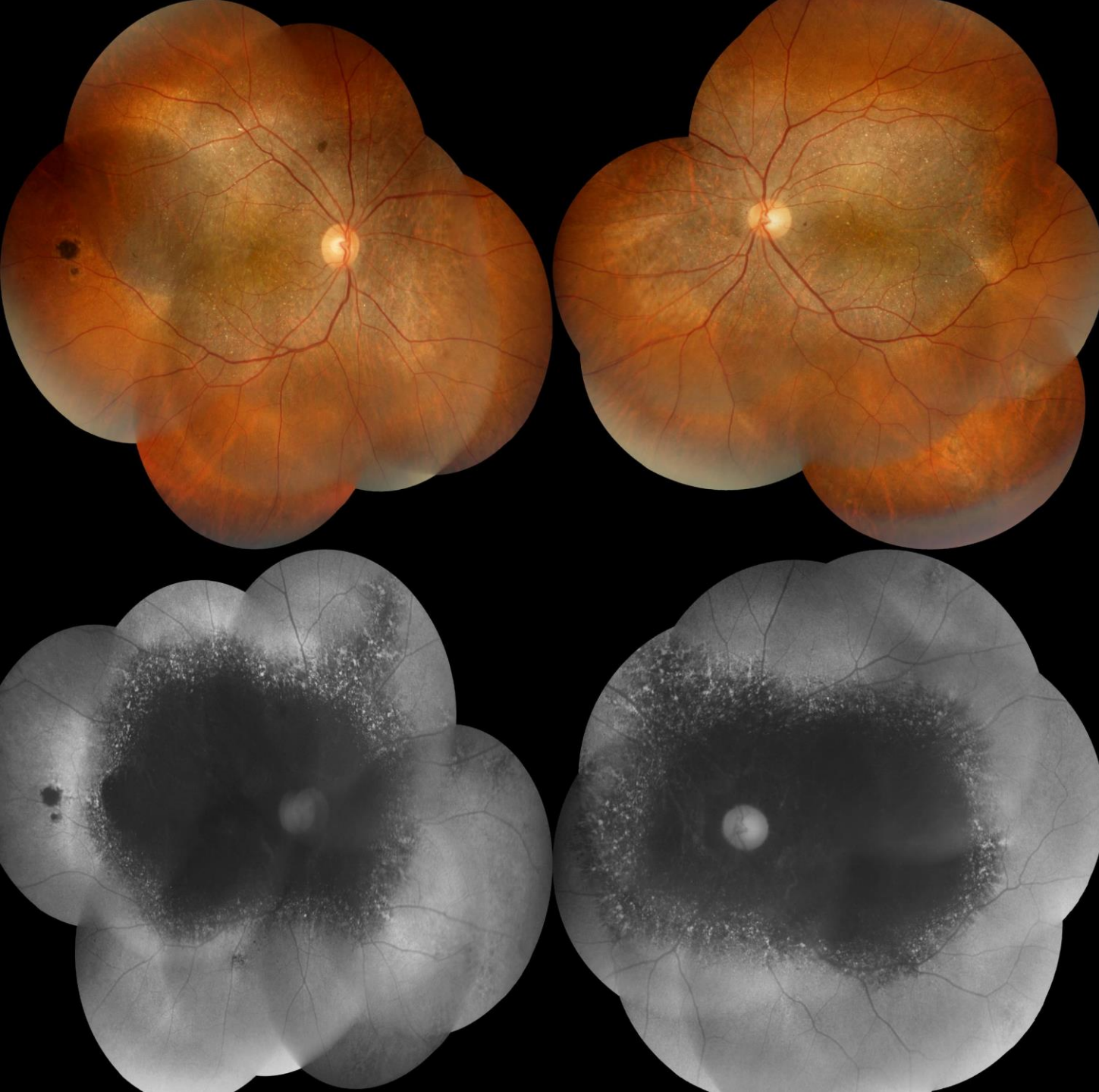
Brao

Katherine Lachut

Virginia

Commonwealth
University Health
System





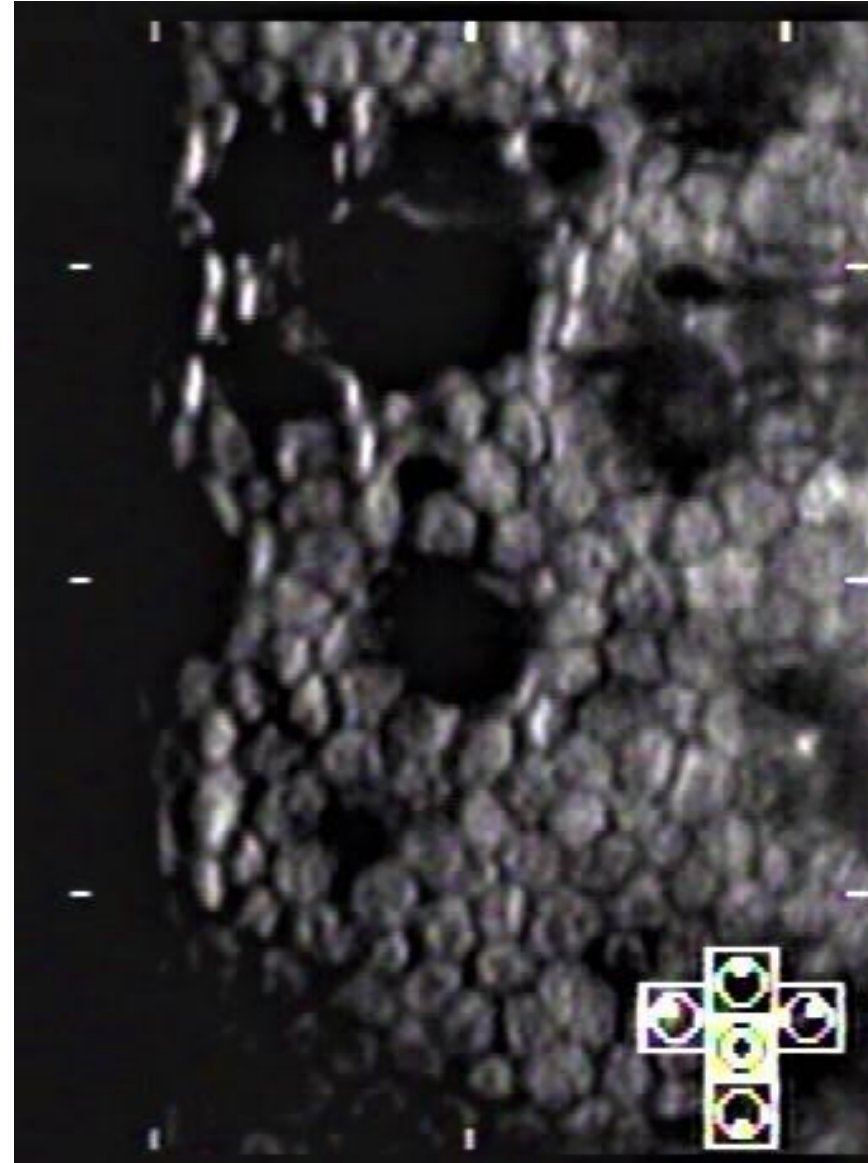
Bietti Crystalline Dystrophy 2
John Leo
Rajan Eye Care Hospital Pvt Ltd



Corneal Endothelial Photography

Cornea Guttata


Shymaa Mohamed
Kresge Eye Institute



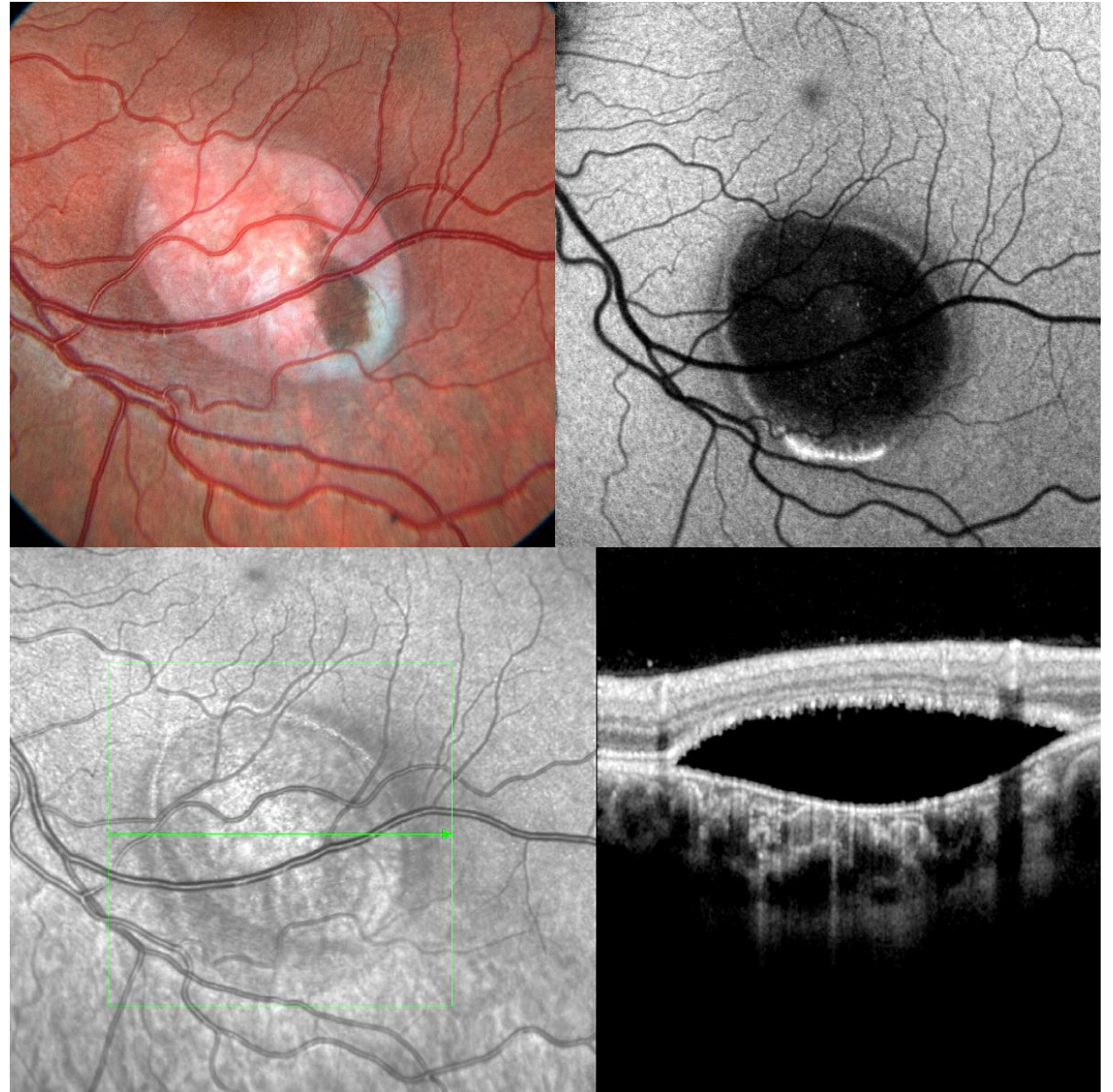
Cross Categories



Foreign Body
Kasi Sandhanam
Singapore National
Eye Center



Serous Detachment Ronald Hall Retina Specialty Institute

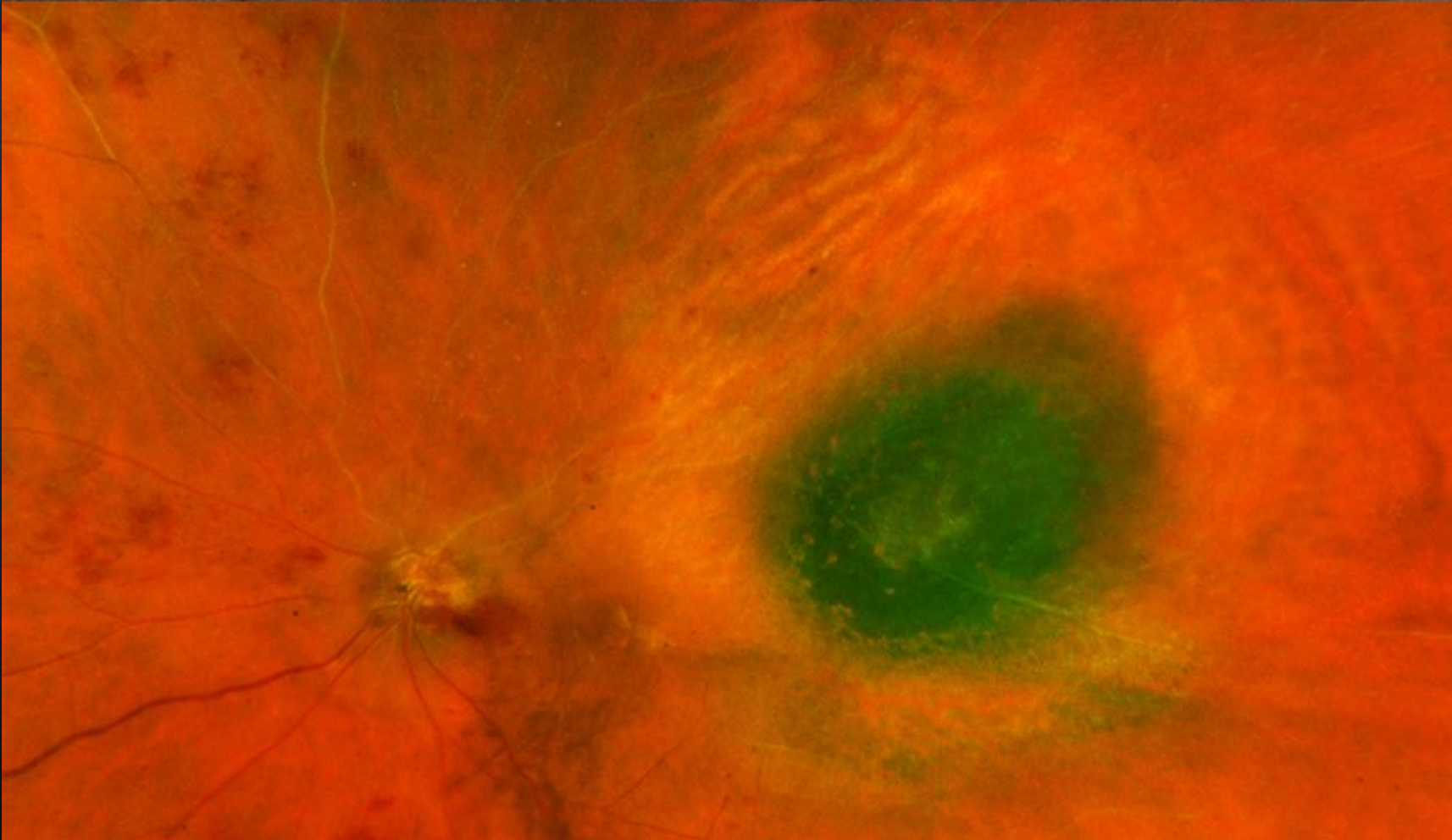
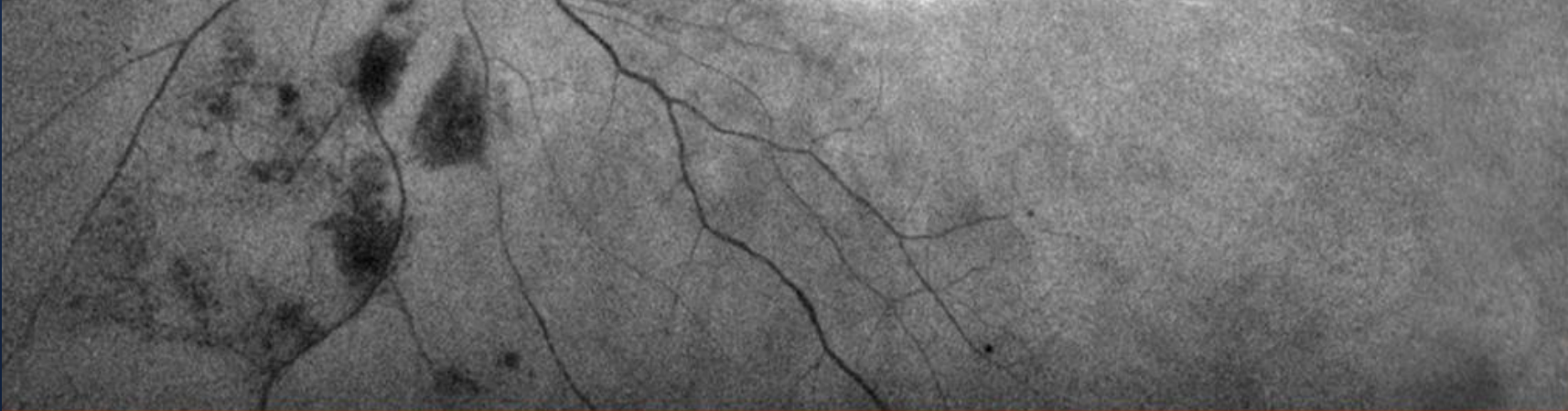


Choroidal Melanoma

Mark D. Clark

Wake Forest

University Eye Center

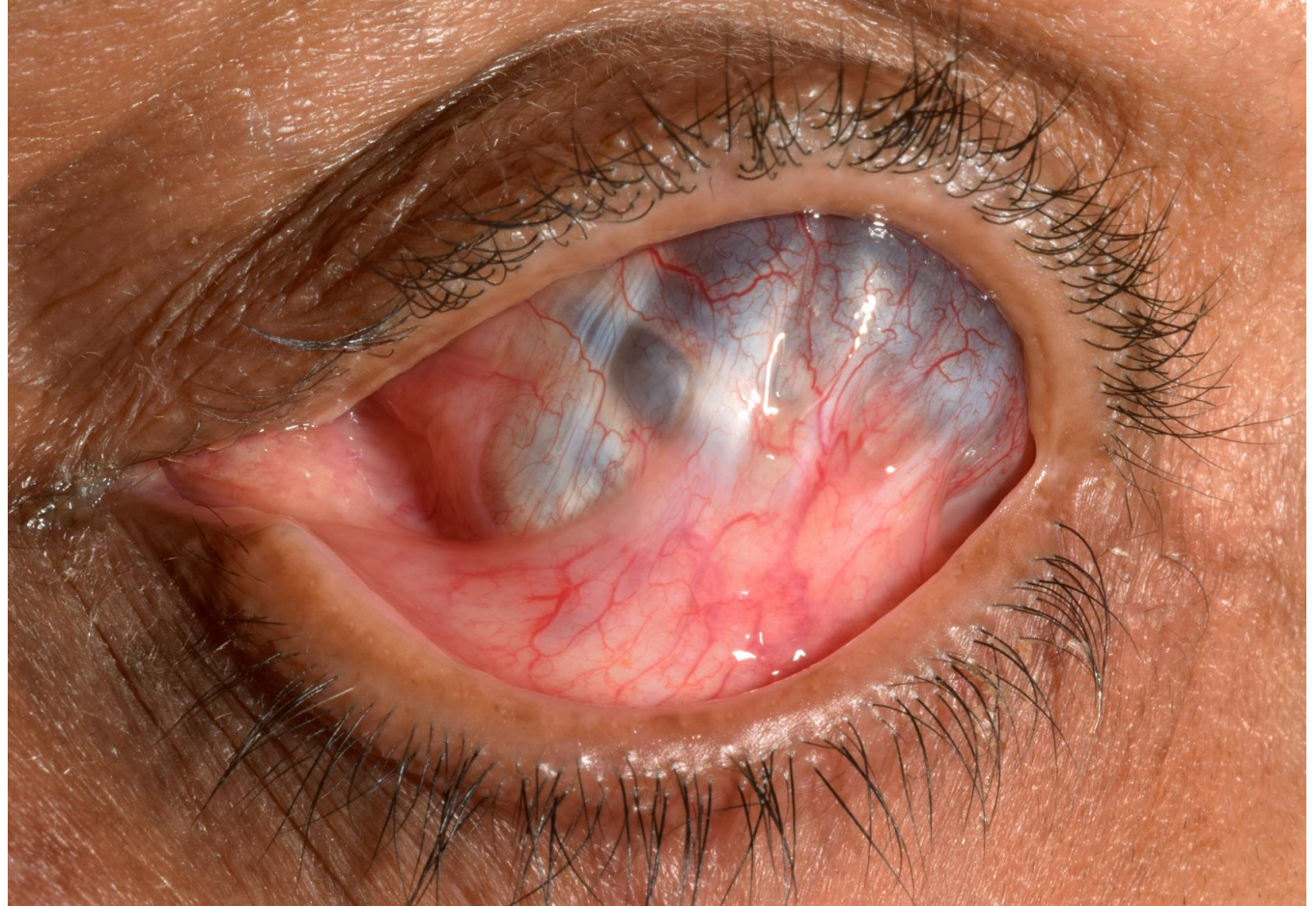


External Photography

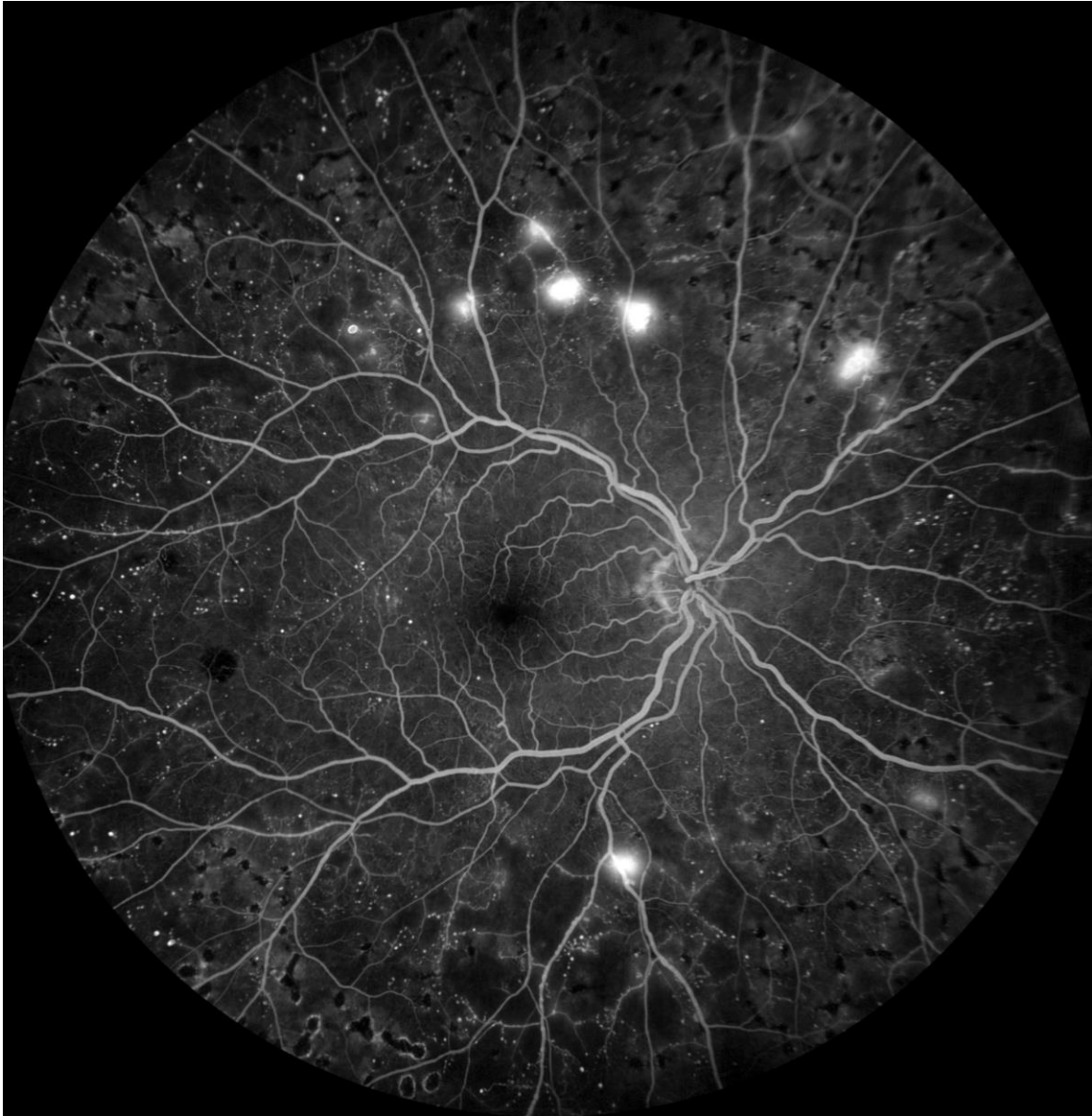


Vascularization over Implant

David T. Miller, CRA
Wake Forest Baptist
Health Eye Center



Fluorescein Angiography



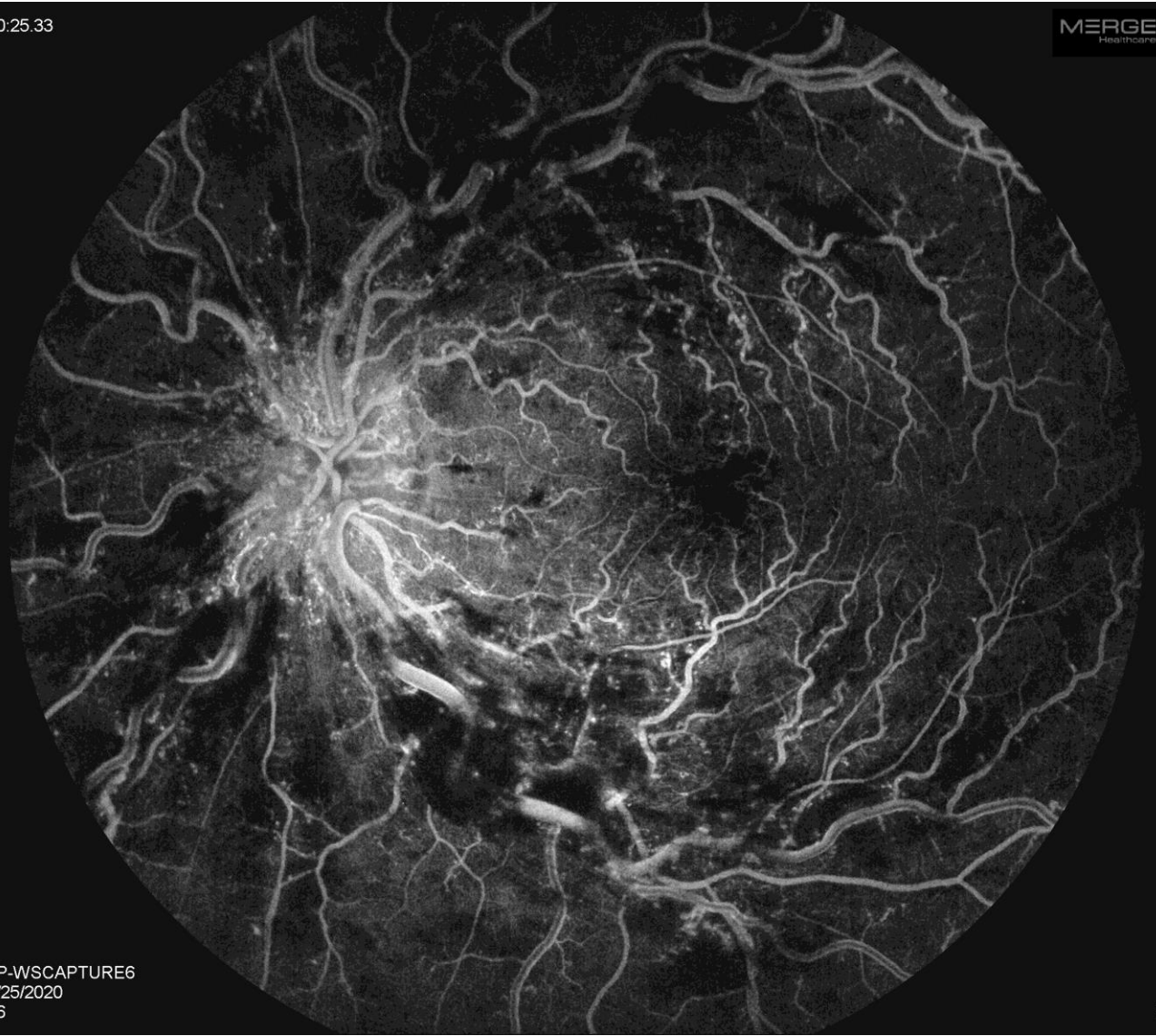
DM

Jennifer Ann Humenny,
CRA, OCT-C
Henry Ford Health
System



00:25.33

MERGE
Healthcare



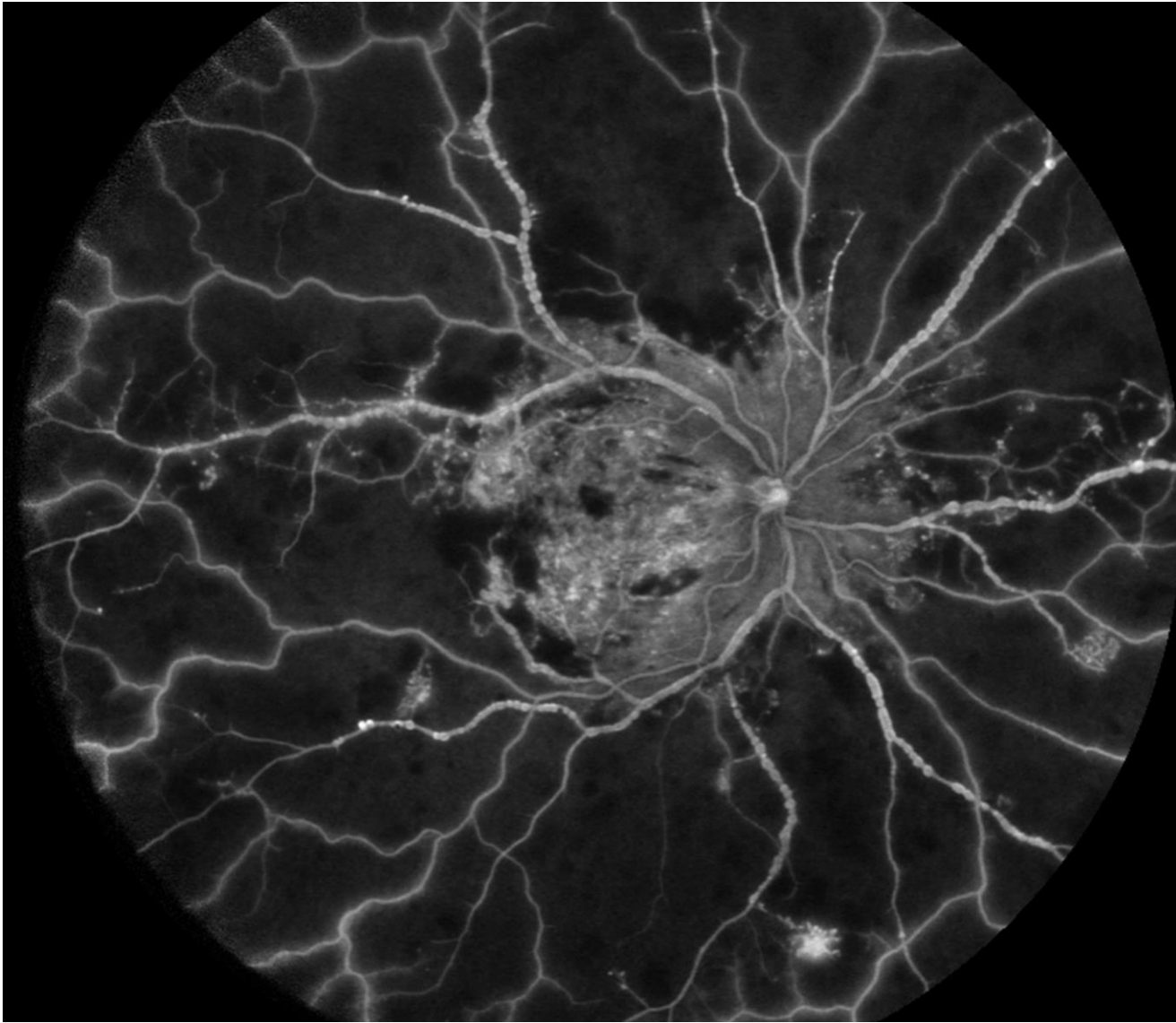
LP-WSCAPTURE6
8/25/2020
16

E

CRVO

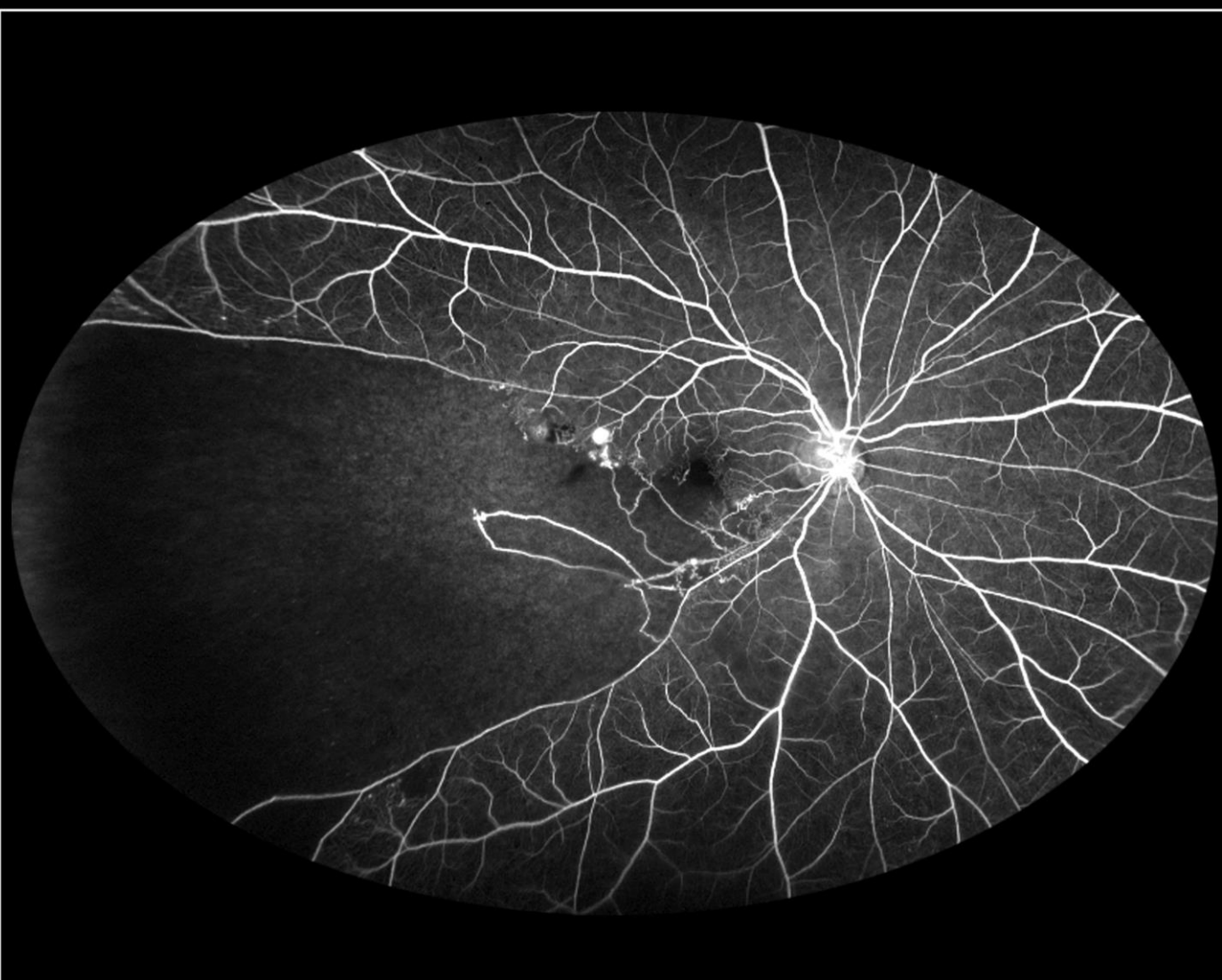
Lina Kristina Olsauskas
Illinois Retina
Associates






Leukemic Retinopathy
Darrin Landry, CRA, OCT-C
Eyecare Medical Group

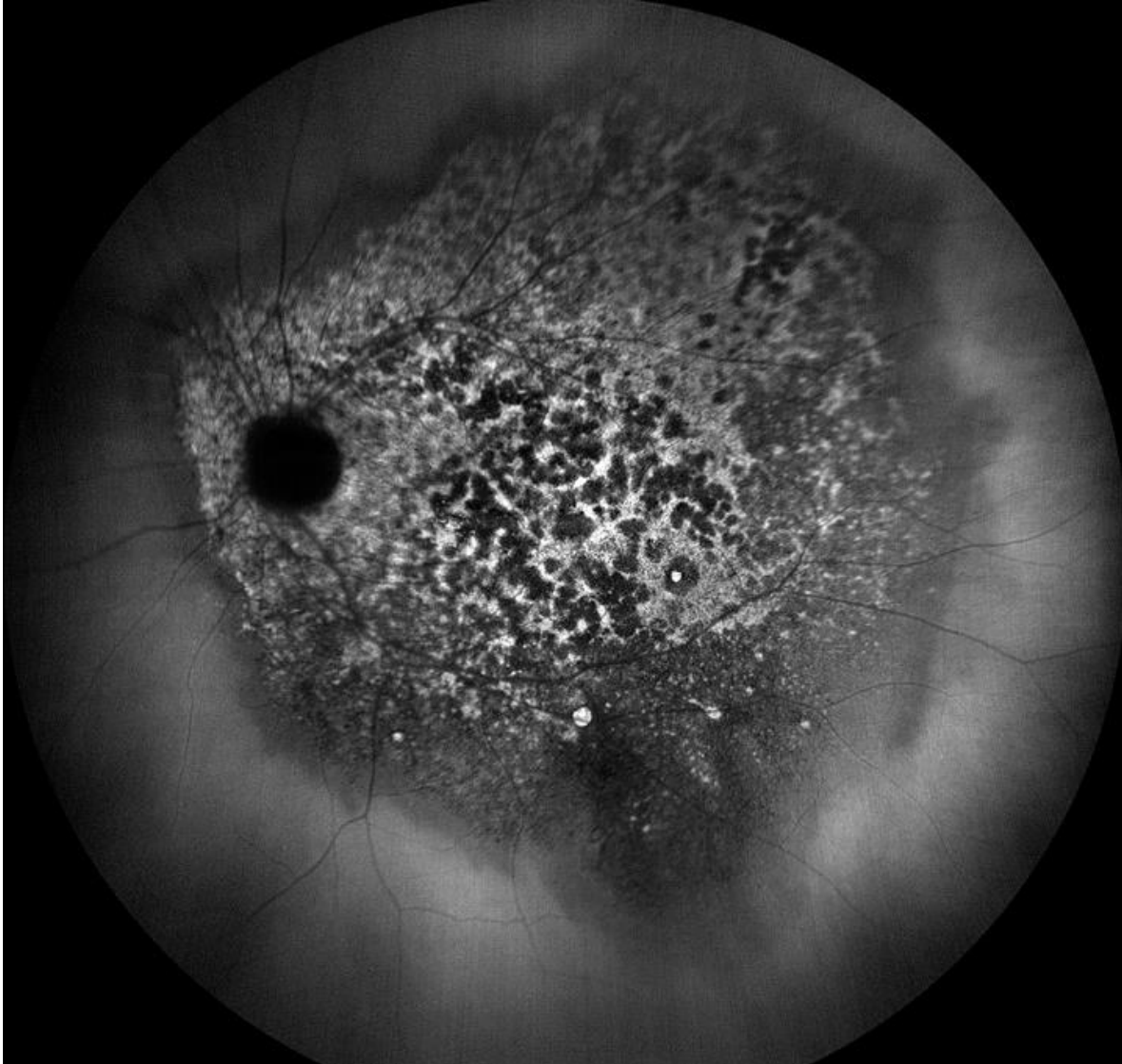




Ischemic Branch
Retinal vein occlusion
Kasi Sandhanam
Singapore National
Eye Center



Fundus Autofluorescence

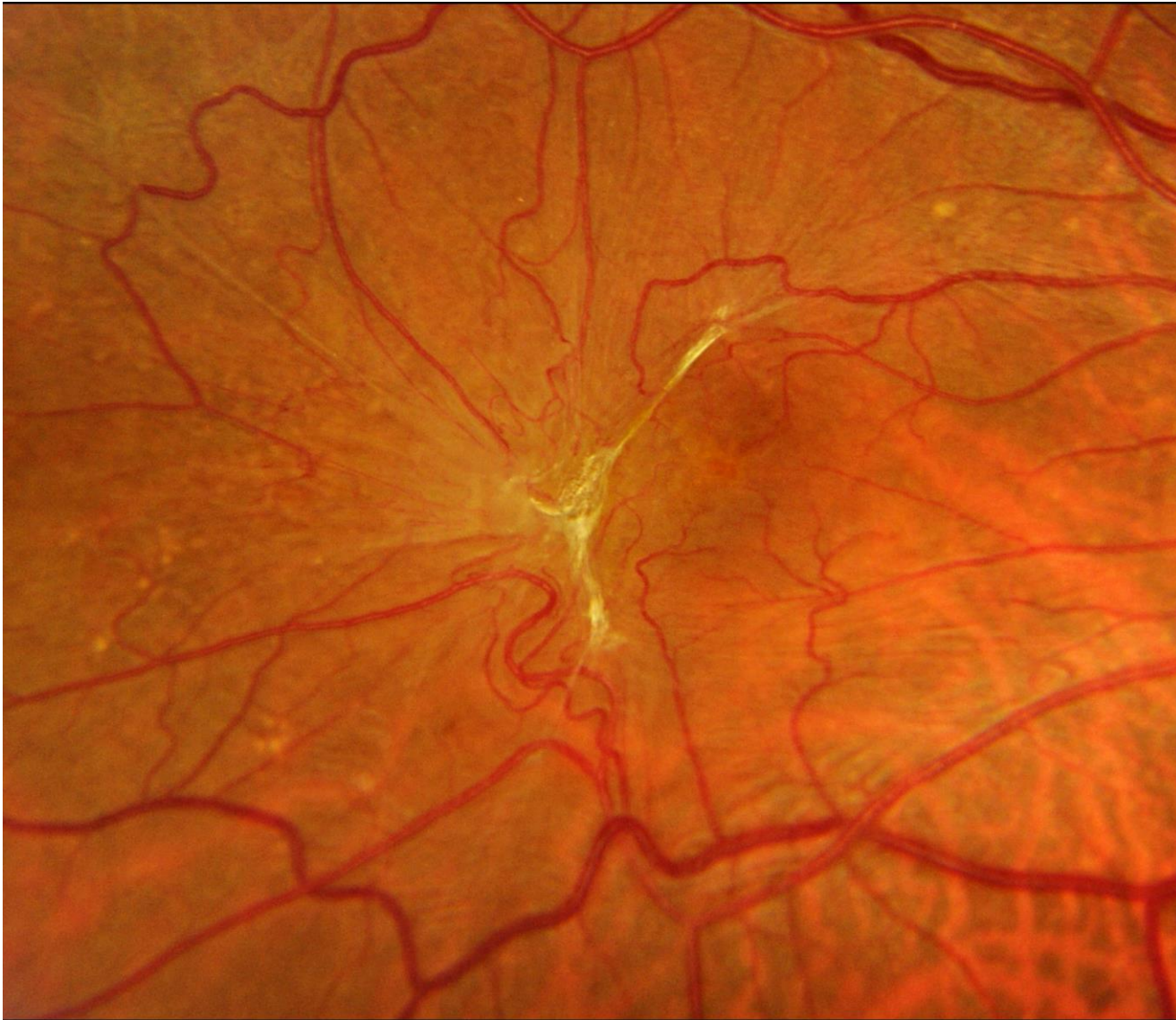

Choroidal Metastasis from Cutaneous Melanoma with Optic Nerve and Retinal Invasion

Philip Dockery
Shields and Shields, PC

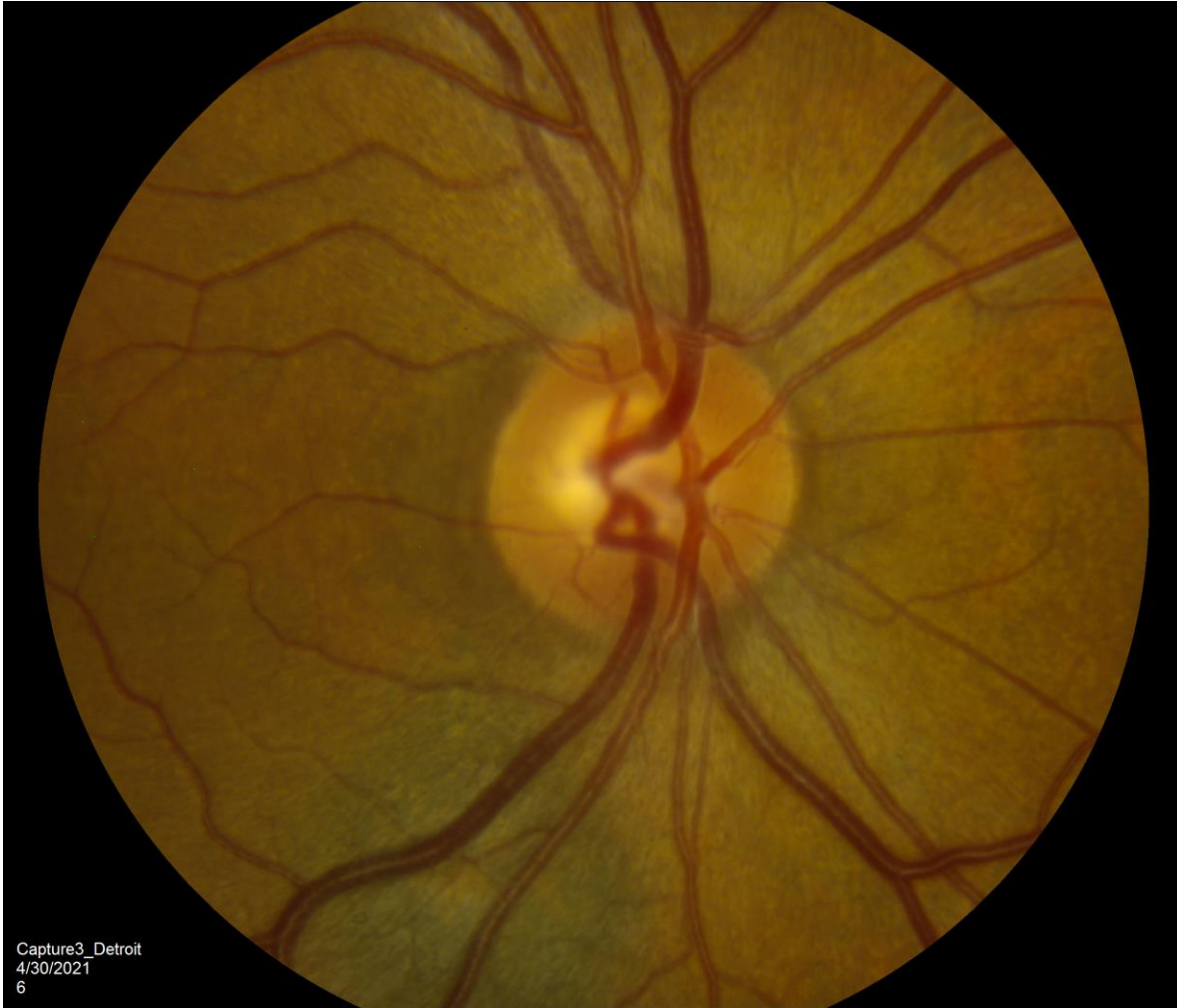

Fundus Photography, High Magnification, 20°



Epiretinal Membrane
Kasi Sandhanam
Singapore National Eye
Center





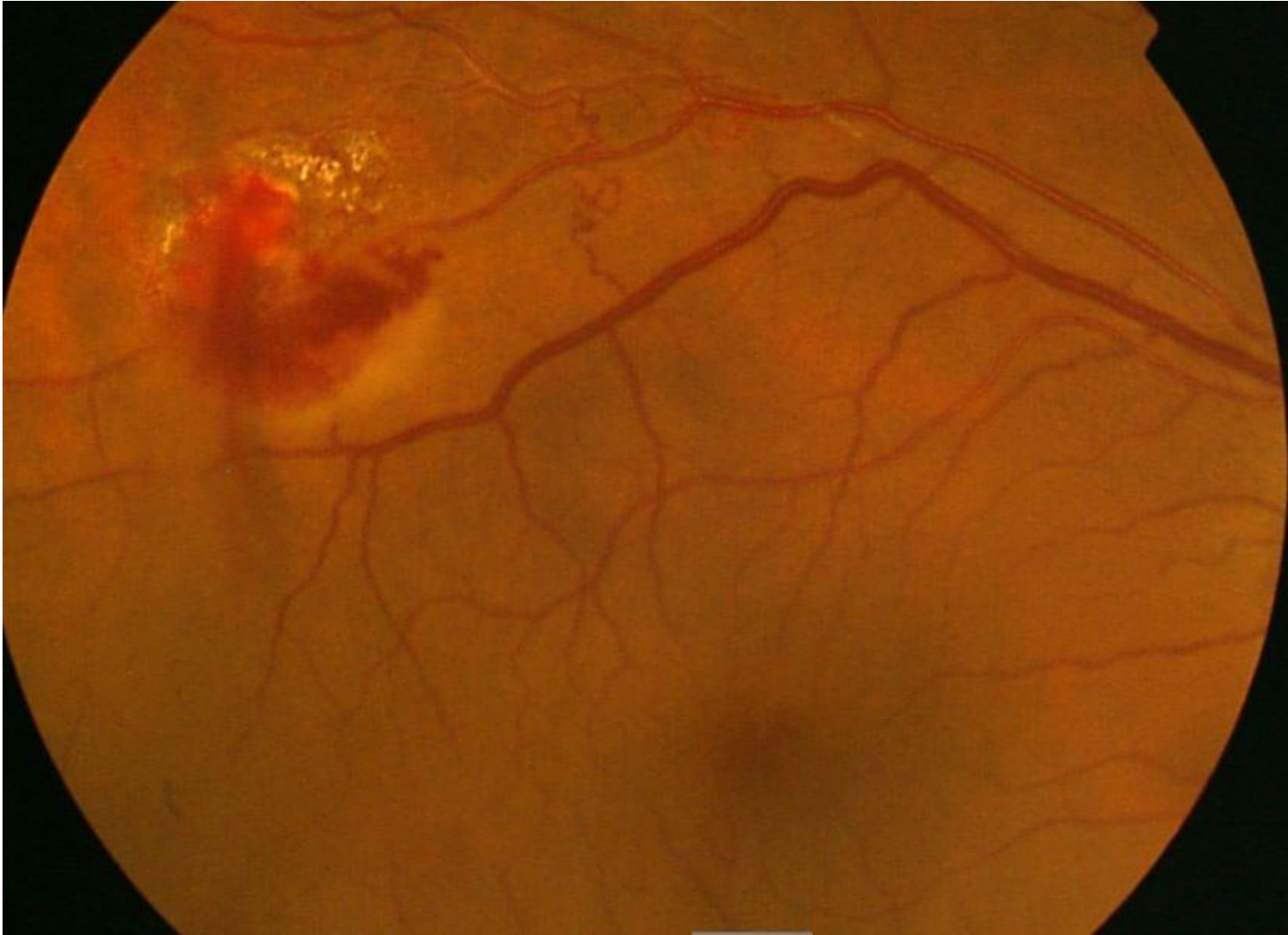Capture3_Detroit
4/30/2021
6

Choroidal Nevus

Shymaa Mohamed
Kresge Eye Institute



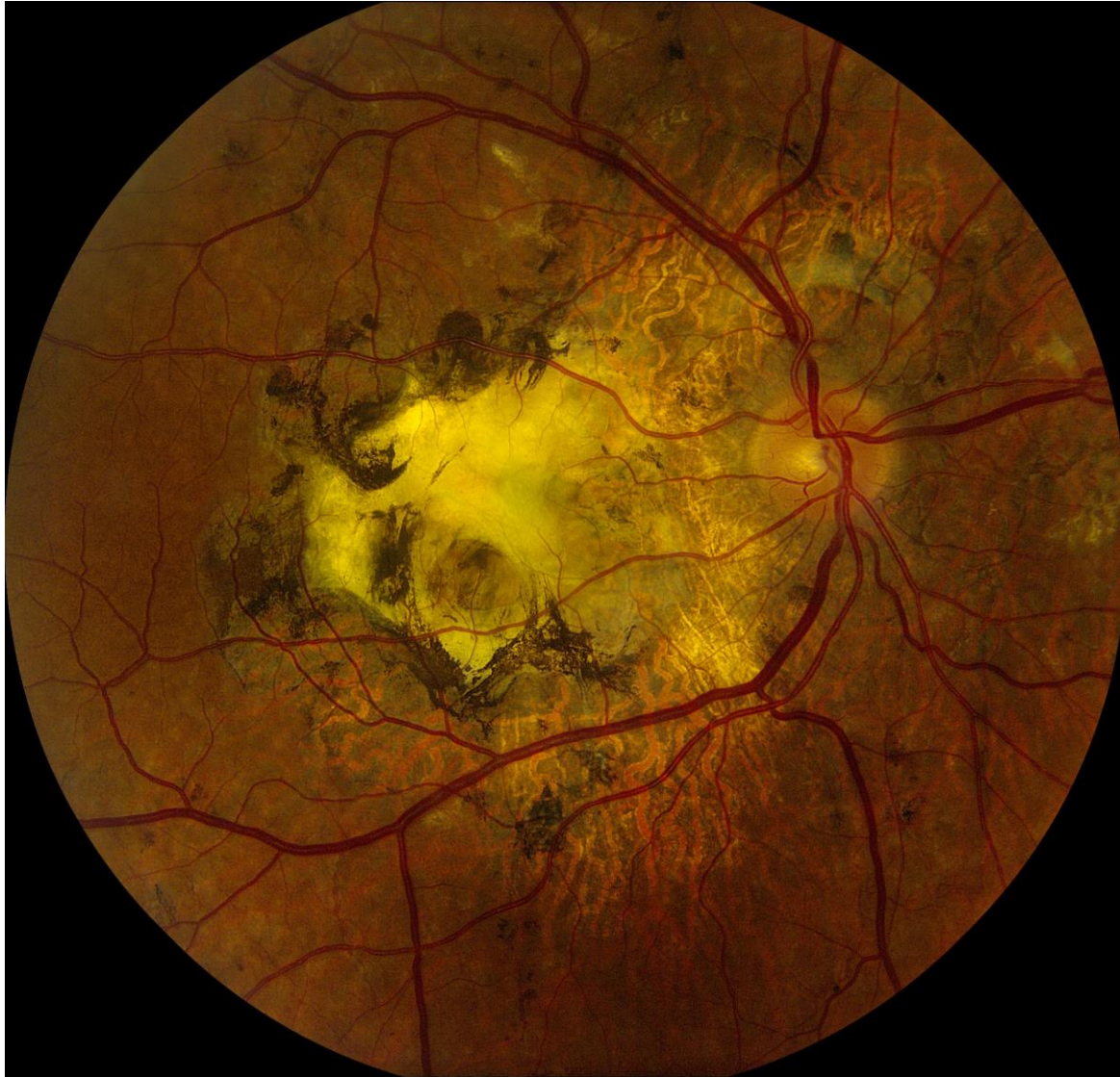Fundus Photography,
Normal, 30°-40°



Branch Retinal Vein
Occlusion (old)
Surinder Kumar
Haifa Eye Hospital



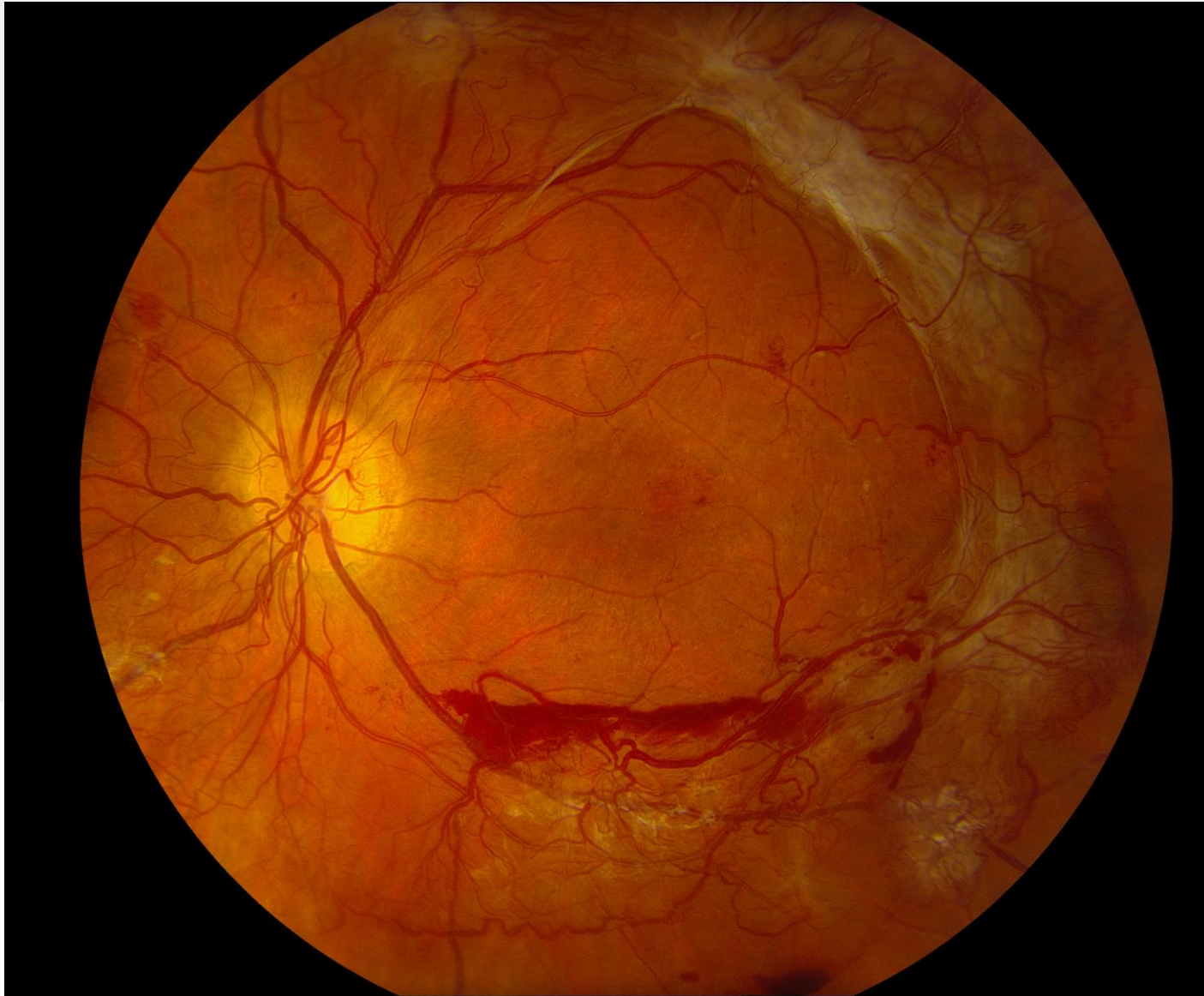
Fundus Photography, Wide Angle, 45°+



Atrophy

Jennifer Ann Humenny, CRA,
OCT-C
Henry Ford Health System

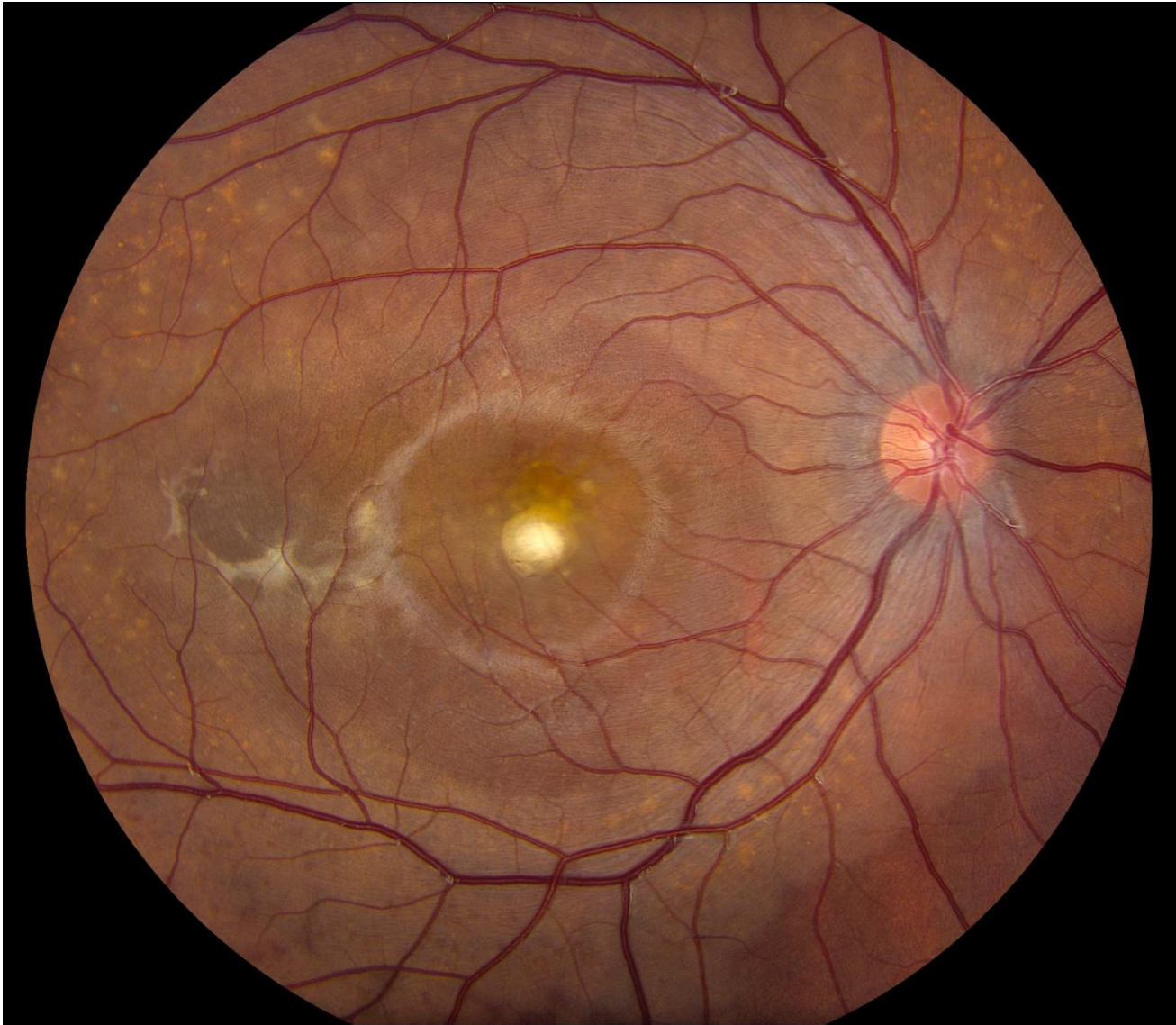




PDR 2

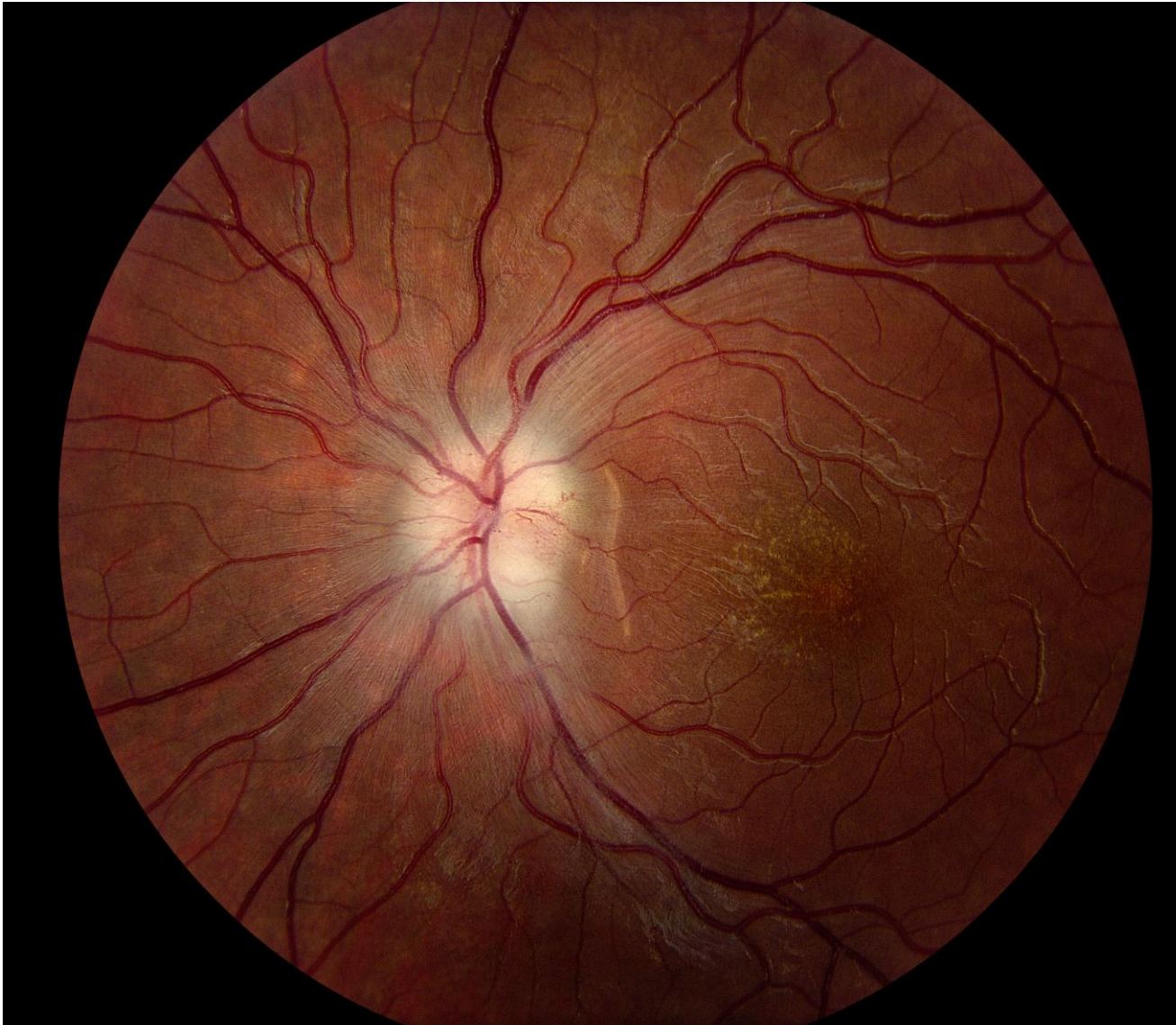
Jennifer Ann Humenny,
CRA, OCT-C
Henry Ford Health
System





Coats
Derick Ashley
Henry Ford Health
System






Papilledema
Bradley Stern
Henry Ford Health System



Gonio Photography





Cyclodialysis Clefts

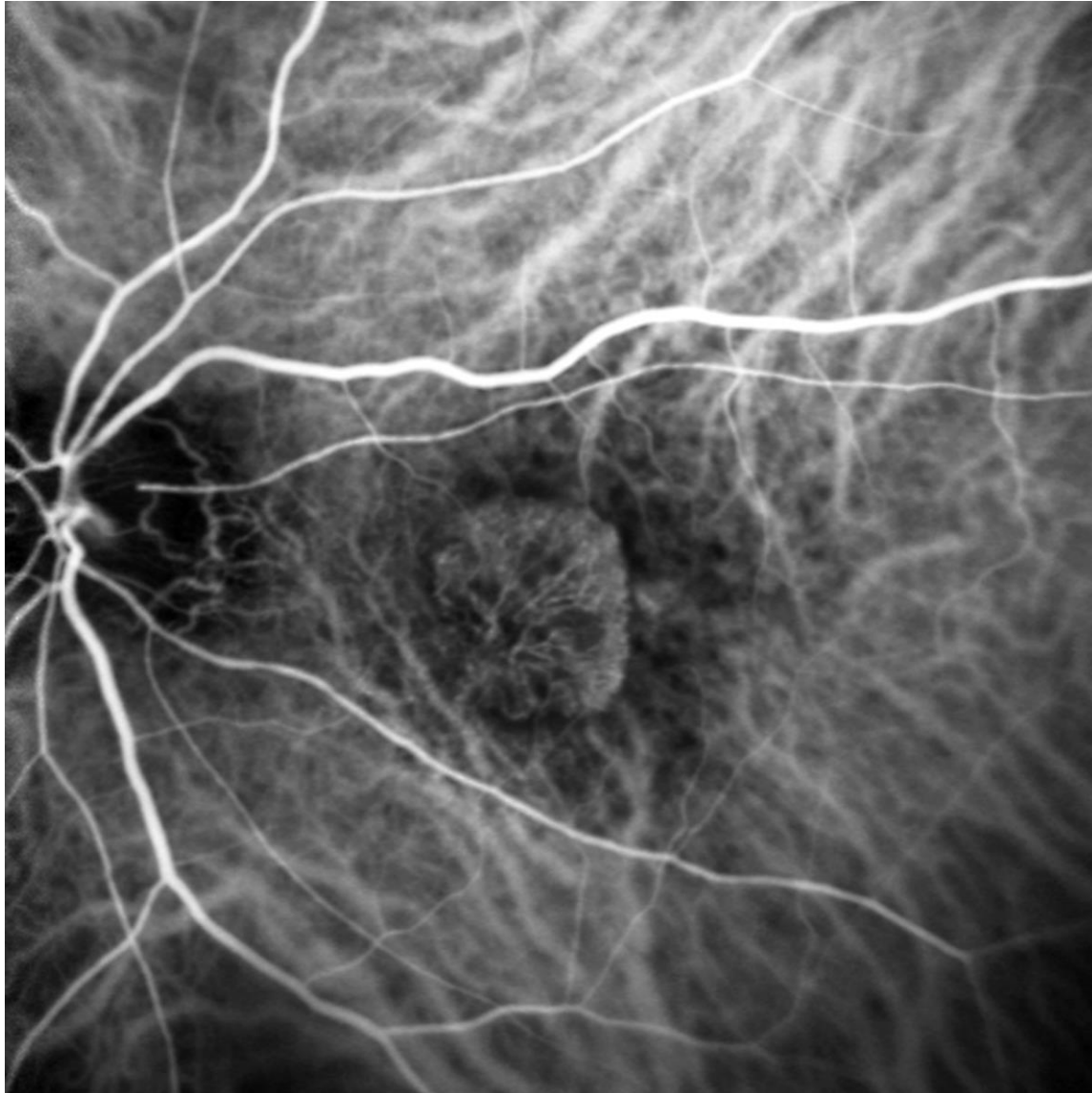
Ashley Brito

Pichardo

Maine Eye Center

ICG Angiogram





Branch Arterial Venous Complex

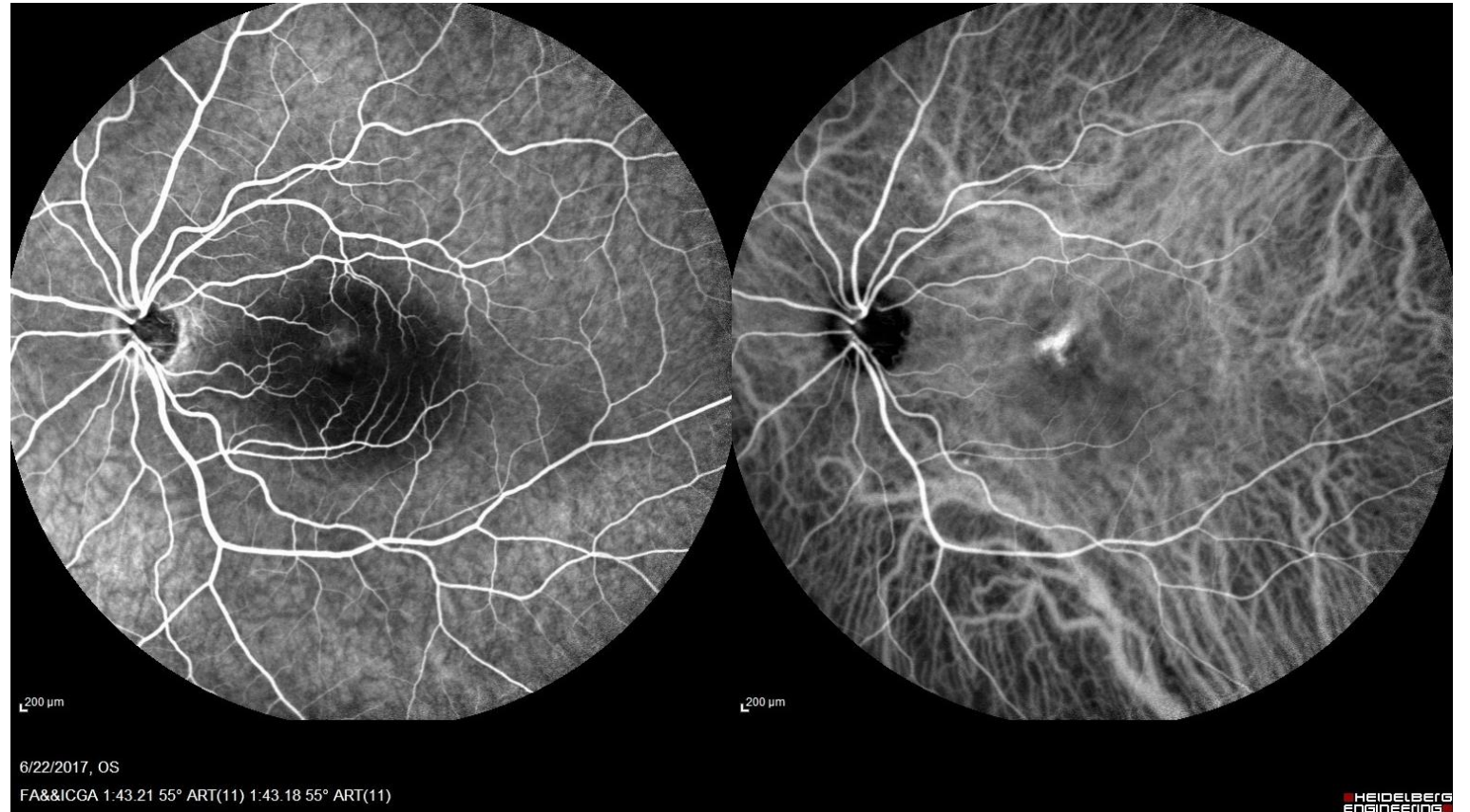
Ashley Brito Pichardo

Maine Eye Center

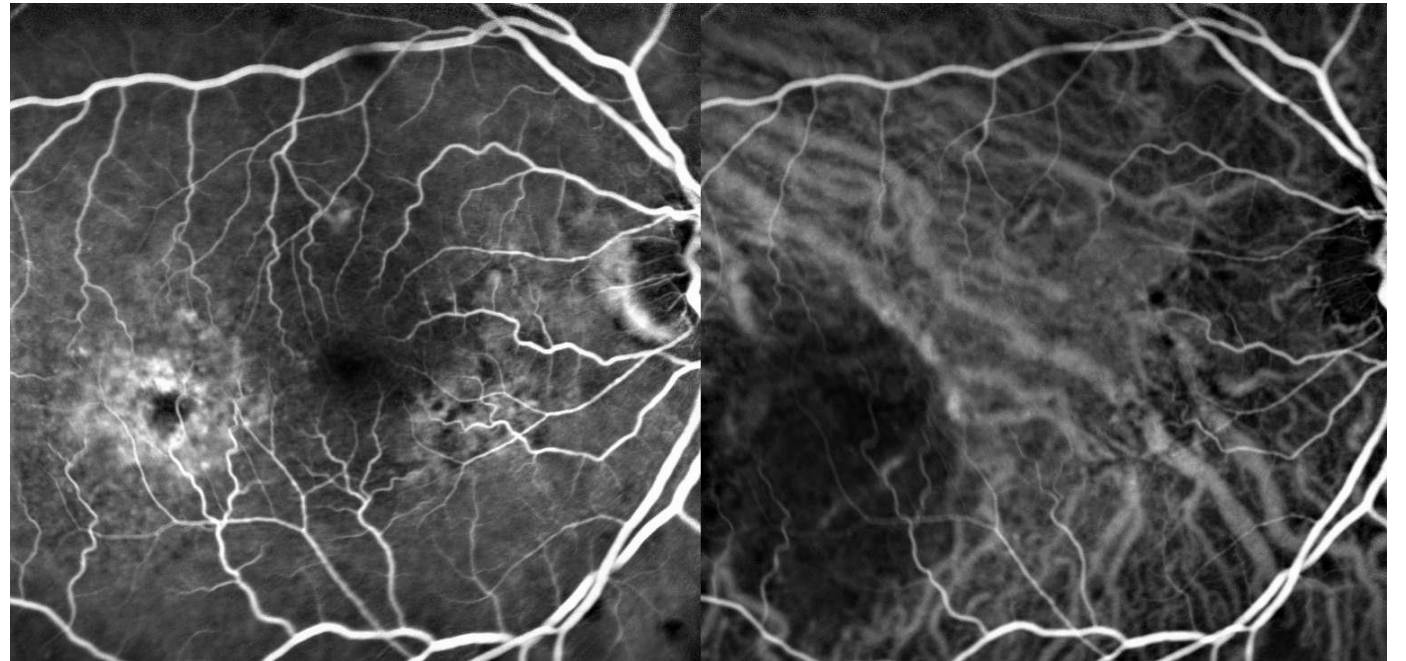


Central Serous Chorioretinopathy

Shymaa Mohamed
Kresge Eye Institute

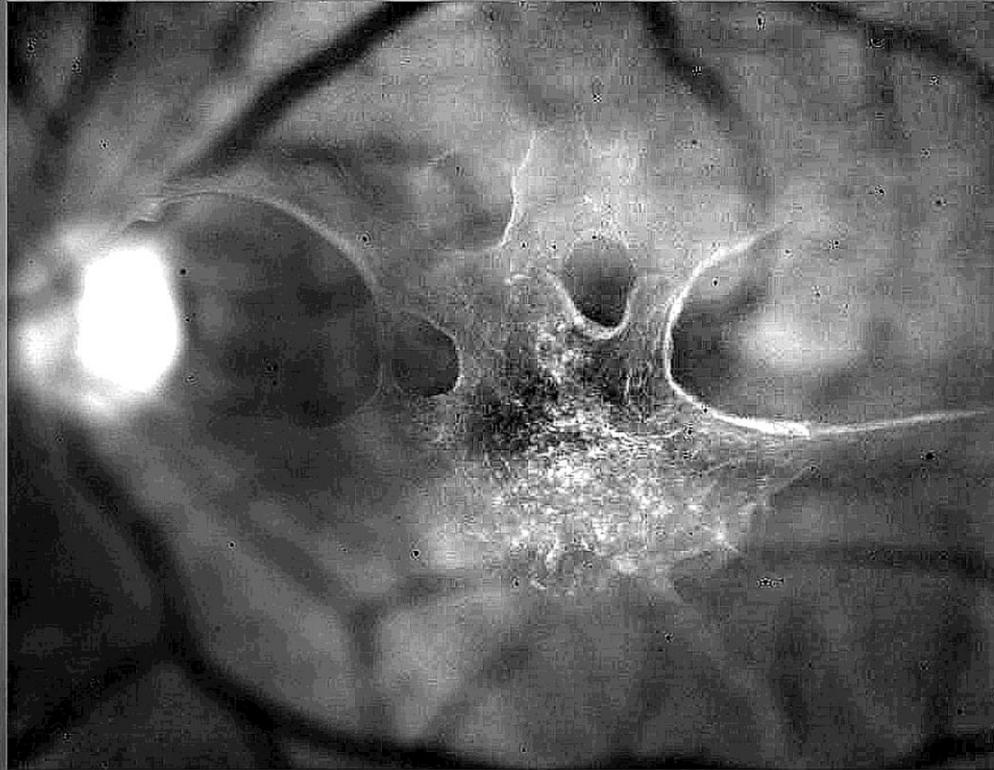


Chorioretinopathy
Shymaa Mohamed
Kresge Eye
Institute



Monochromatic Photography

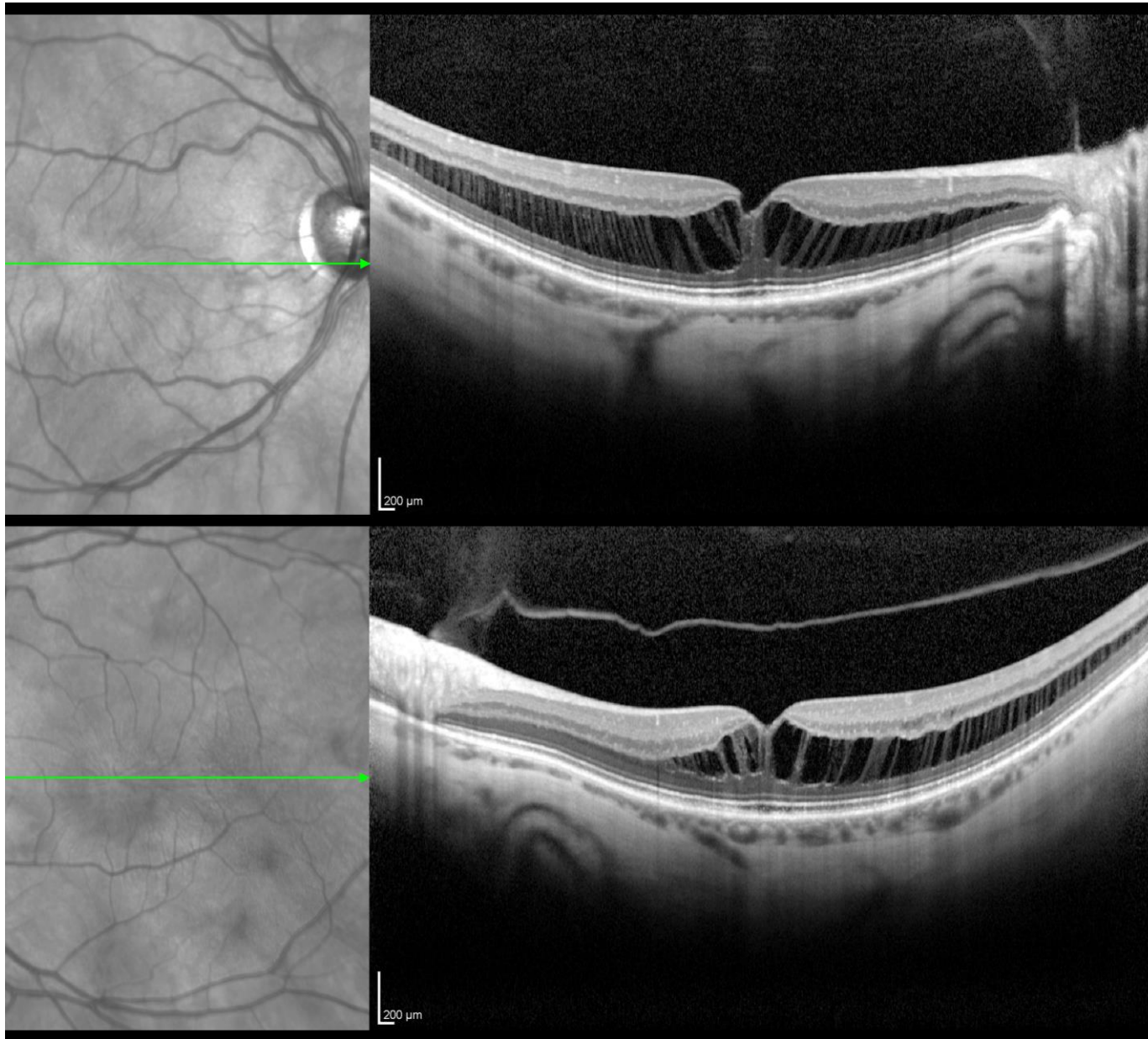




Posterior Vitreous Detachment
John Leo
Rajan Eye Care Hospital Pvt Ltd




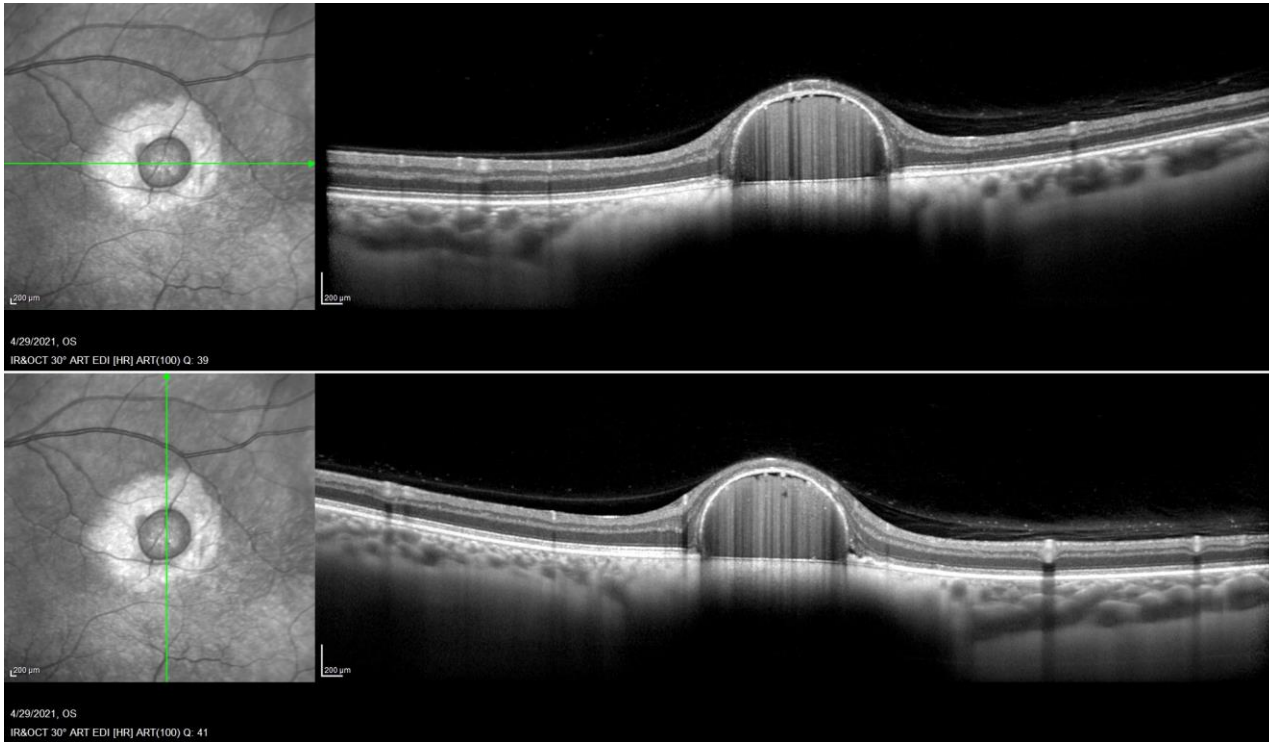
Optical Coherence Tomography



Retinoschisis

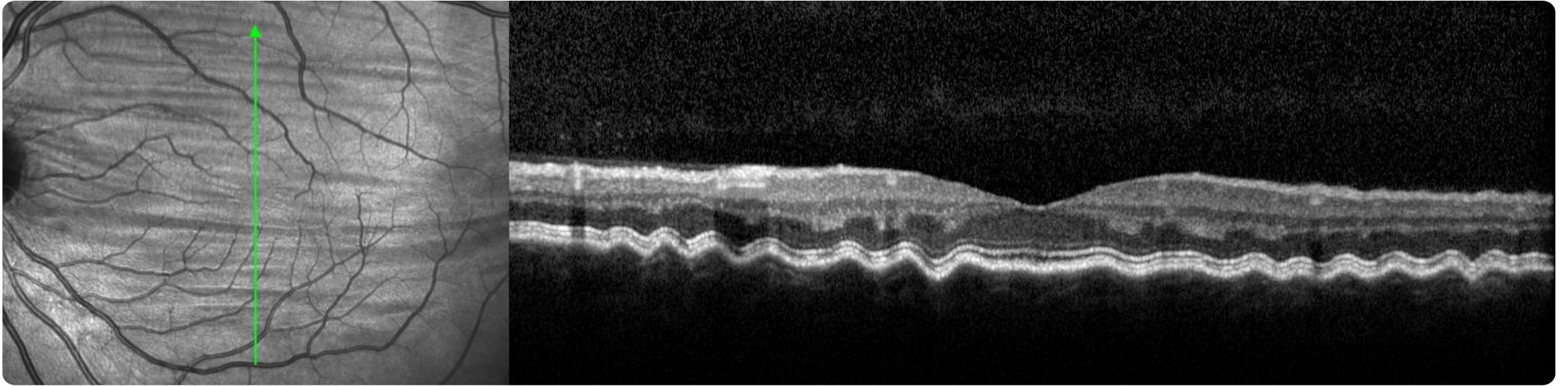
Tracey Troszak
Henry Ford Health
System





PED
Jennifer Ann Humenny,
CRA, OCT-C
Henry Ford Health System



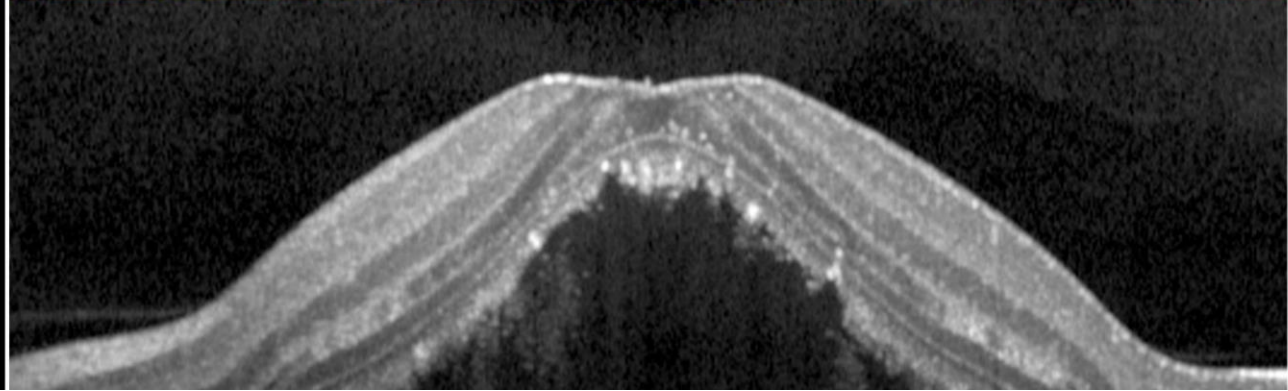
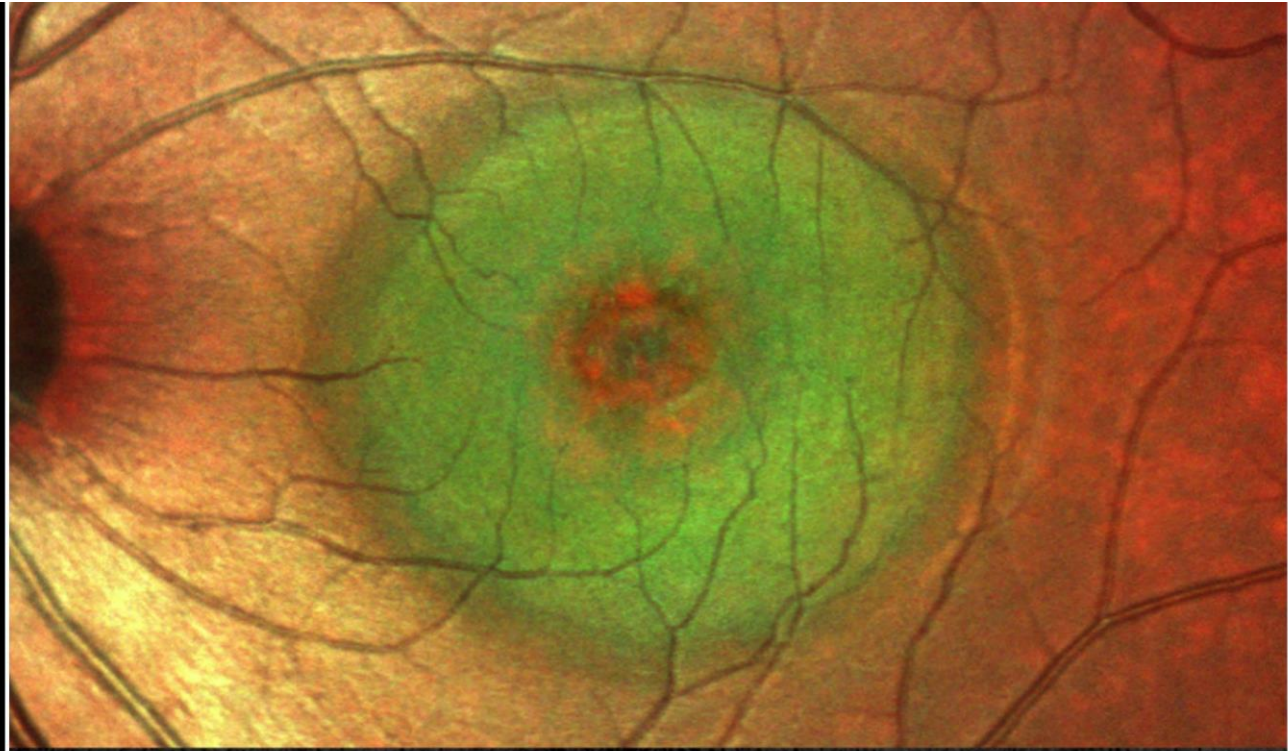

Choroidal Folds OCT

Veronica T. Jones

Duke Eye Center



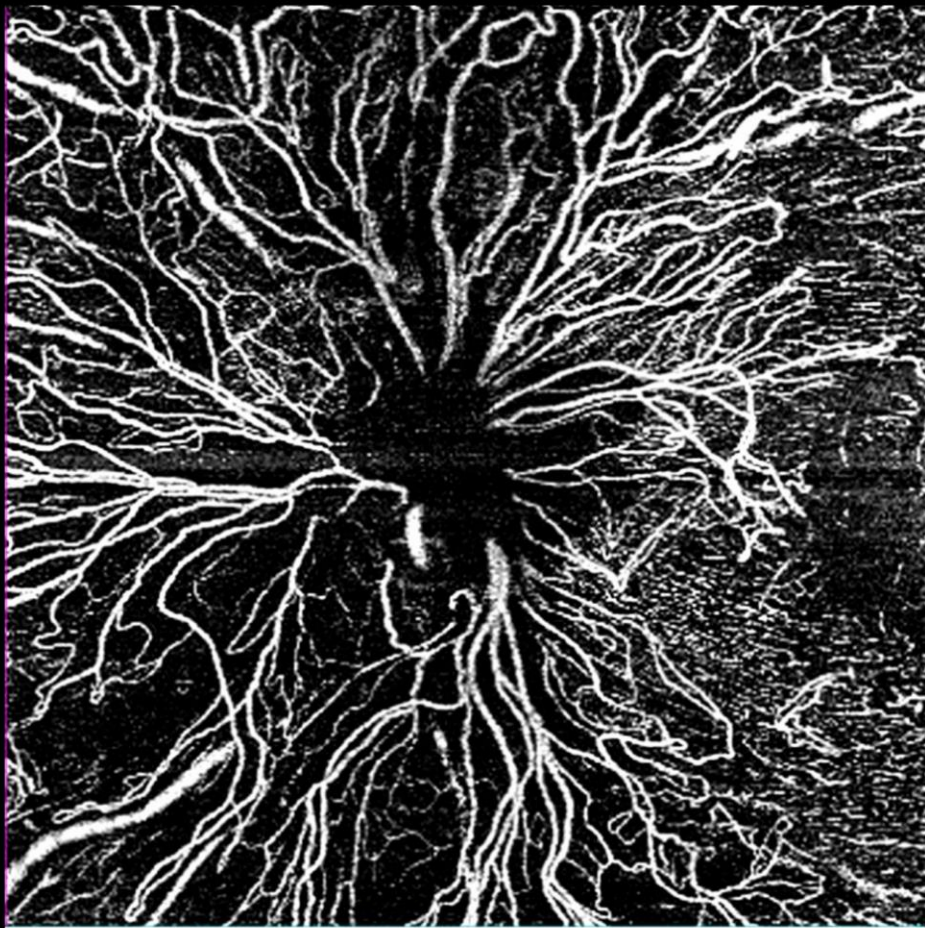


Central Serous Retinopathy

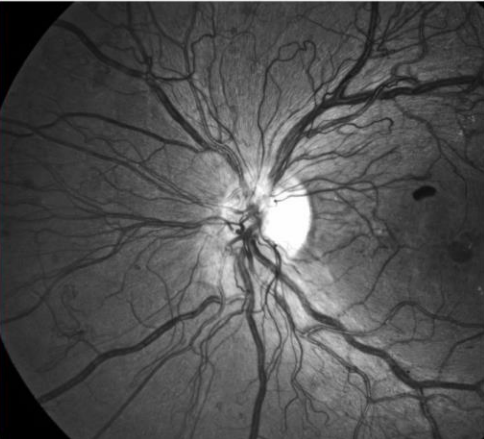
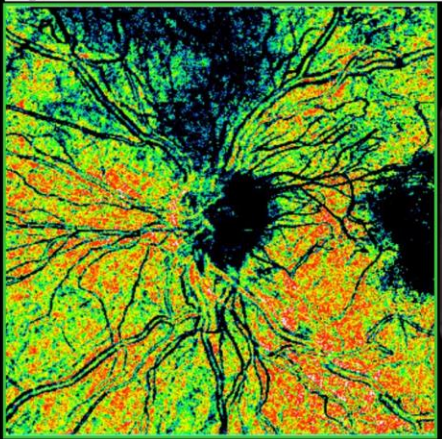
Kasi Sandhanam
Singapore National Eye
Center



Optical Coherence Tomography Angiography



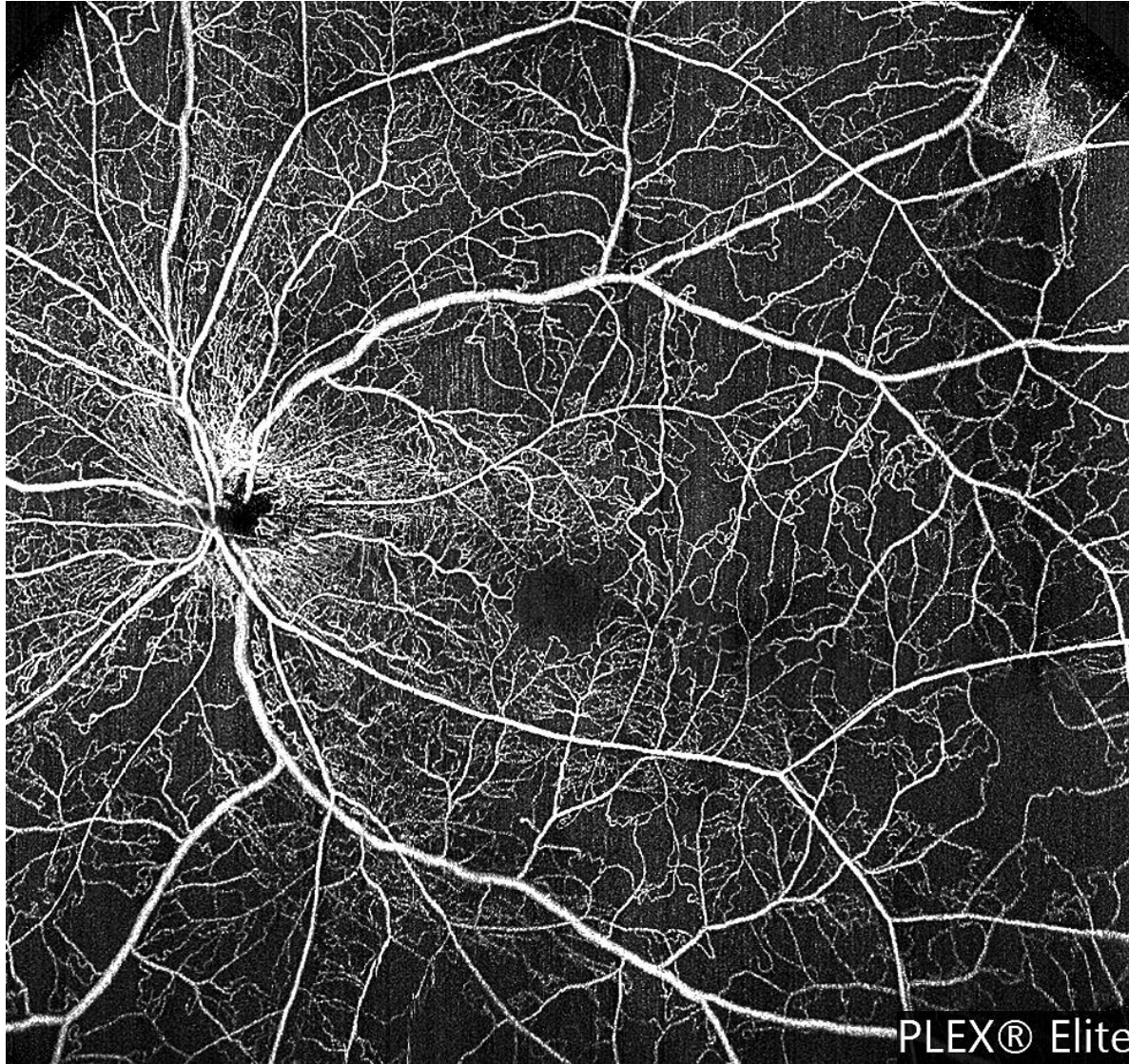
AngioPlex VRI: ILM-230, ILM+70



Neovascularization in the Disc

John Leo
Rajan Eye Care Hospital Pvt Ltd

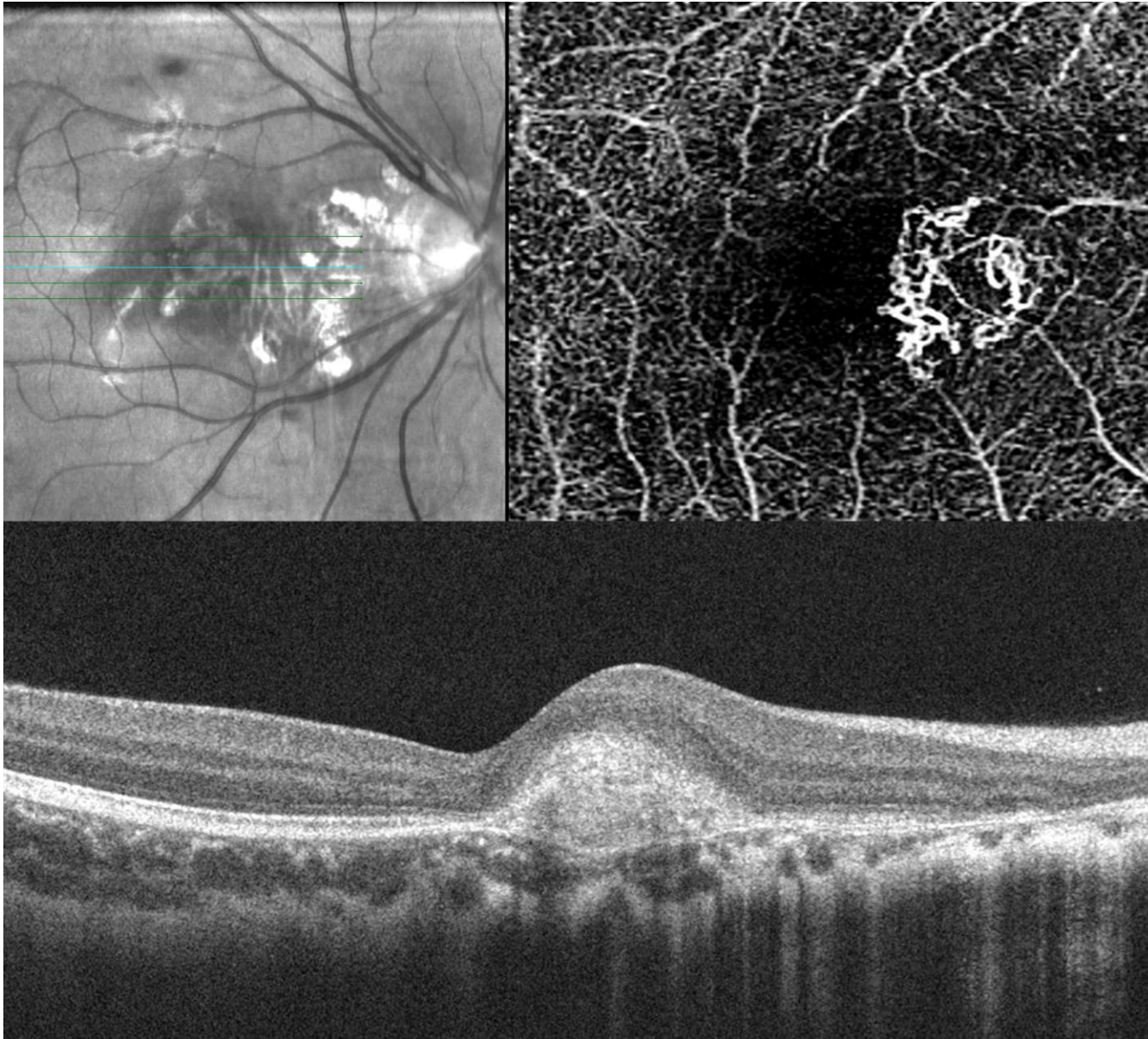




Central Retinal Vein Occlusion 1

Kasi Sandhanam
Singapore National Eye Center



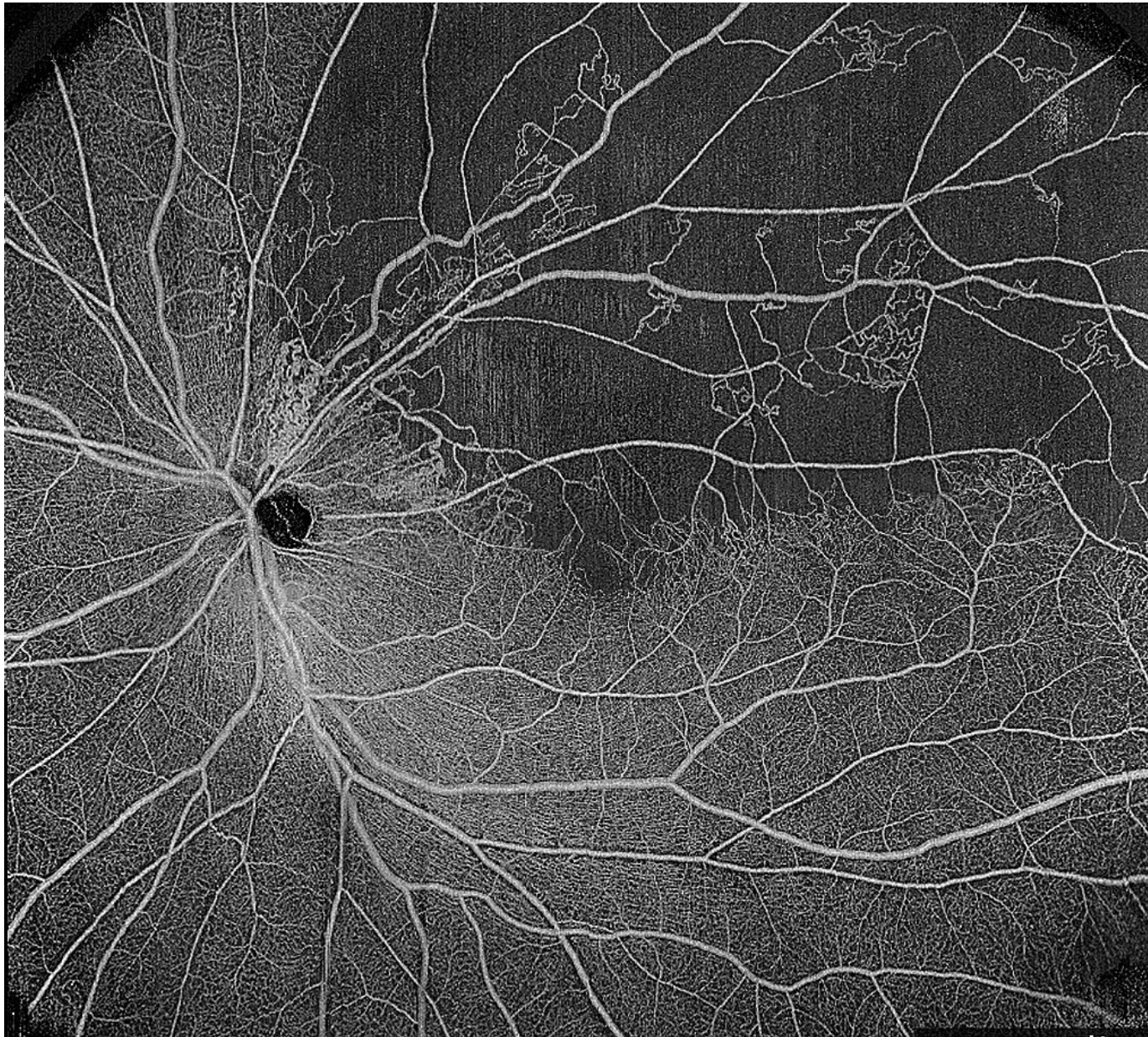


Myopic CNVM

John Leo

Rajan Eye Care Hospital
Pvt Ltd





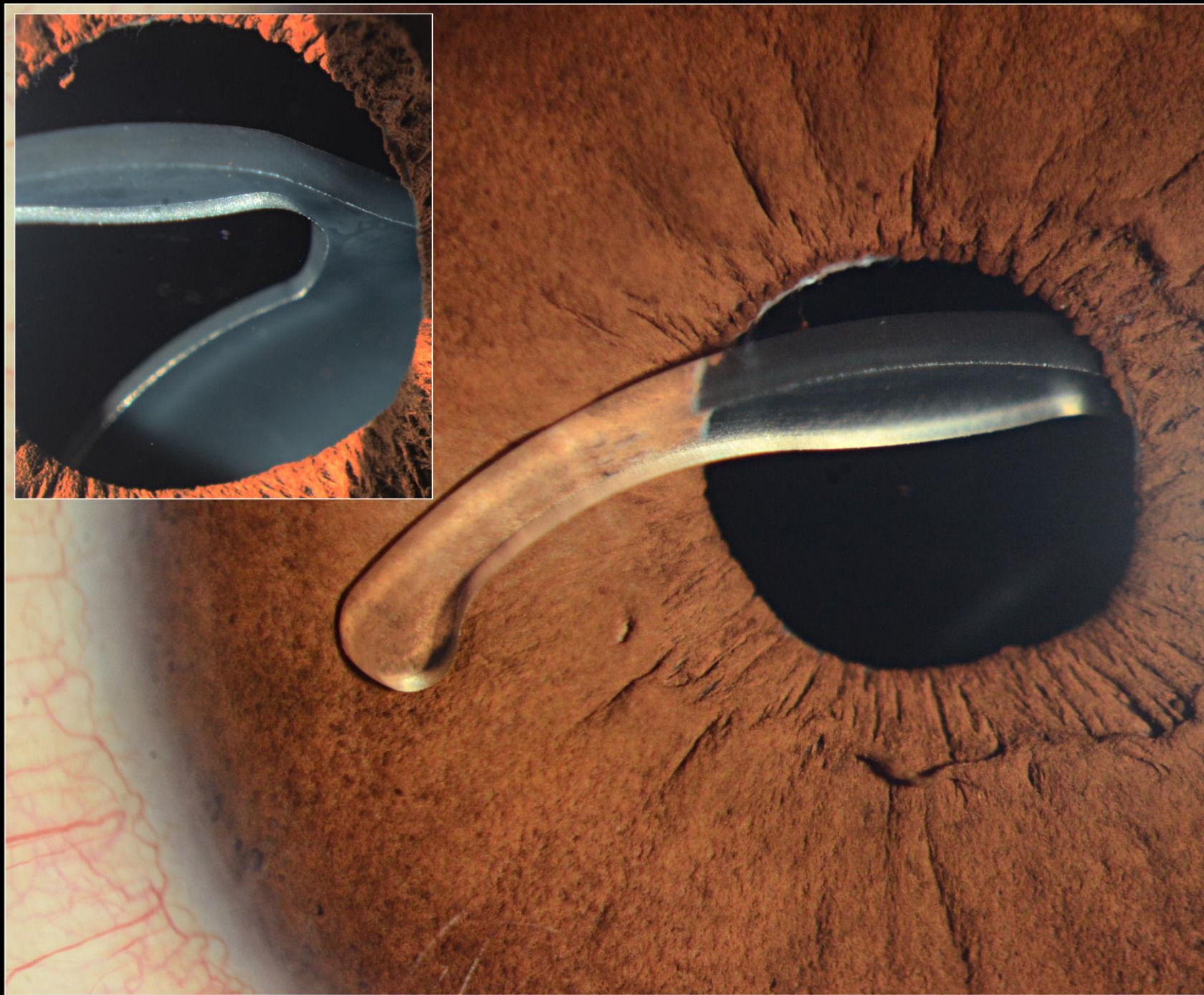
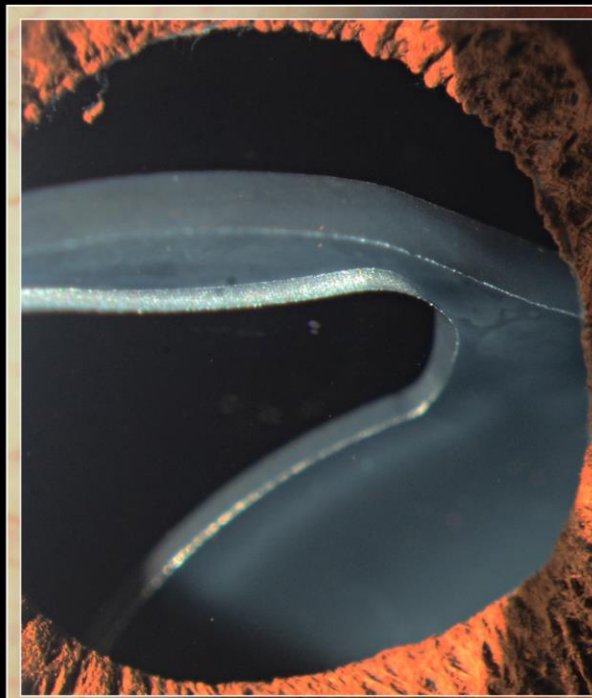
**Branch Retinal vein
occlusion 1**
Kasi Sandhanam
Singapore National Eye
Center

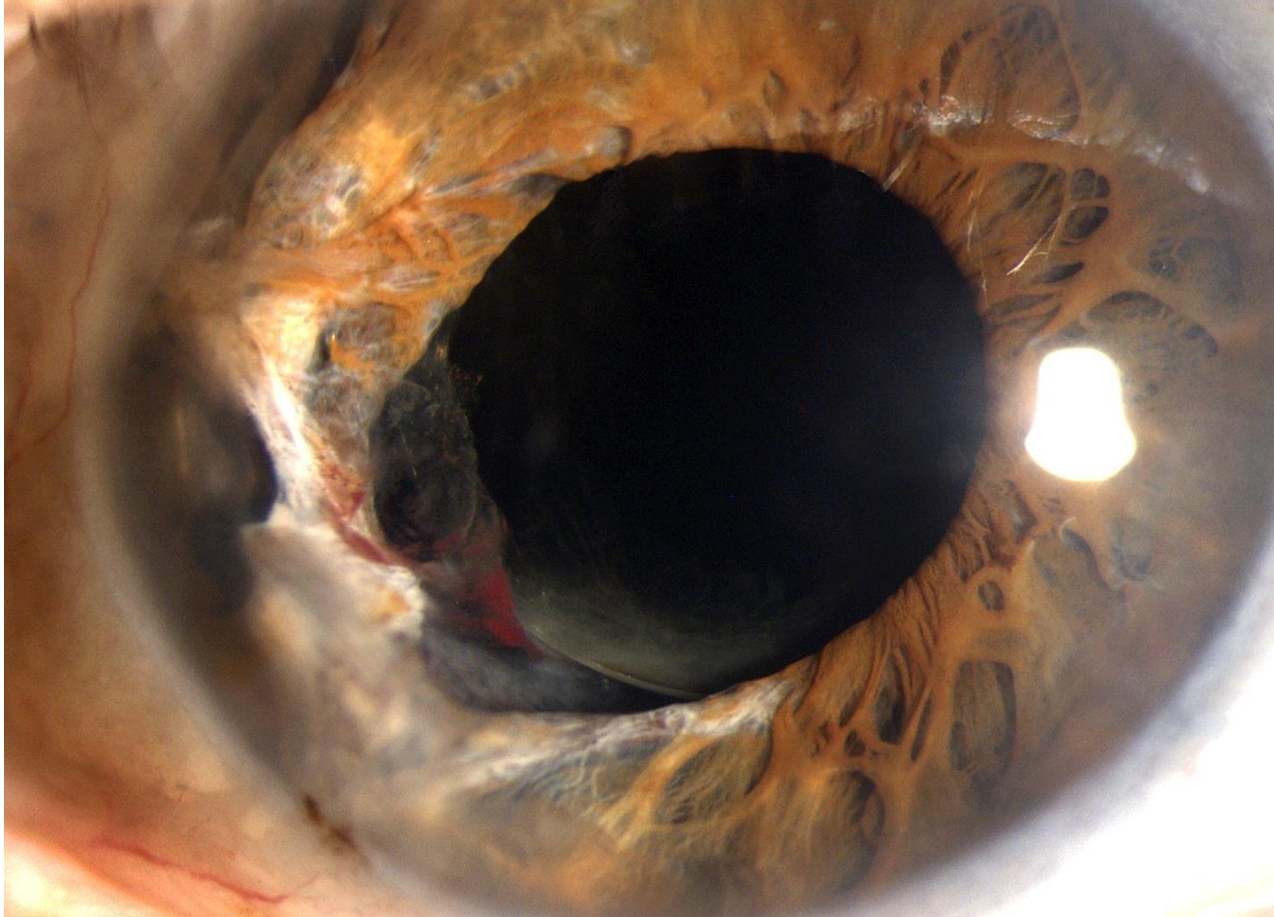


Slitlamp Photography



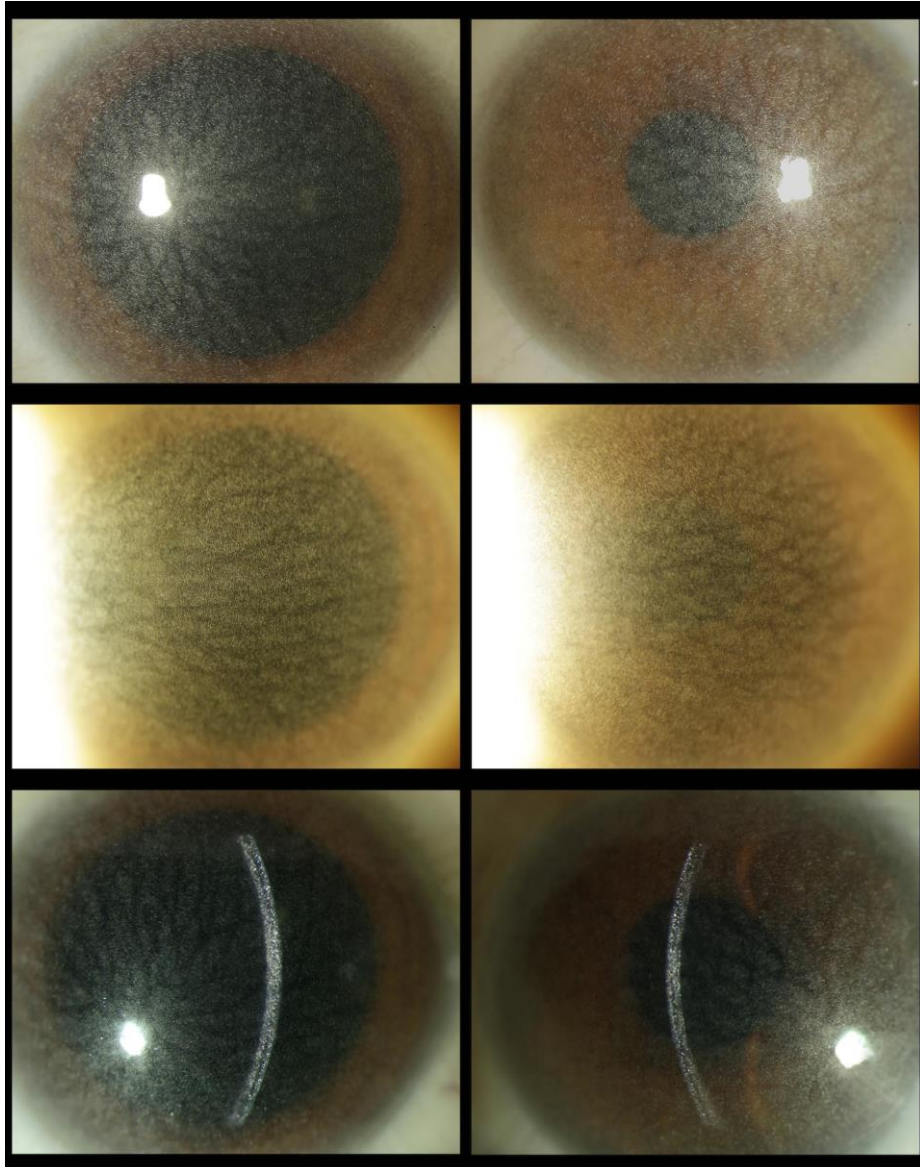
Dislocated IOL
Kasi Sandhanam
Singapore
National Eye
Center





Iridodialysis with Vit Heme
David T. Miller, CRA
Wake Forest Baptist Health
Eye Center

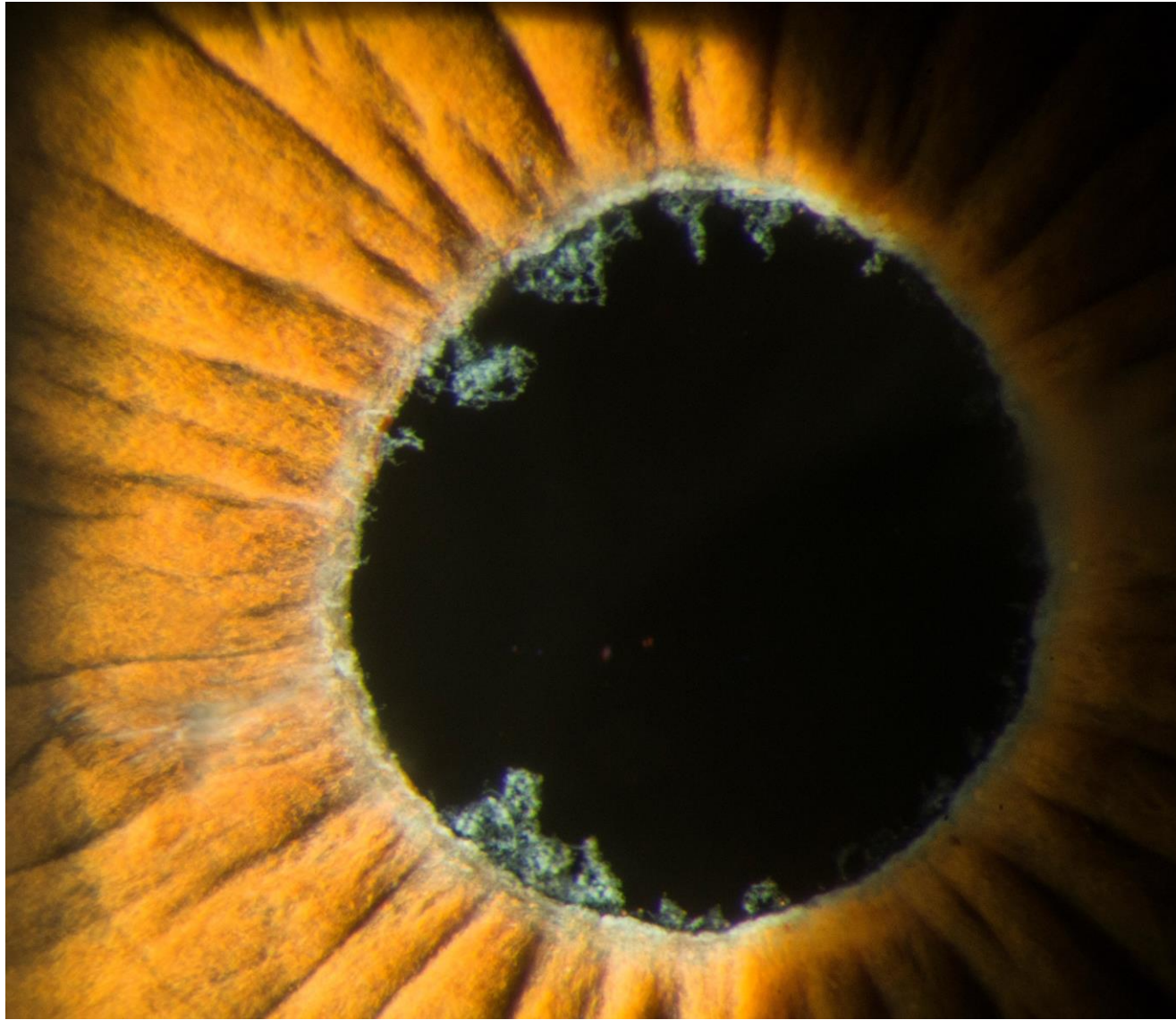




Cystine Deposits in the Cornea

Nicole Mantel
Inselspital, Bern

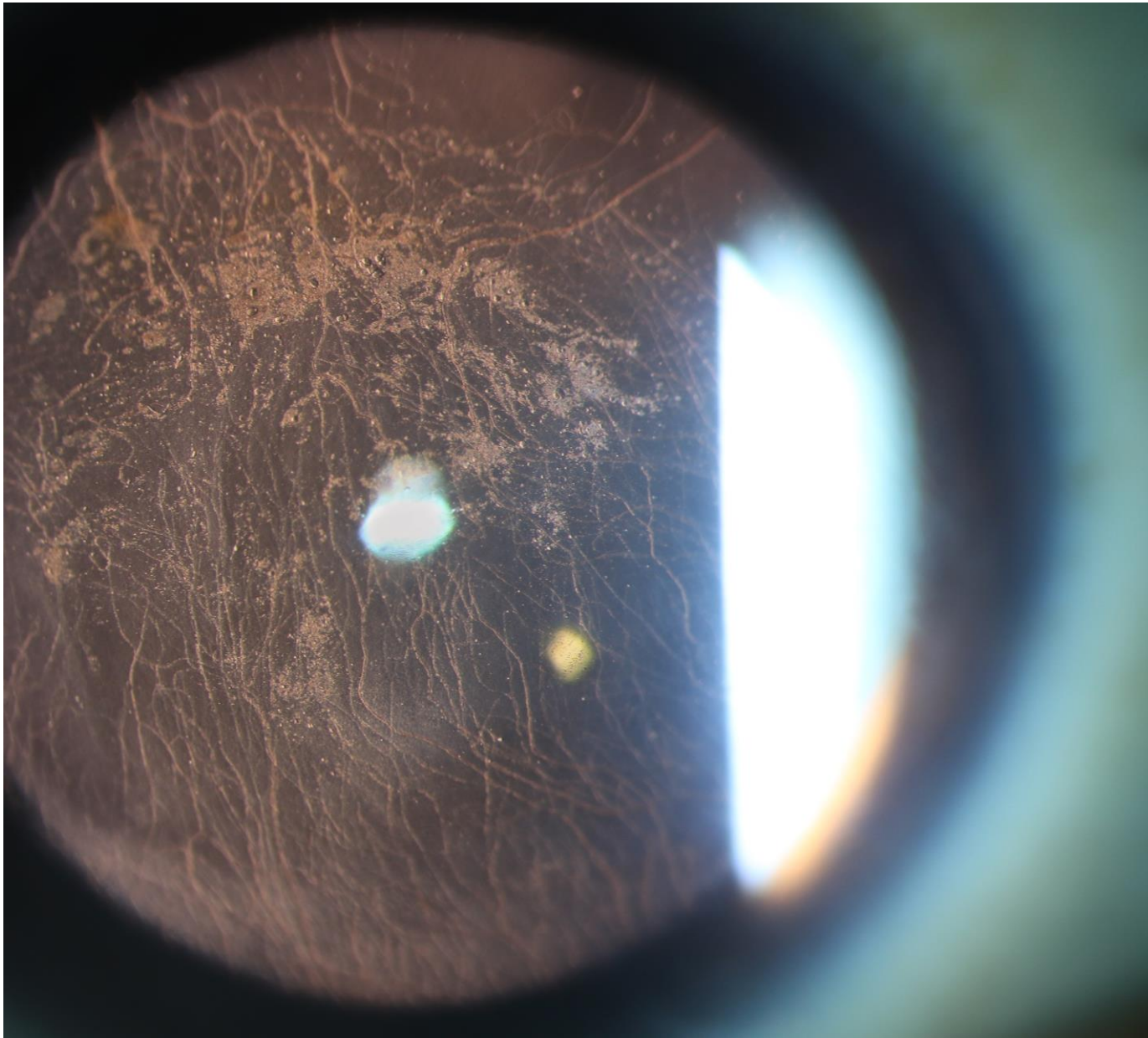




Pseudoexfoliation on Pupil Margin

Angela J. Chappell
Flinders Medical Centre

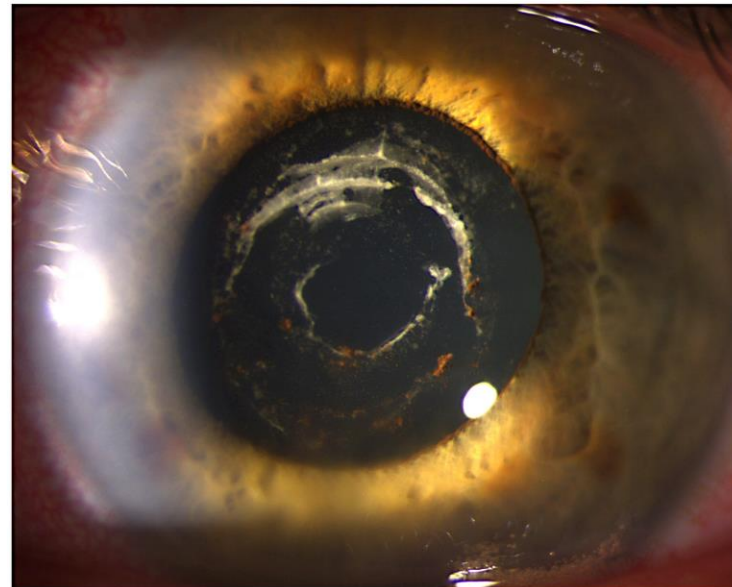
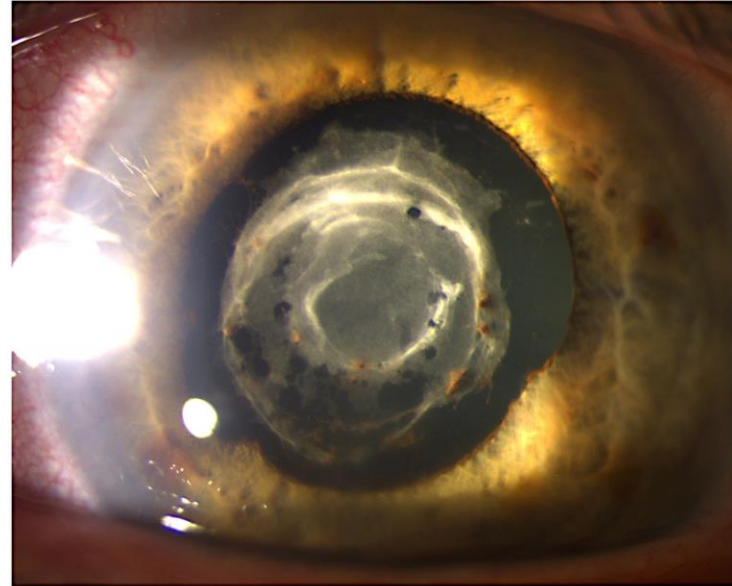




Corneal Ghost Vessels
Katherine Lachut
Virginia Commonwealth
University Health System



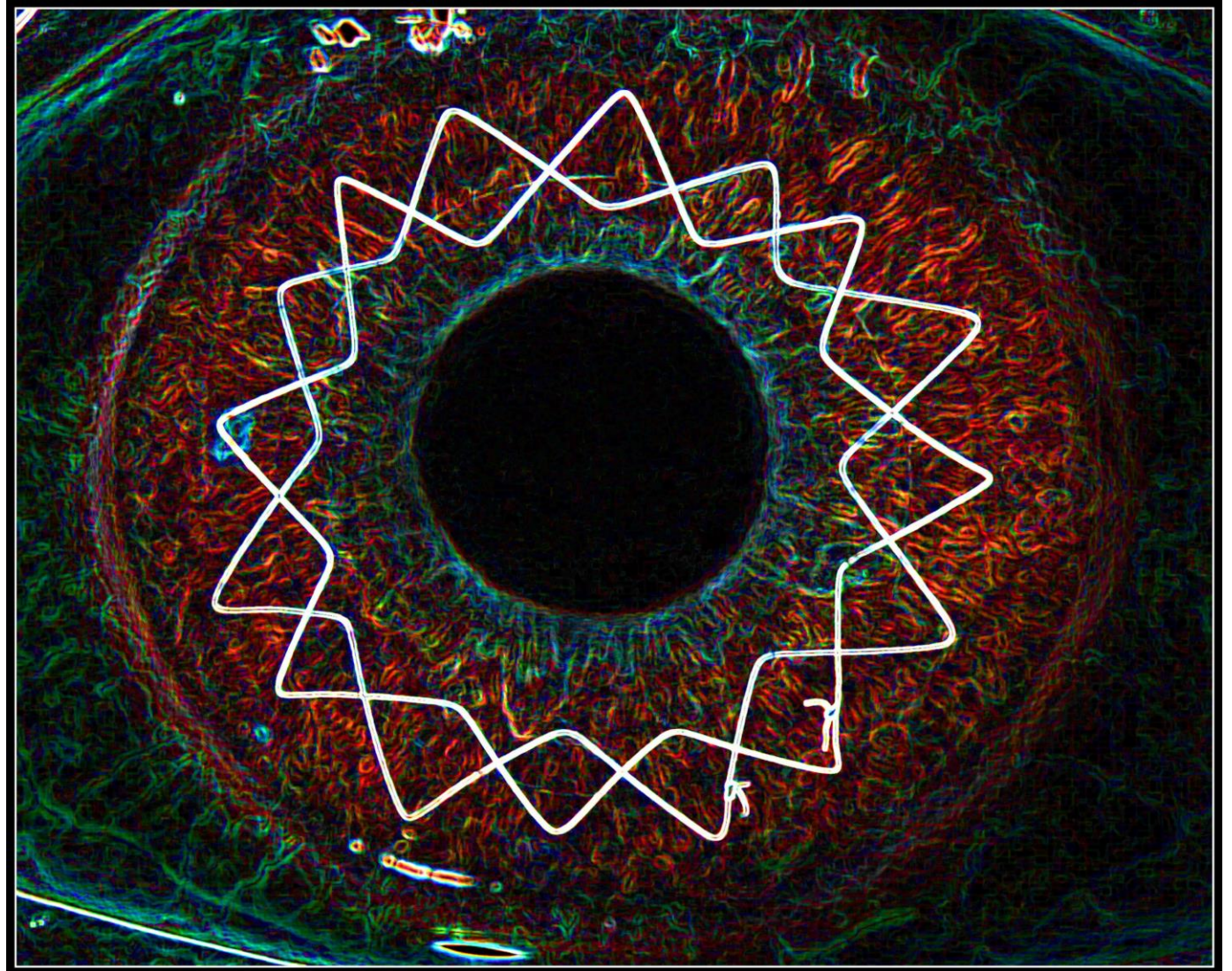
Tpa Injection Before
and After
Ashley Brito Pichardo
Maine Eye Center



The Eye as Art



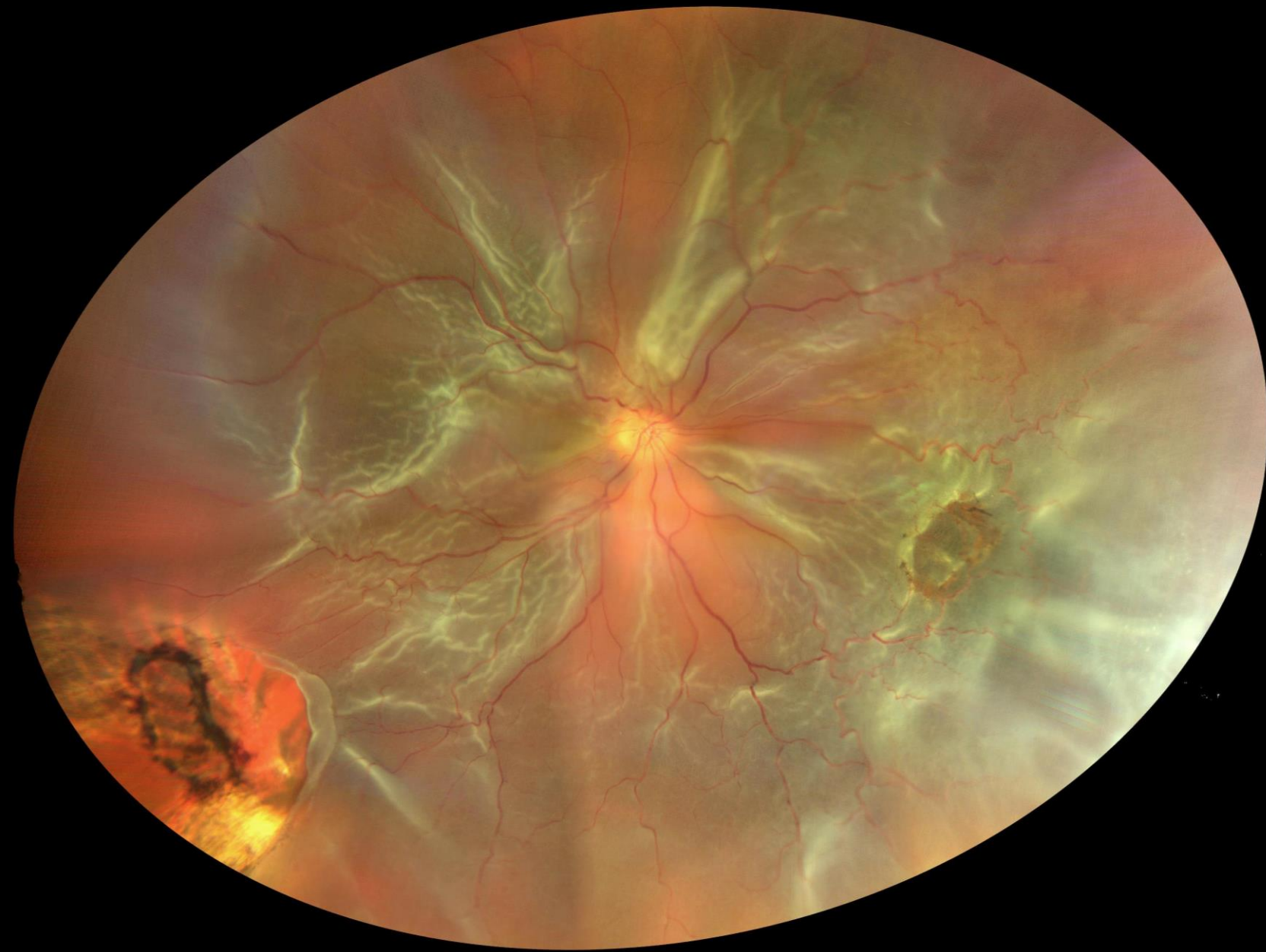Christal line (Post
corneal graft)
Kasi Sandhanam
Singapore National
Eye Center



FA Night Sky
Sara Cassabon
Kresge Eye
Institute

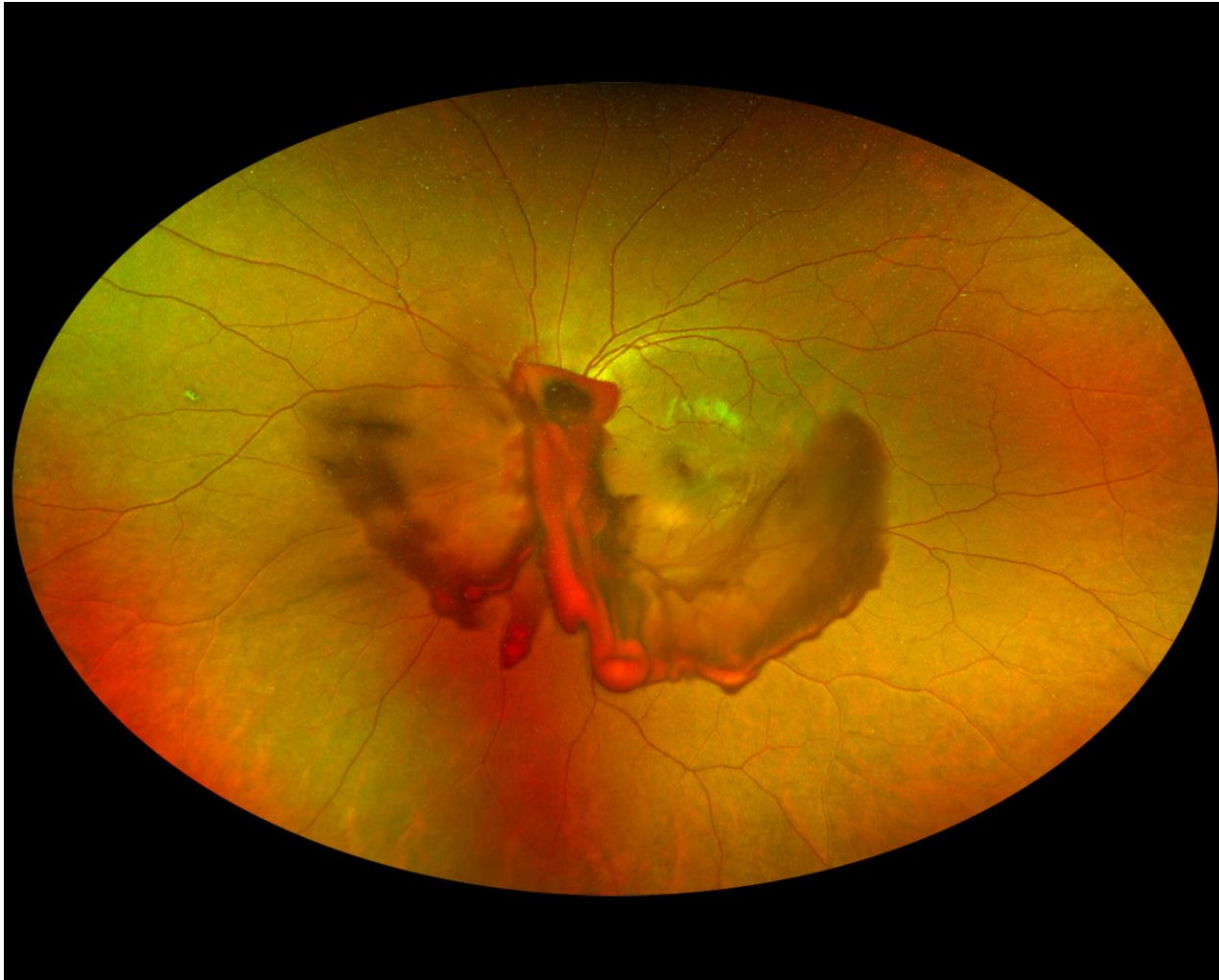

Ultra-Widefield Imaging $>60^\circ$
(all modalities)



Amotio Retinae
Nicole Mantel
Inselspital, Bern





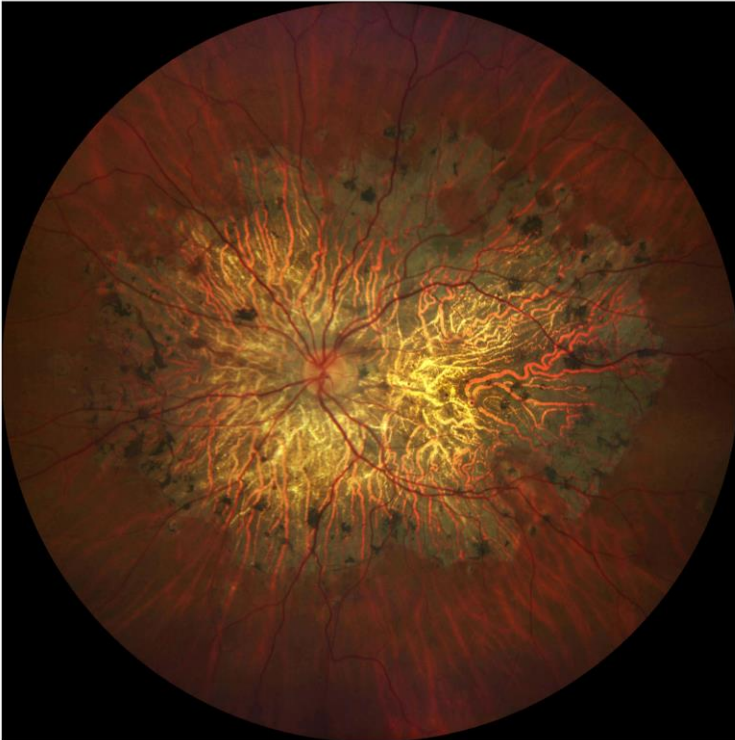
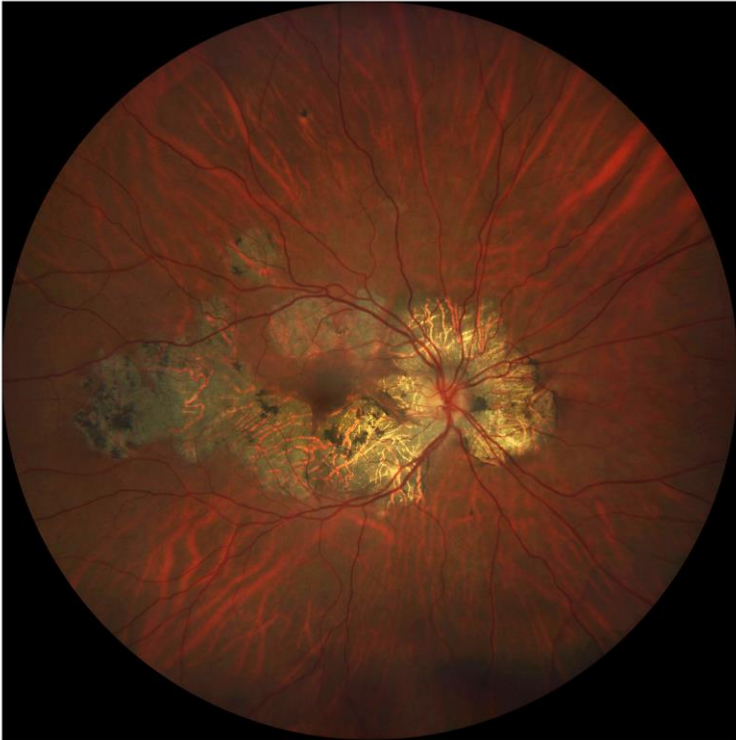
**Terson Syndrome with
Preretinal Hemorrhage**
Kasi Sandhanam
Singapore National Eye
Center

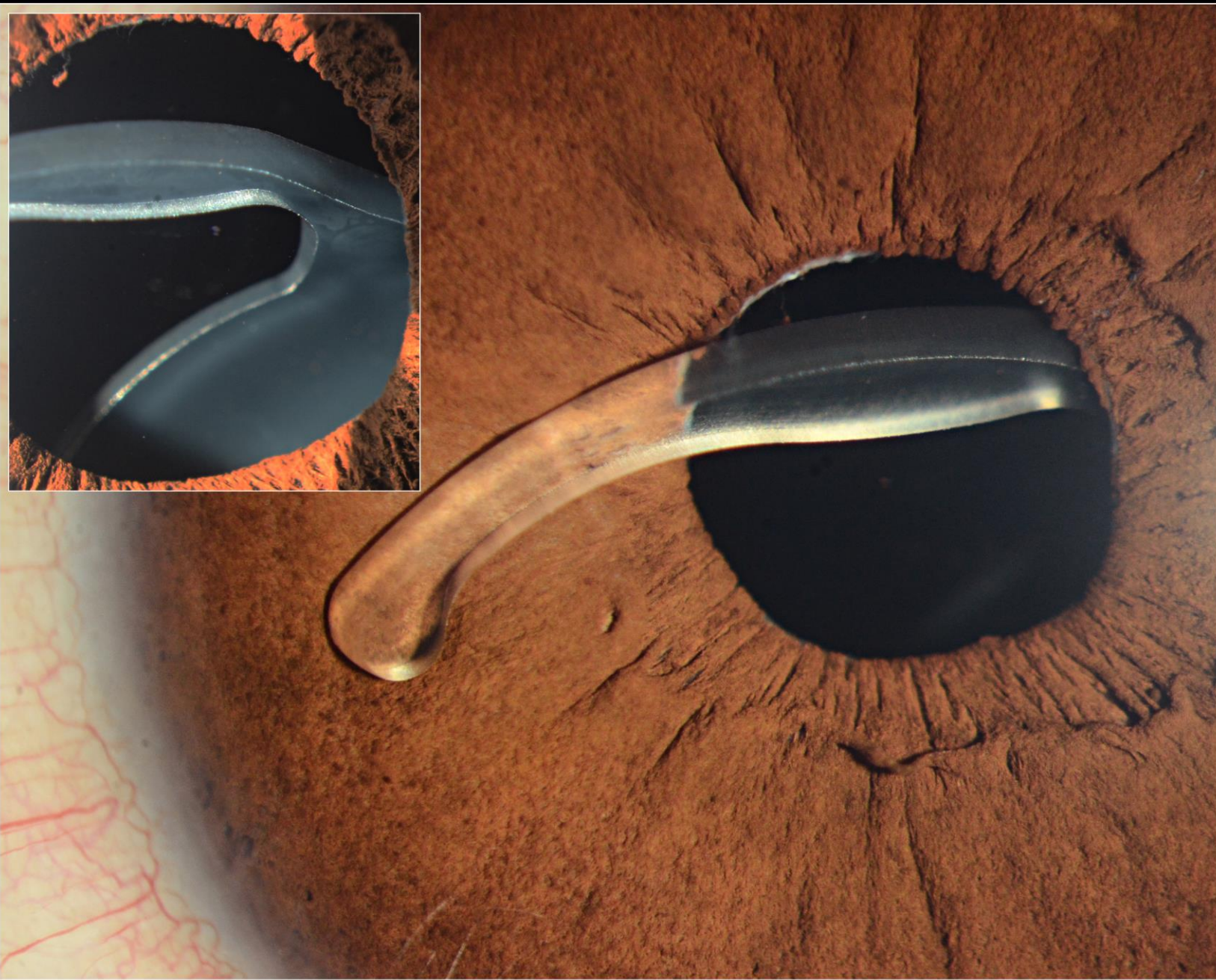


Serpiginous Choroiditis

Ashley Brito Pichardo

Maine Eye Center





BEST OF SHOW:
Dislocated IOL
Kasi Sandhanam
Singapore National Eye
Center





OPHTHALMIC
PHOTOGRAPHERS'
SOCIETY
EYE IMAGING EXPERTS

