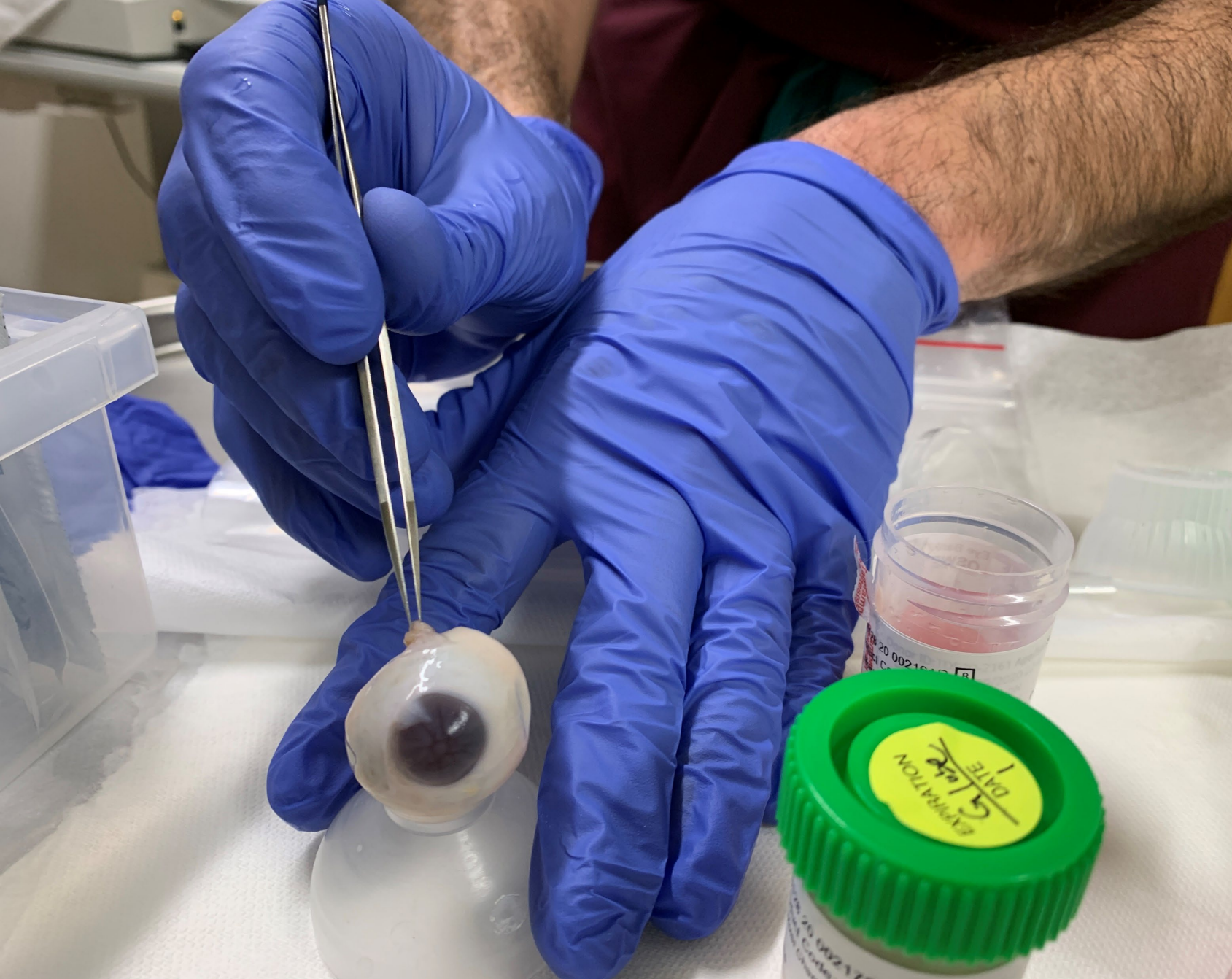

**Ophthalmic
Photographers' Society
2022 Exhibit**



OPHTHALMIC PHOTOGRAPHERS' SOCIETY
EYE IMAGING EXPERTS

Clinical Setting Photography



Gross Dissection

By: Denice Barsness

California Pacific Medical
Center Dept. of
Ophthalmology

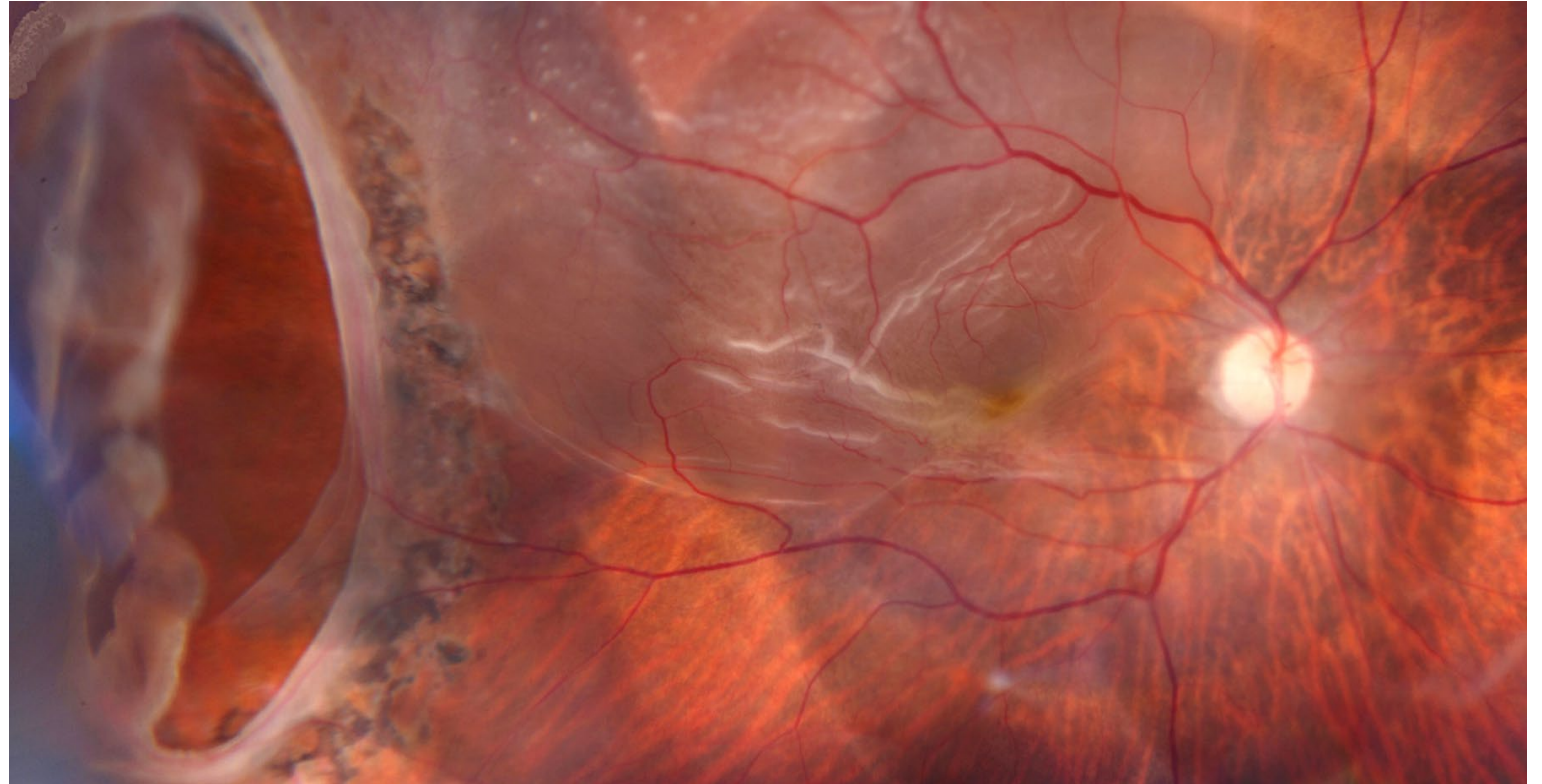


Composite



Retinal Detachment with GRT

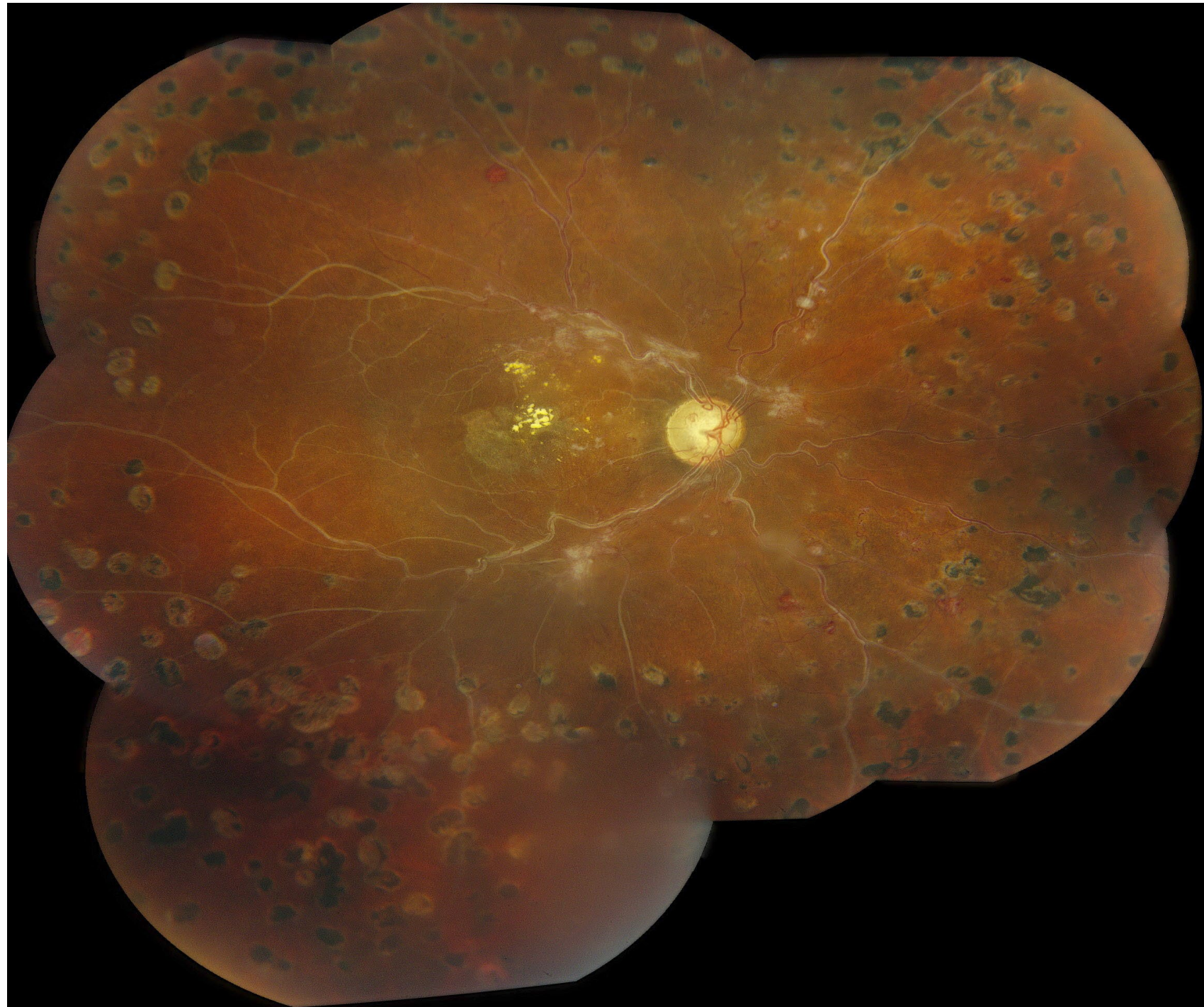
By: John Leo
Rajan Eye Care
Hospital Pvt Ltd

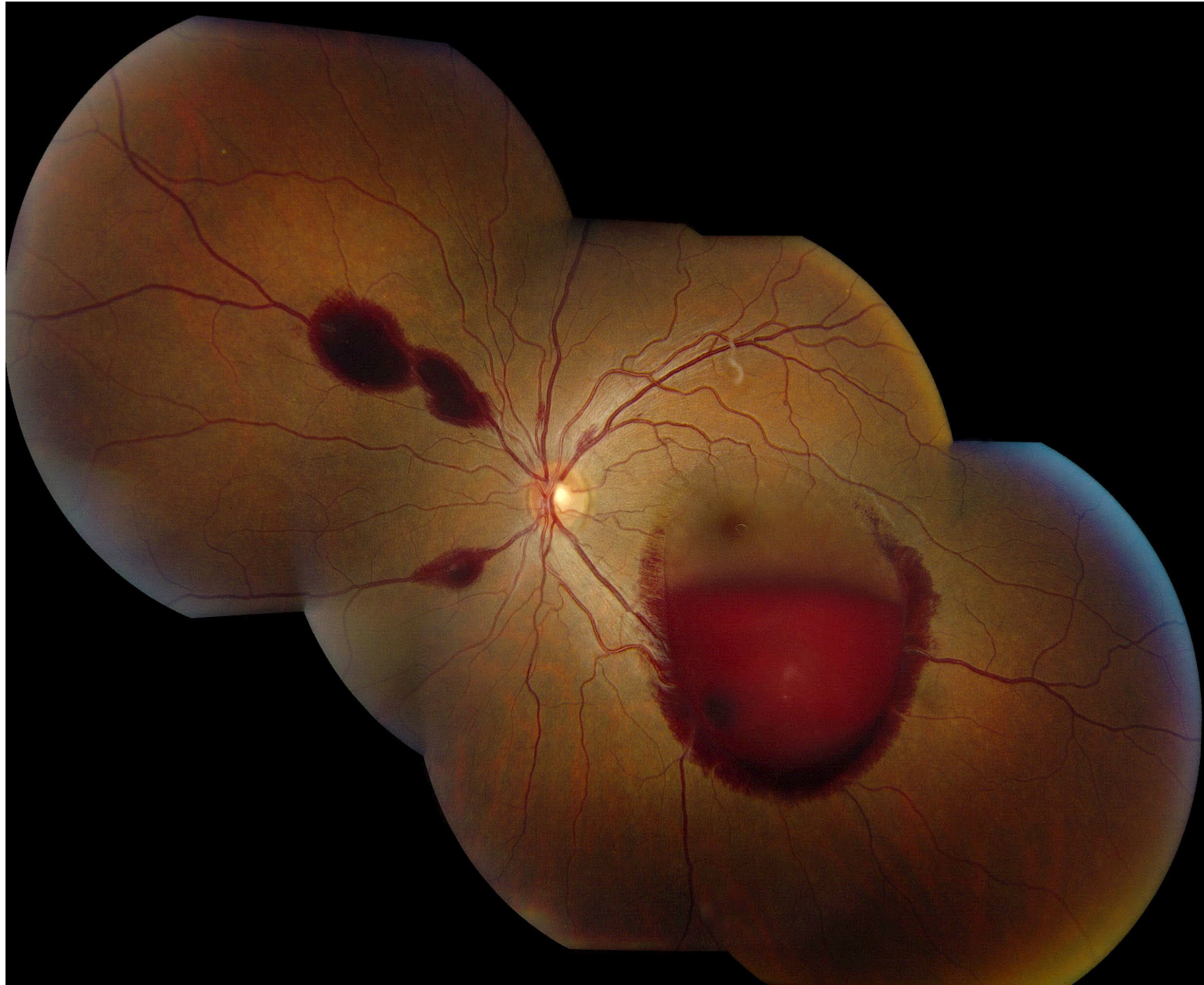


Crao

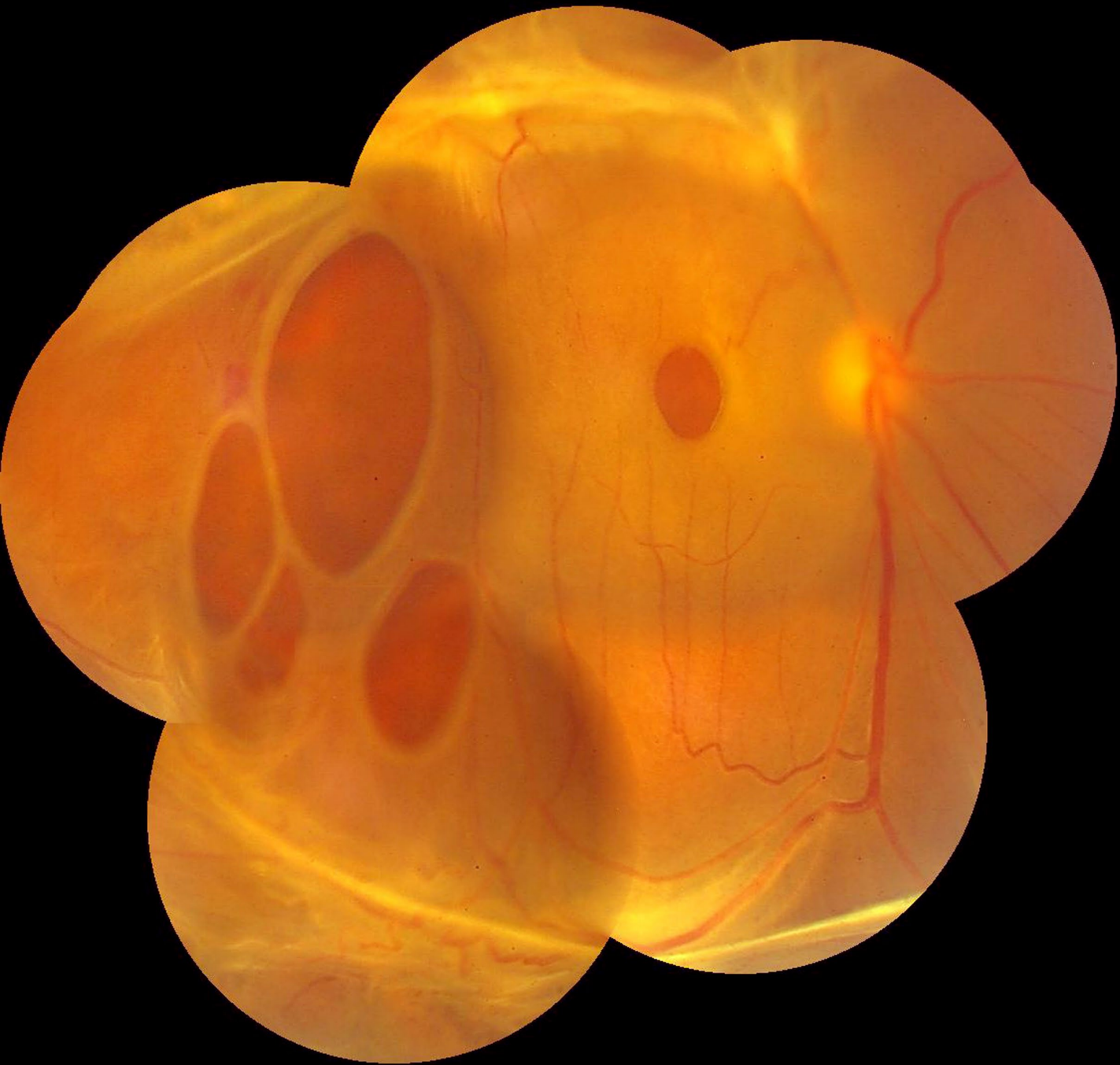
By: Sarah L. Skiles

University of Iowa
Hospitals and Clinics





**Boat Shaped
Hemorrhage**
By: Sarah L. Skiles
University of Iowa
Hospitals and Clinics



Retinal Detachment with Multiple Retinal Holes

By: John Leo
Rajan Eye Care Hospital
Pvt Ltd

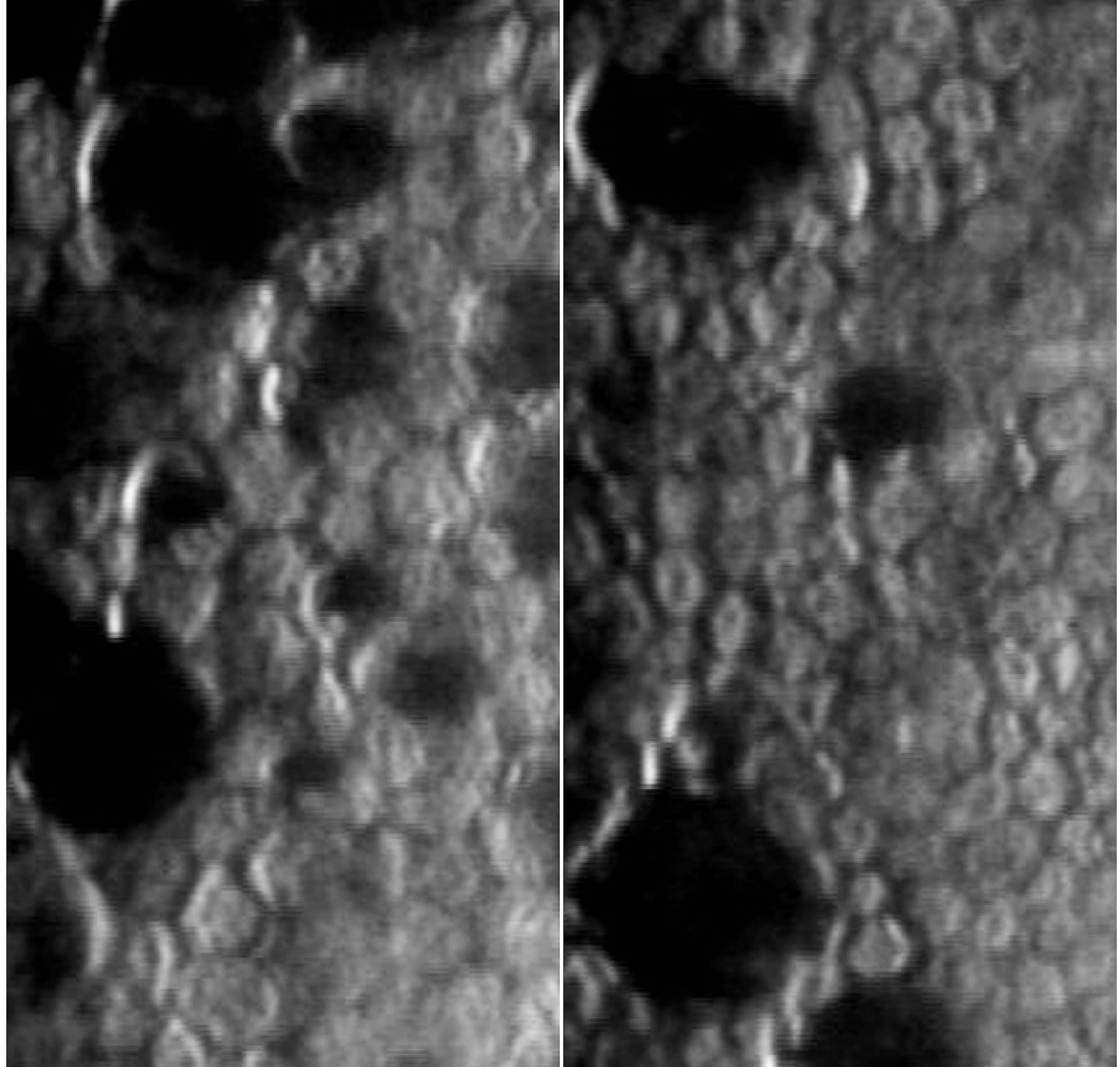


Corneal Endothelial Photography



Moon Craters (Corneal Guttata)

By: Prasanna Venkatesh
Ramesh
Mahathma Eye Hospital
Private Limited

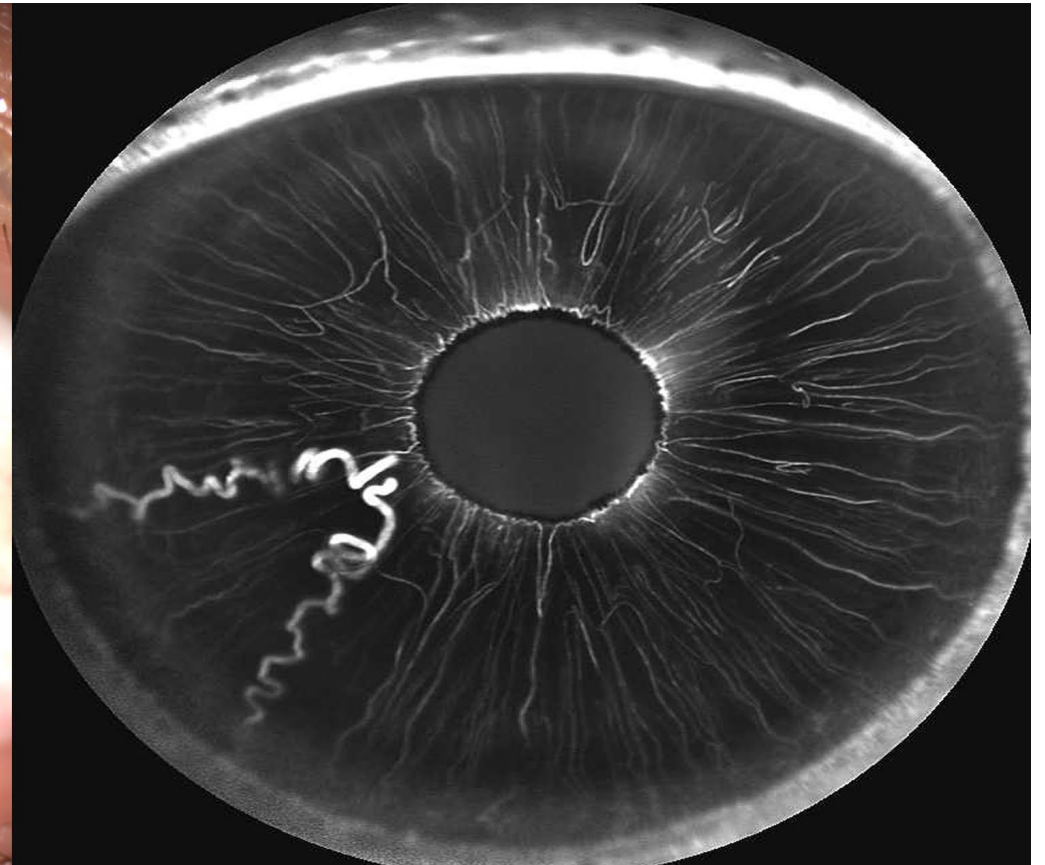
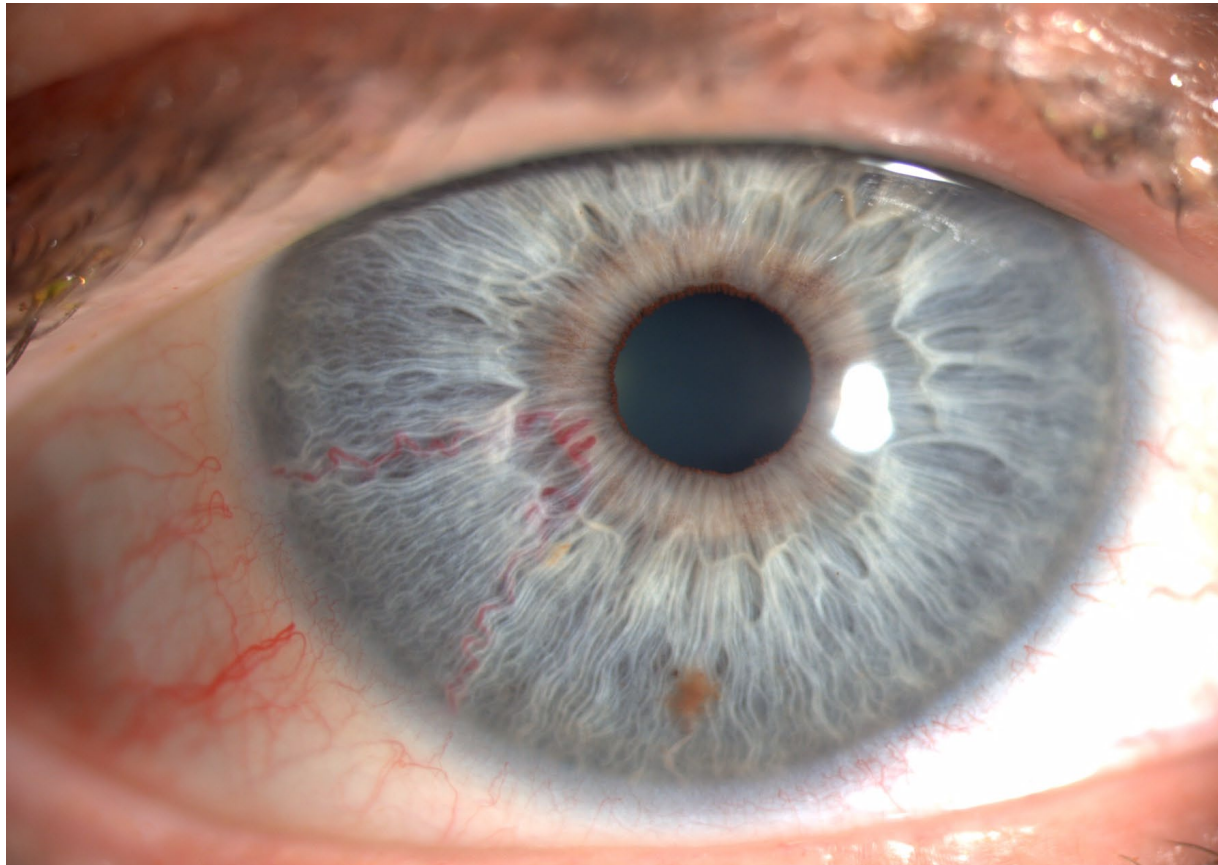


Cross Categories



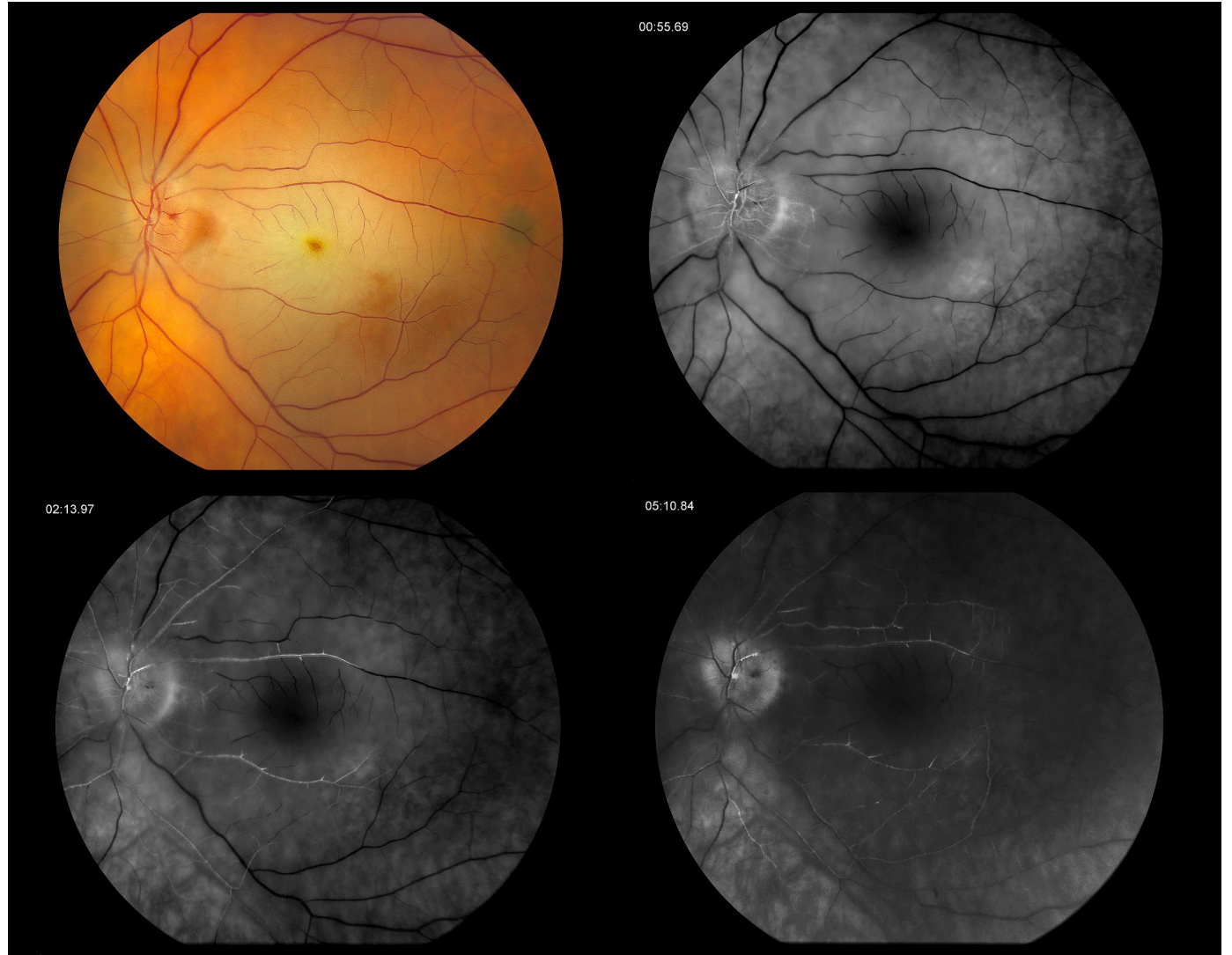
Racemose Hemangioma

By: Darrin A Landry, CRA, OCT-C
Eyecare Medical Group



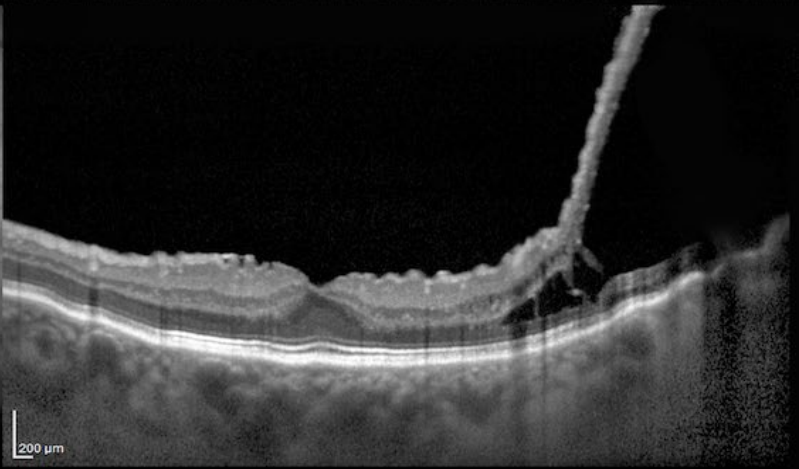
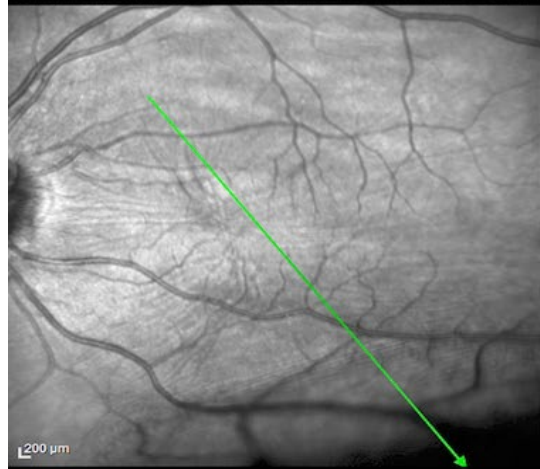
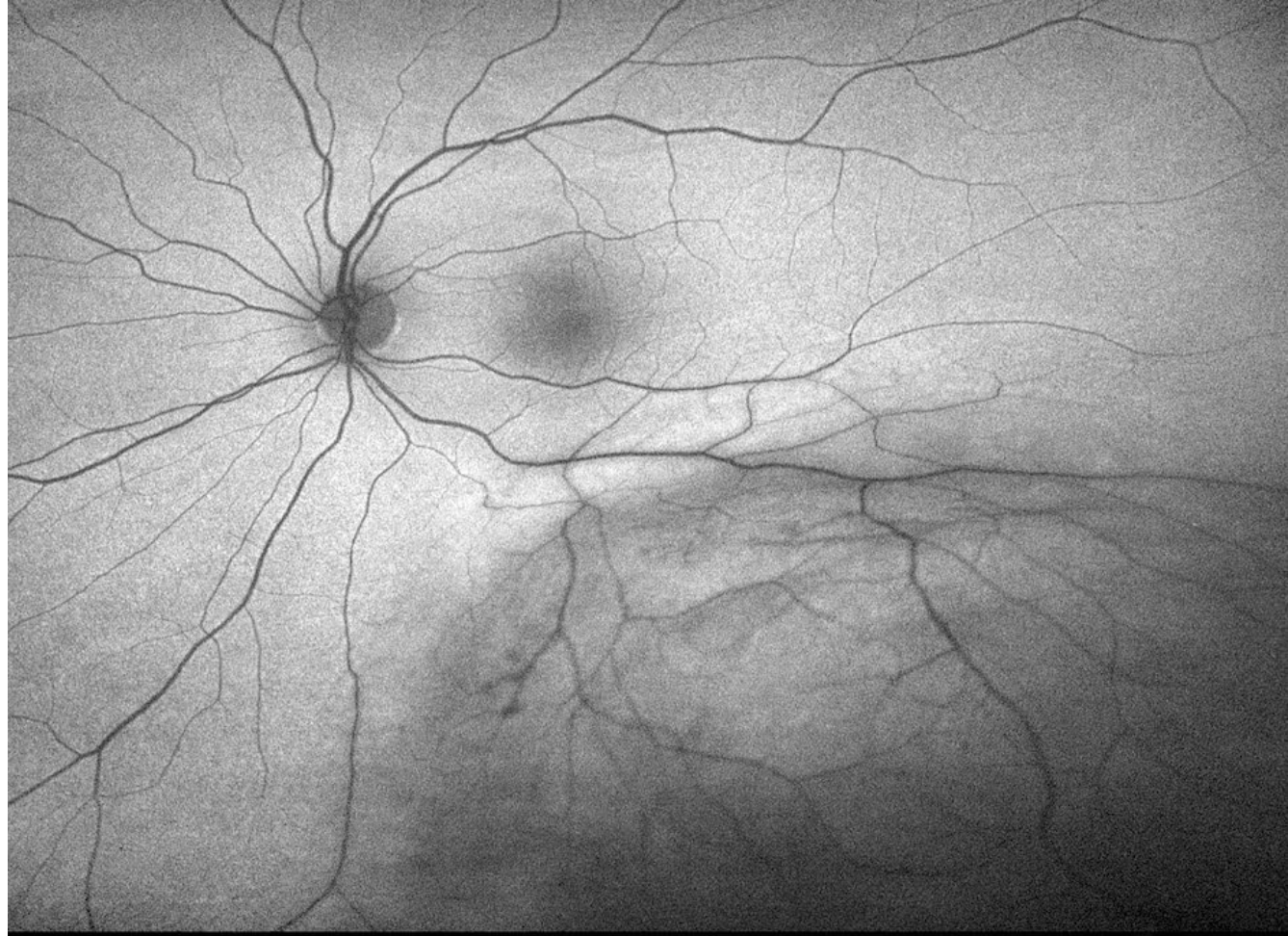Crao

By: Sarah L. Skiles
University of Iowa
Hospitals and Clinics



Retinoschisis

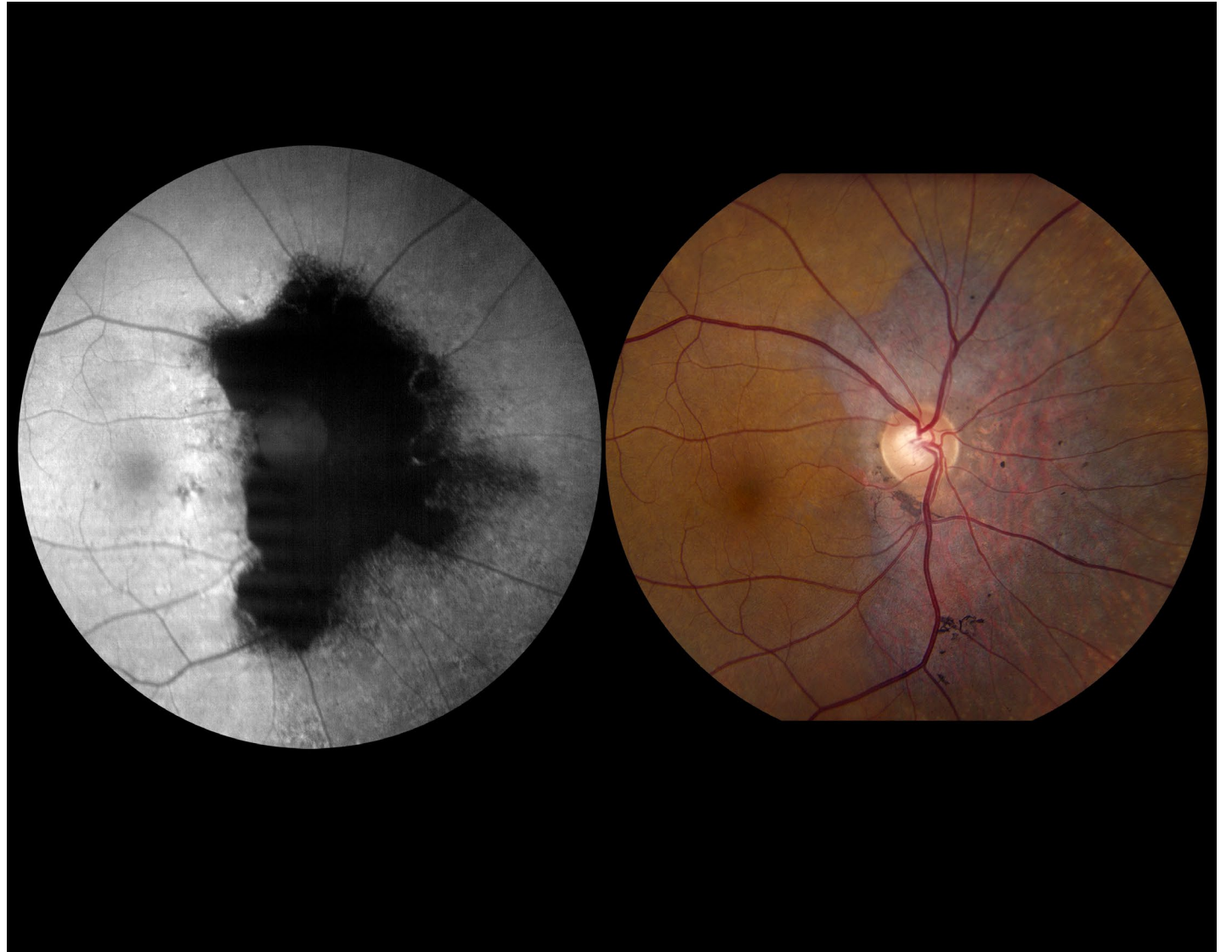By: Sean Grout, OCT-C
UNC Hospital





Optic Disc Atrophy

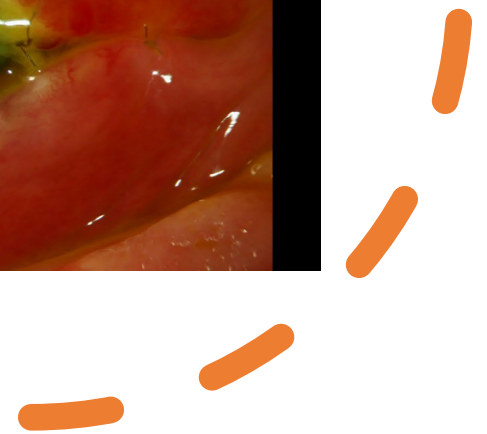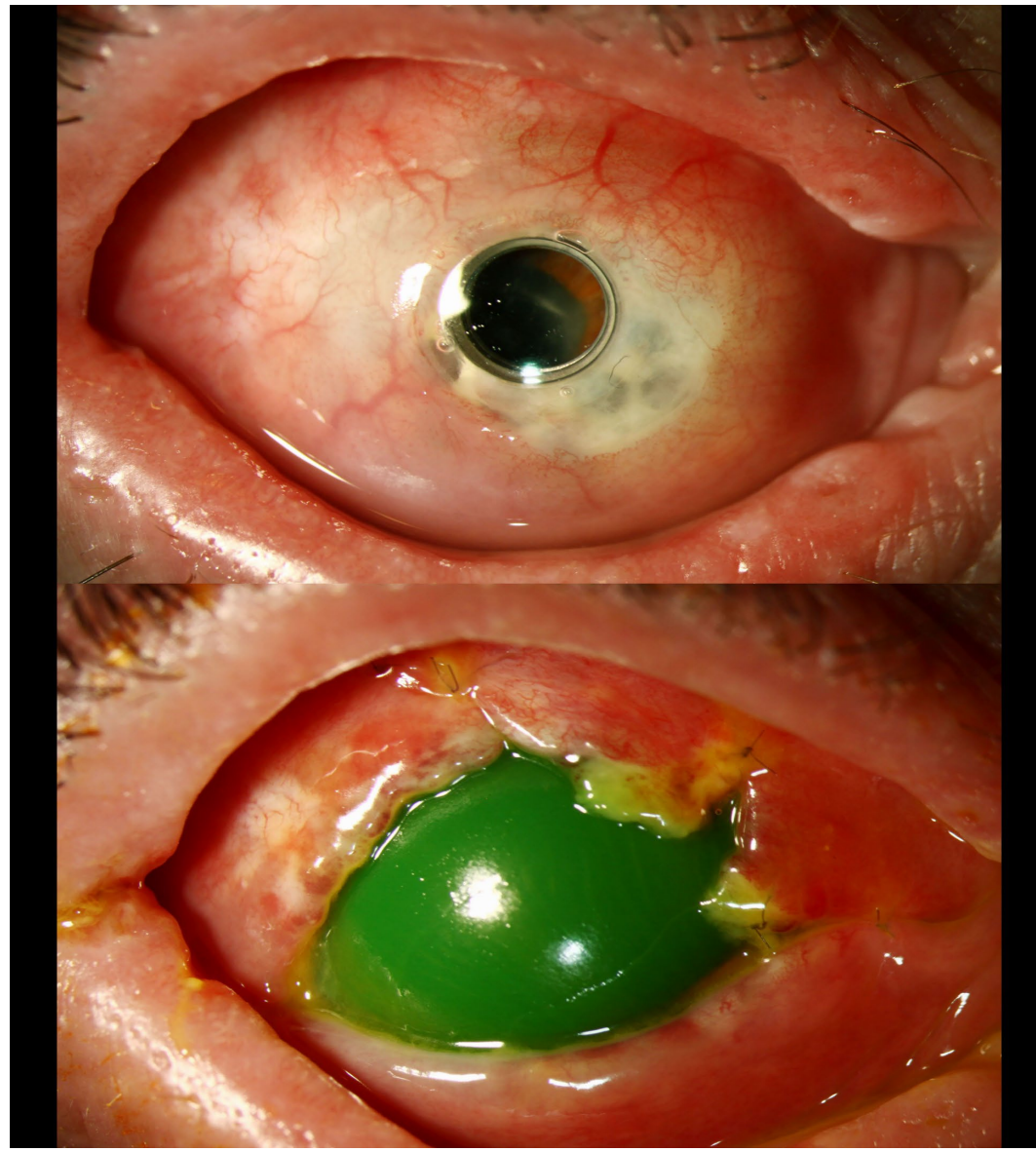
By: Sarah L. Skiles
University of Iowa
Hospitals and
Clinics

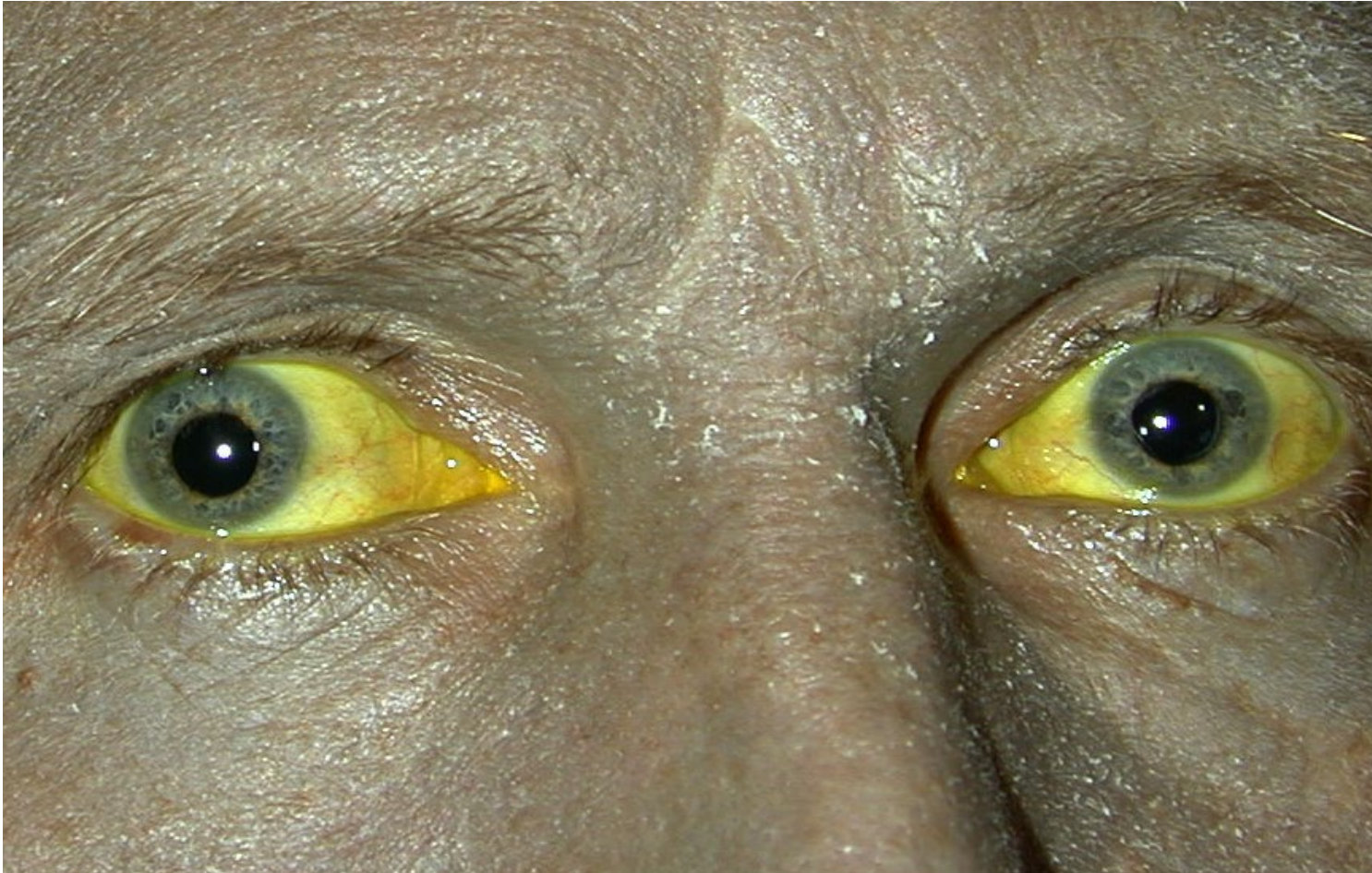

External Photography



Before and after
K-Pro Removal
By: Sarah S. Skiles
University of
Iowa Hospitals
and Clinics





Argyrosis

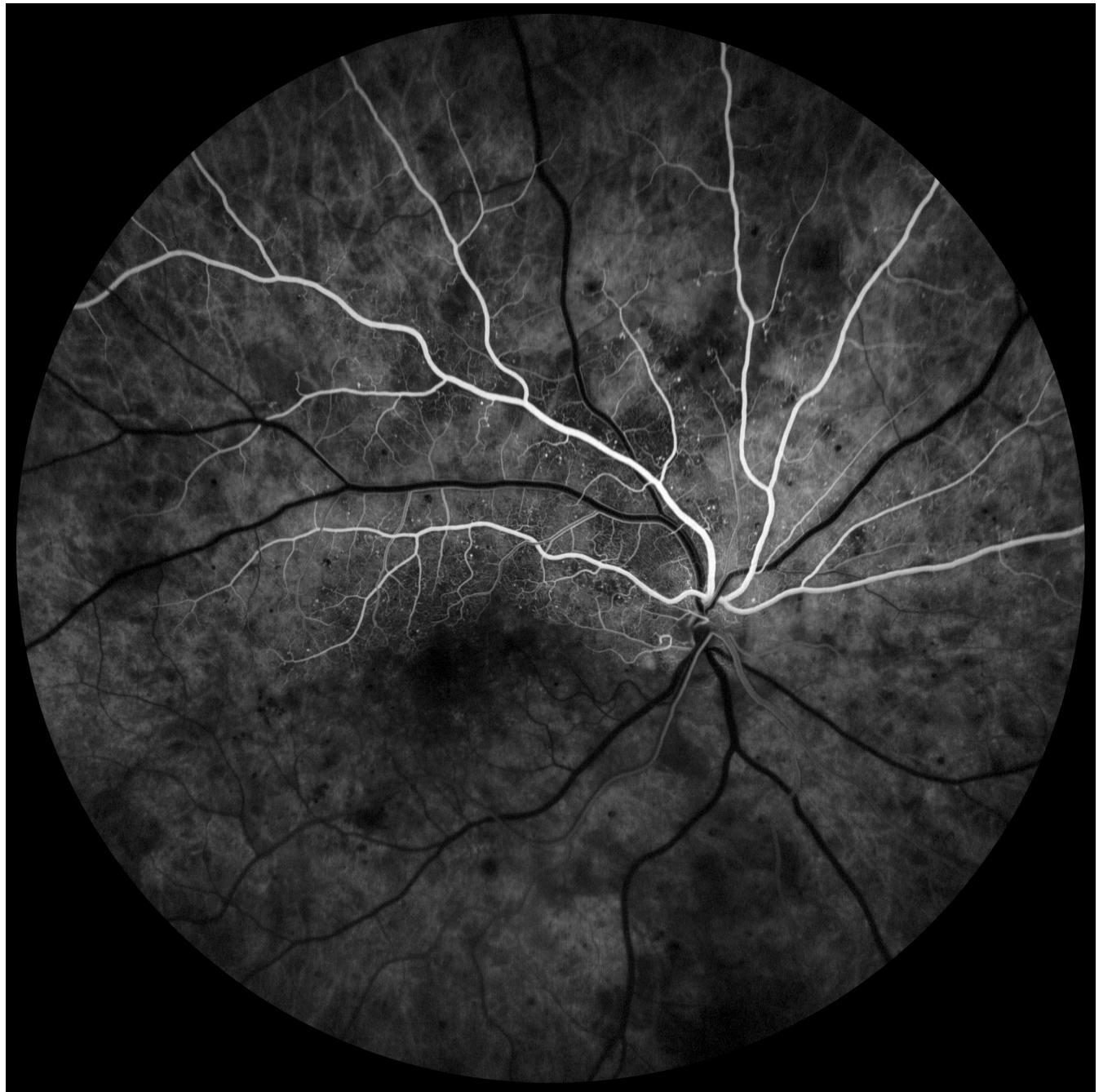
By: Denice Barsness

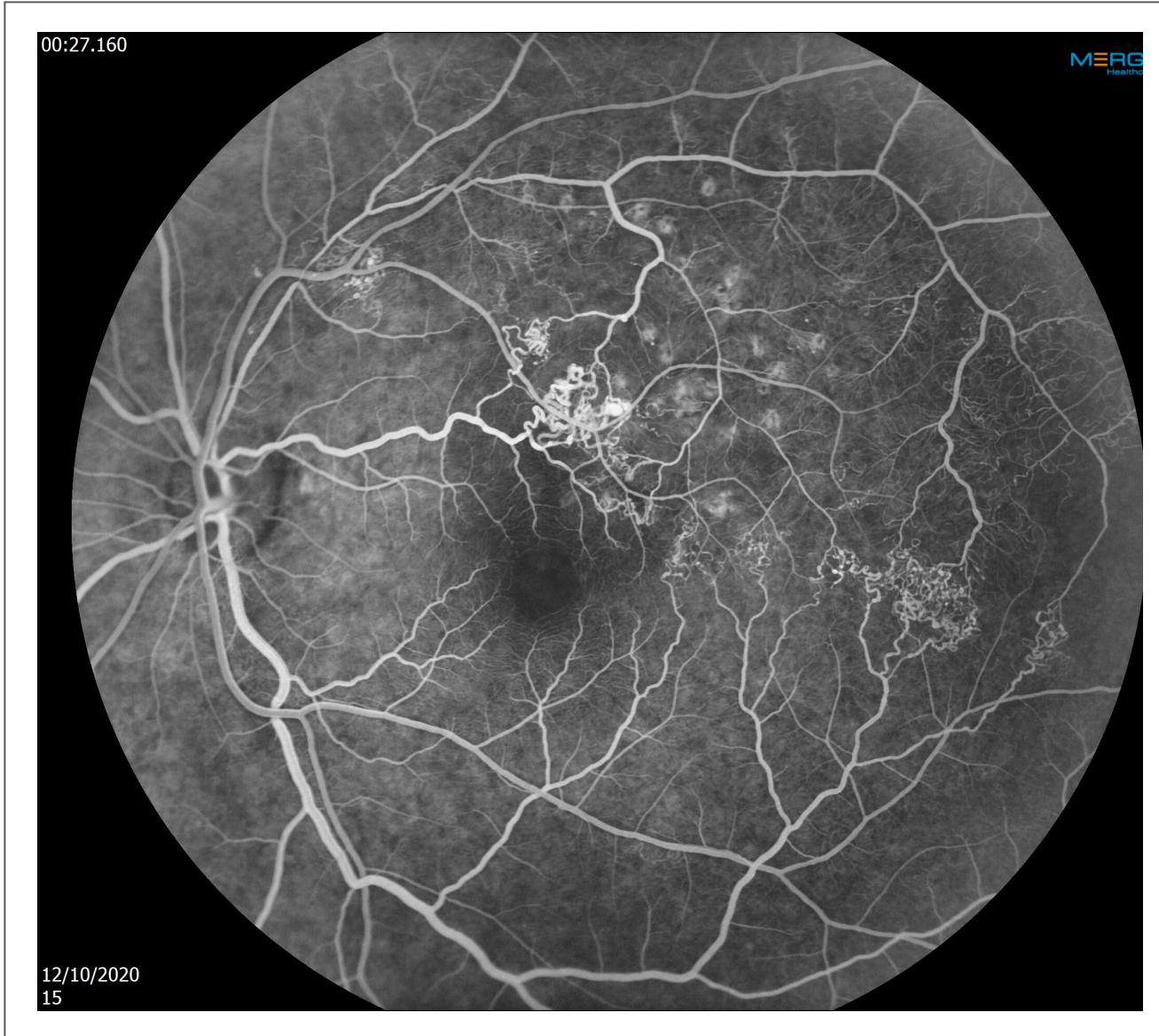
**California Pacific
Medical Center Dept.
of Ophthalmology**

Fluorescein Angiography

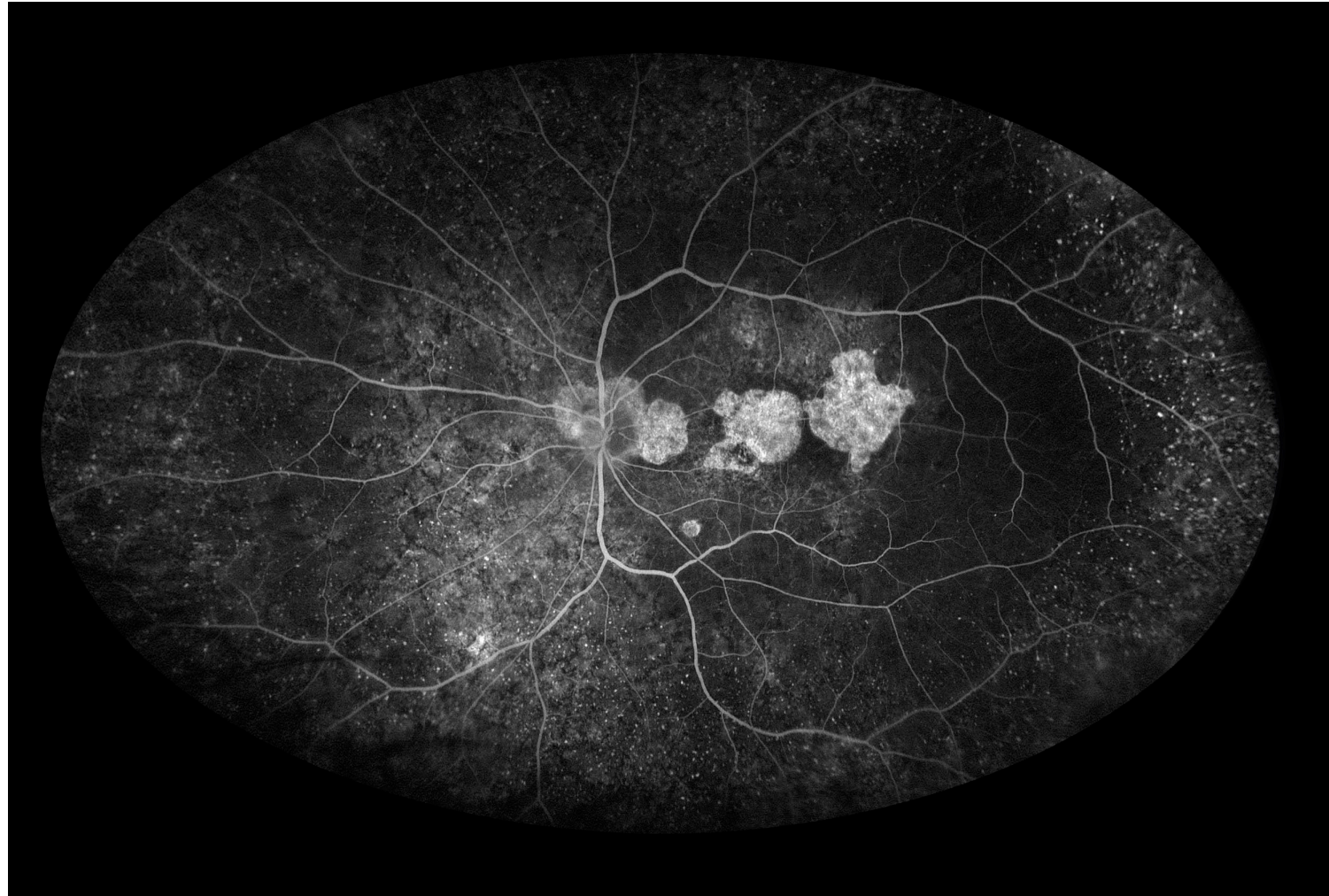
Diabetic Macular Edema with Non-Proliferative Diabetic Retinopathy

By: Anahli Jazhmin
Vazquez-Galvan, OCT-C
Kresge Eye Institute





BRVO (?HTN)
By:Bradley Stern
Henry Ford Health System

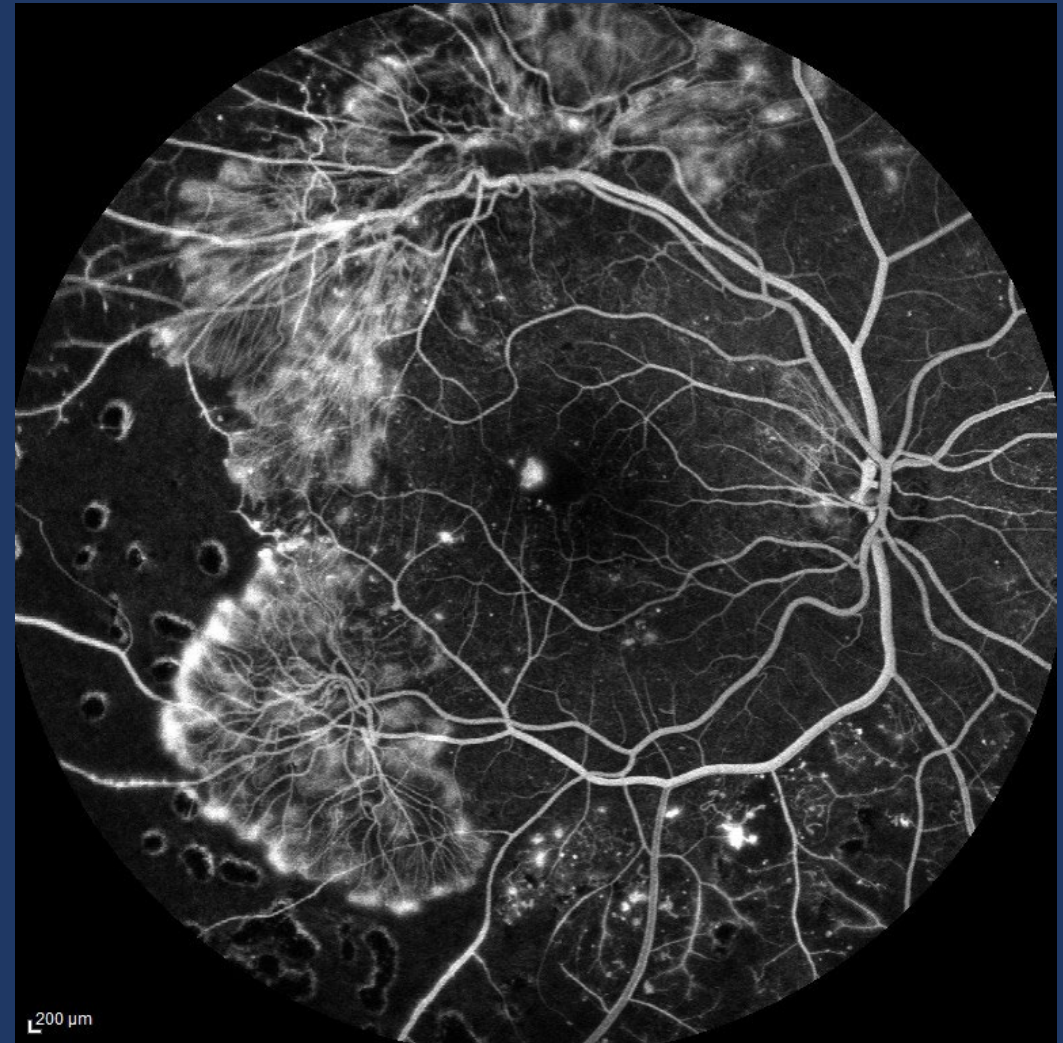


Tubercular
Serpiginous-like
Choroiditis
By: Sara Ash
Kresge Eye
Institute



Florid PDR

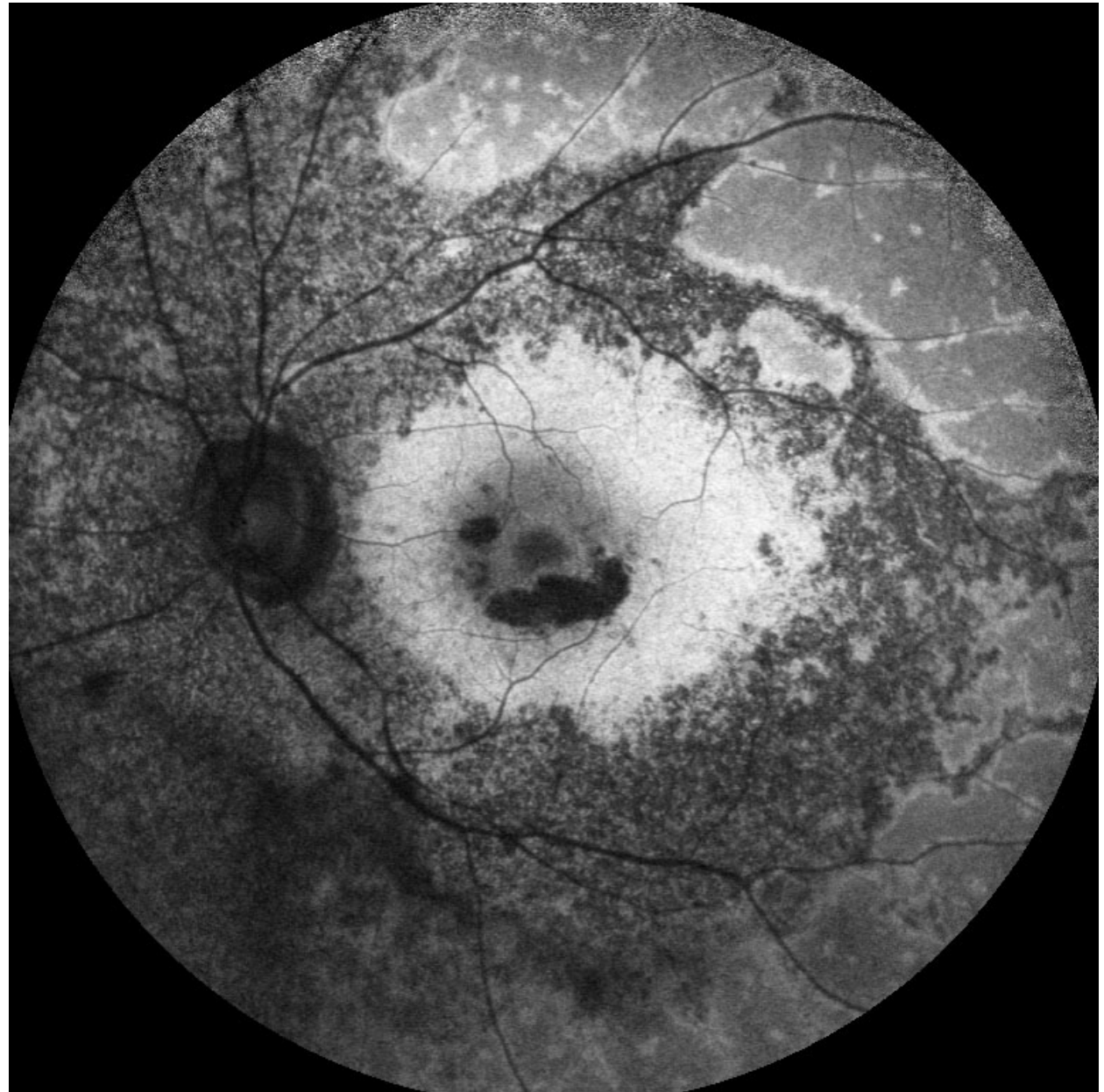
By: Denice Barsness
California Pacific
Medical Center Dept.
of Ophthalmology



Fundus Autofluorescence

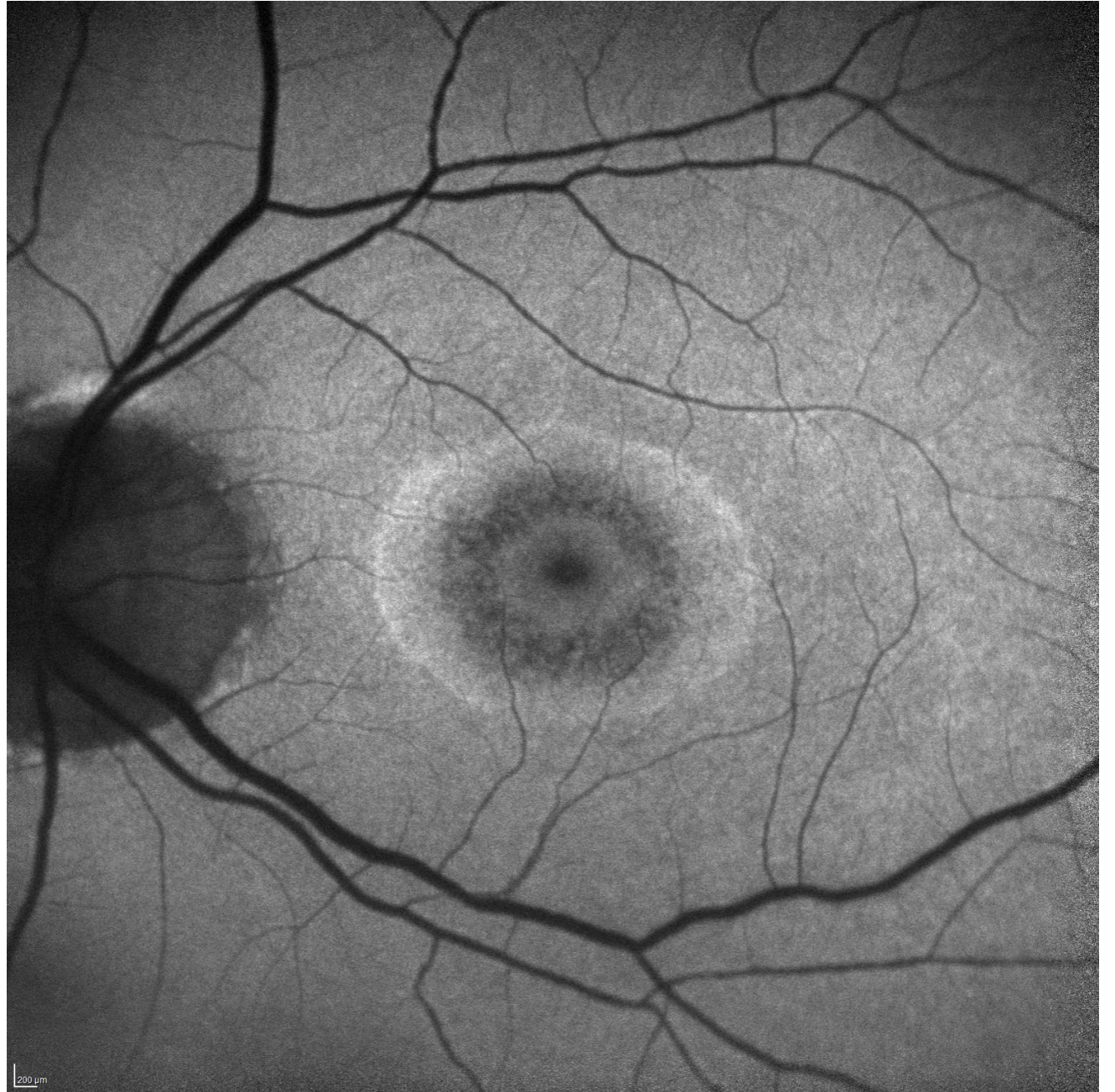
Azoor

By: Sarah Skiles
University of Iowa
Hospitals and
Clinics



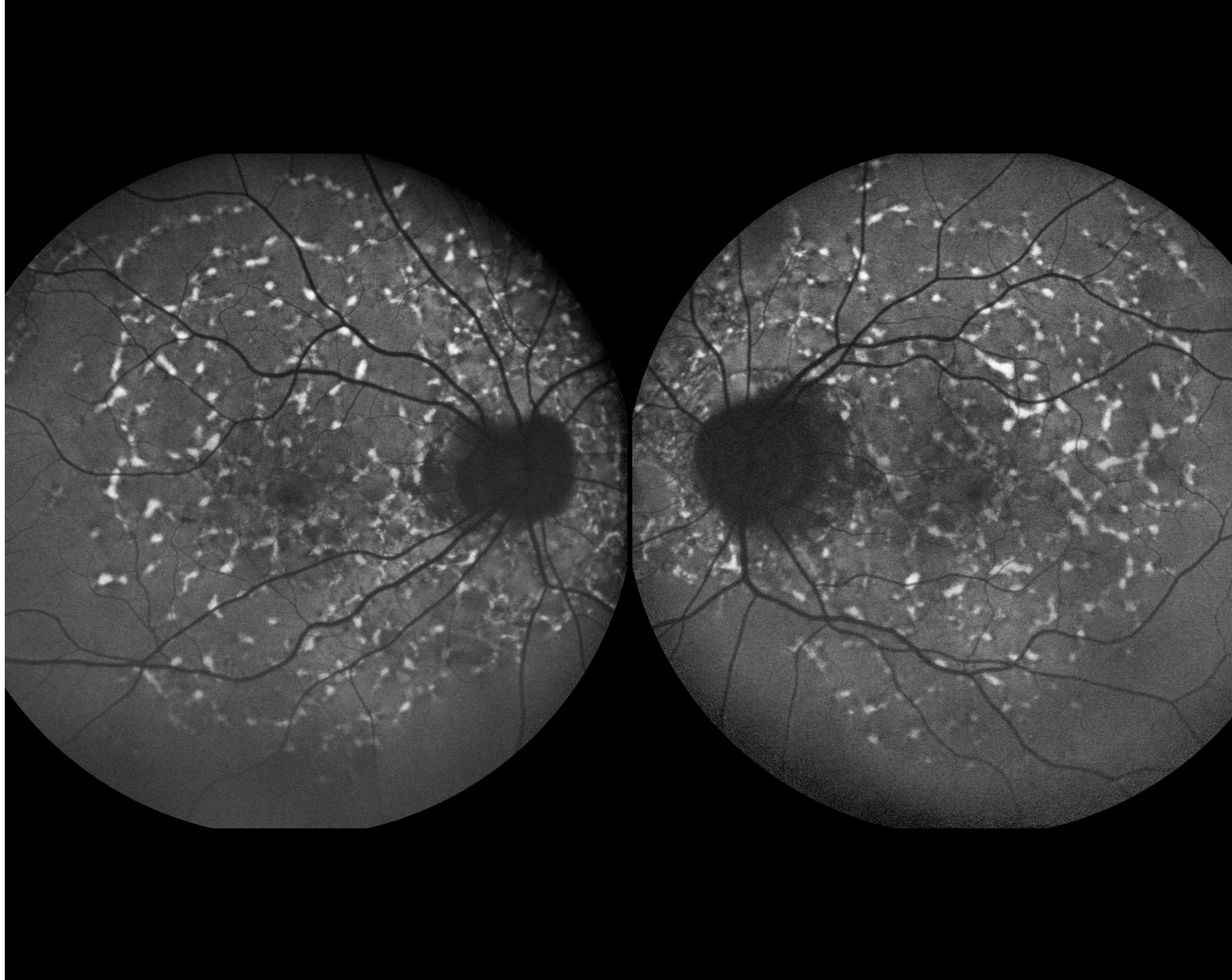
Plaquenil Toxicity

By: Darrin A.
Landry, CRA,
OCT-C
Eyecare
Medical Group



Stargardts

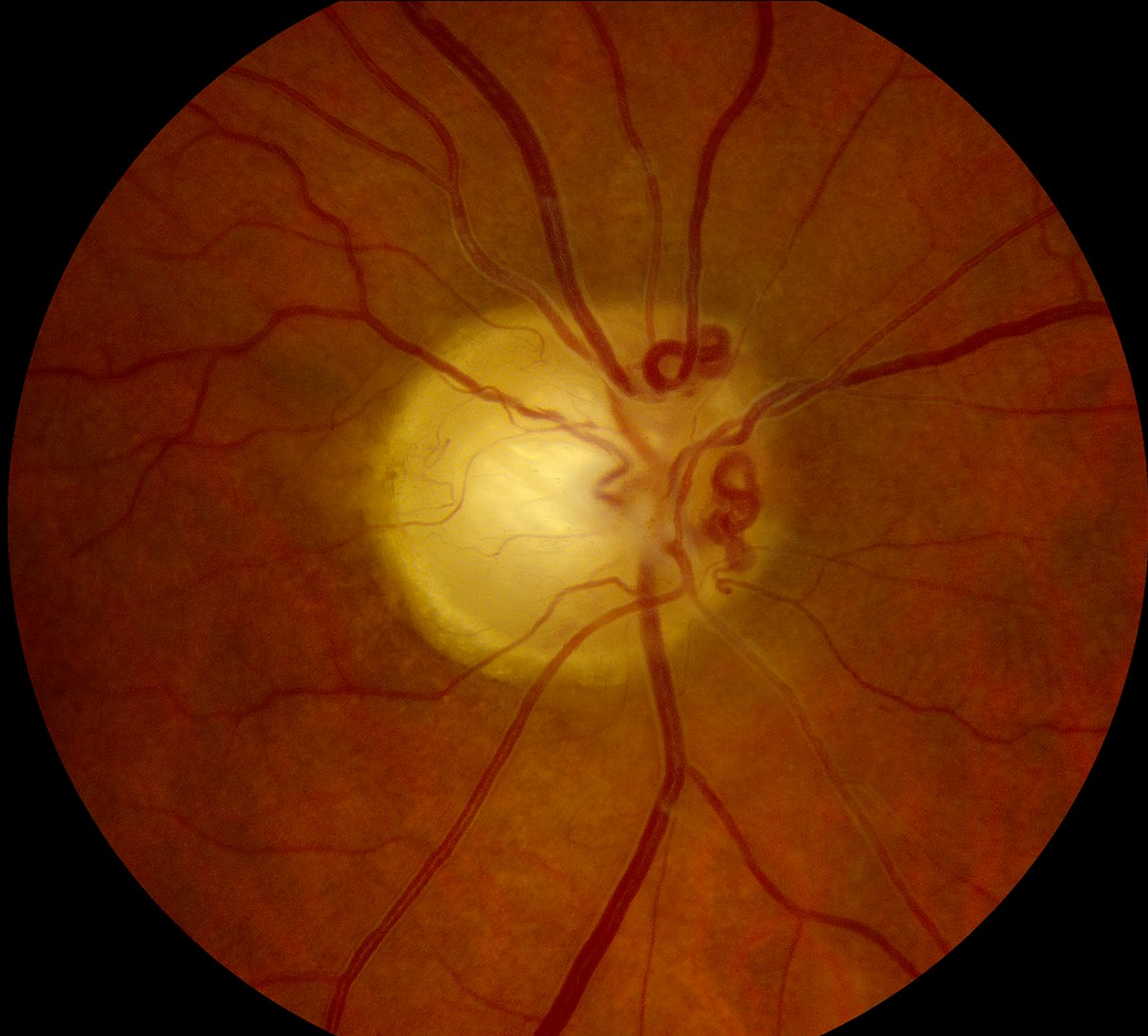By: Darrin A.
Landry, CRA, OCT-C
Eyecare Medical
Group



Fundus Photography, High Magnification, 20°

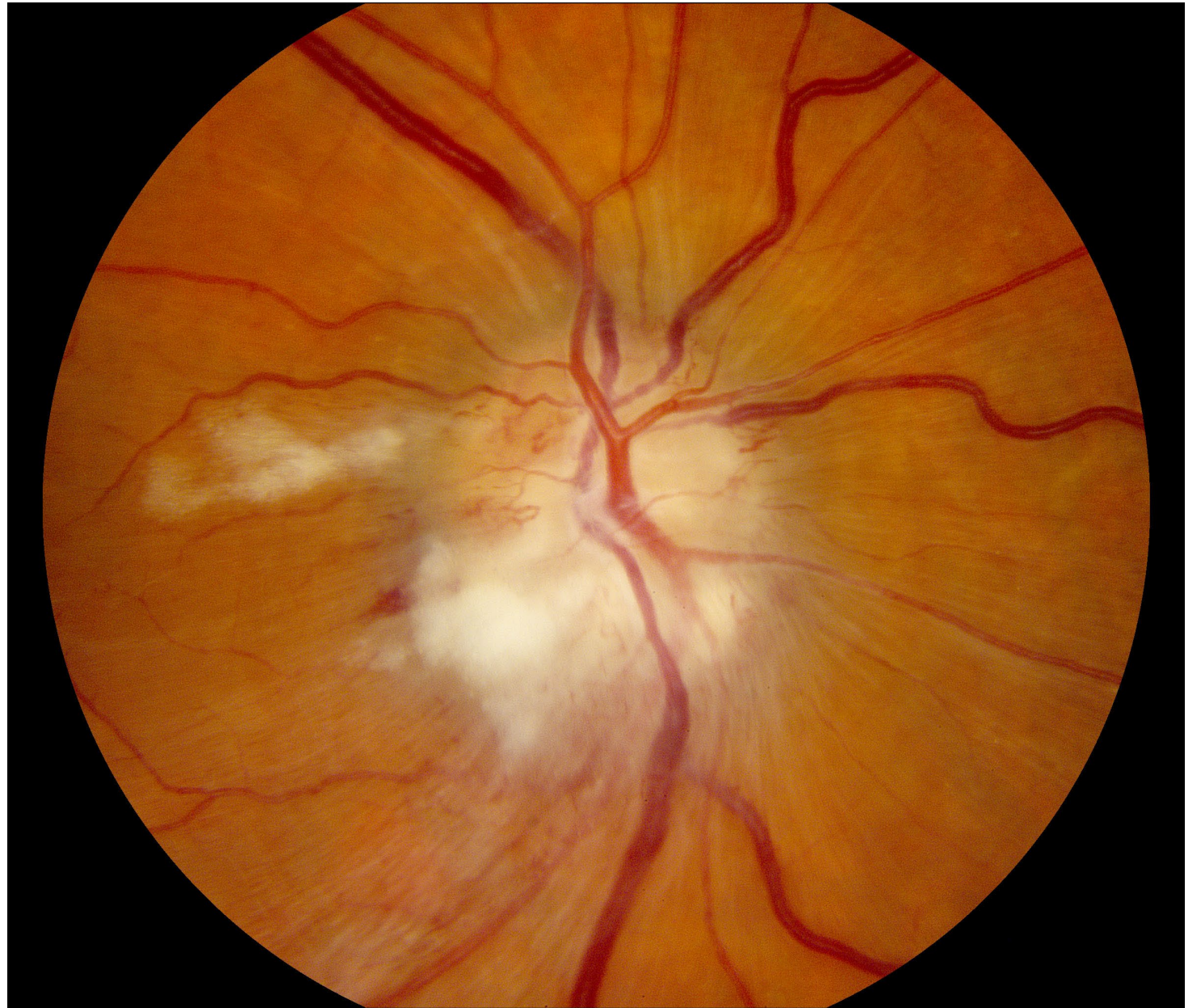Acute Endophthalmitis and Crvo

Jody Troyer, CRA
University of Iowa
Hospitals and
Clinics Department
of Ophthalmology

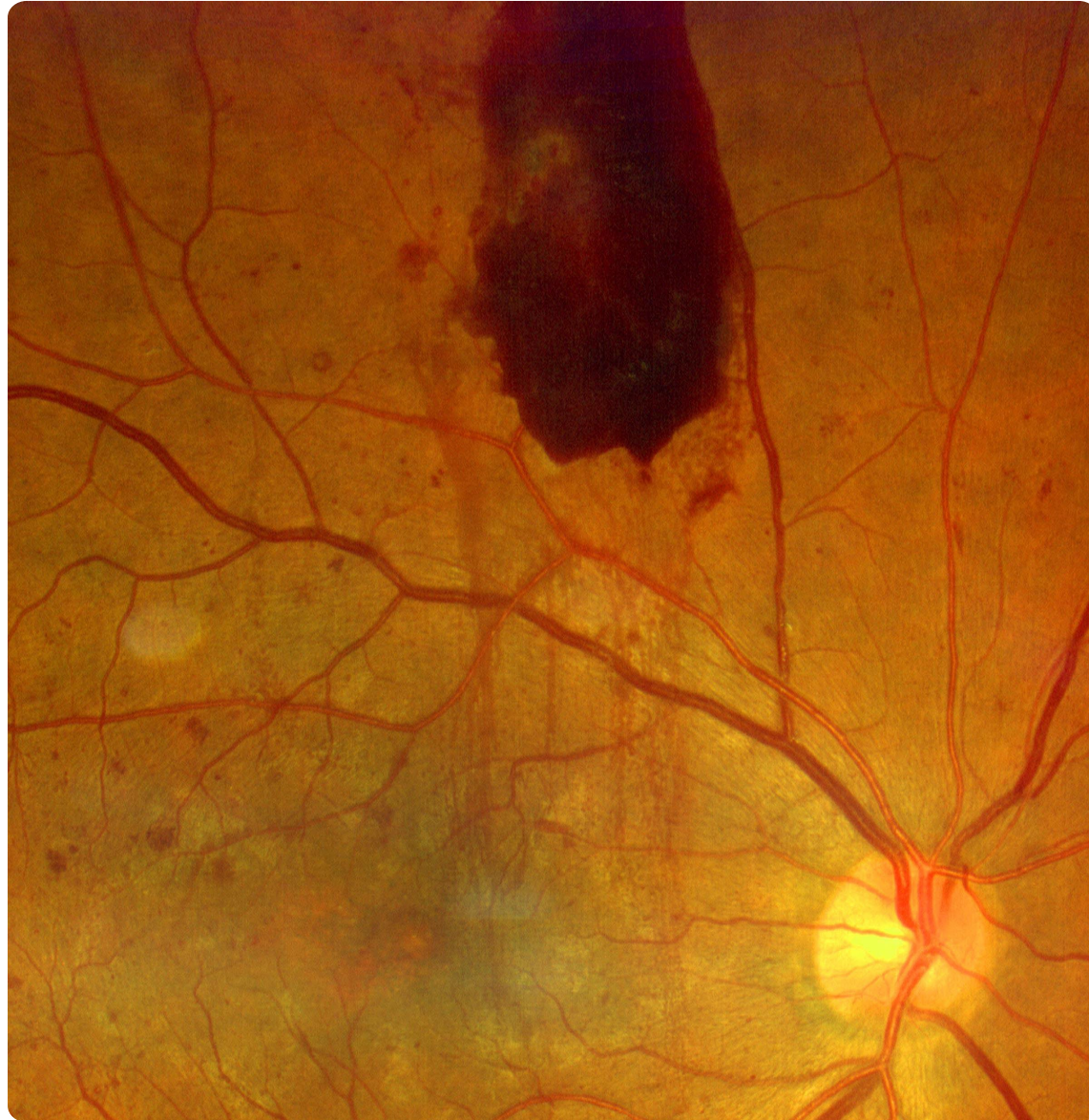

Optic Disc Edema

Sarah L. Skiles
University of Iowa
Hospitals and
Clinics



Fundus Photography,
Normal, 30°-40°



PDR Retinal Hemorrhage

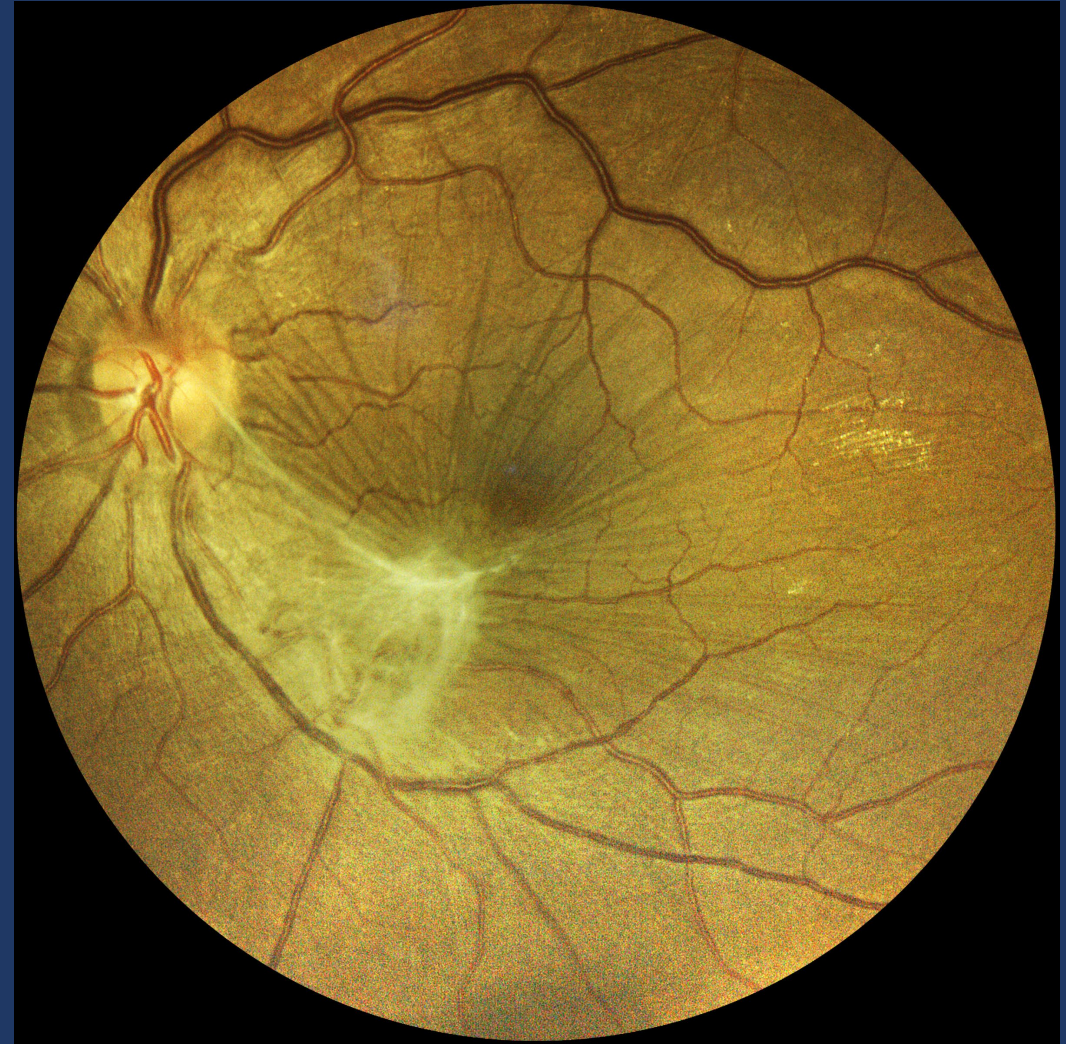By: Darrin A.
Landry, CRA, OCT-C
Eyecare Medical
Group





Resistance of the Pull - Epiretinal Membrane with Vitreo-Macular Traction

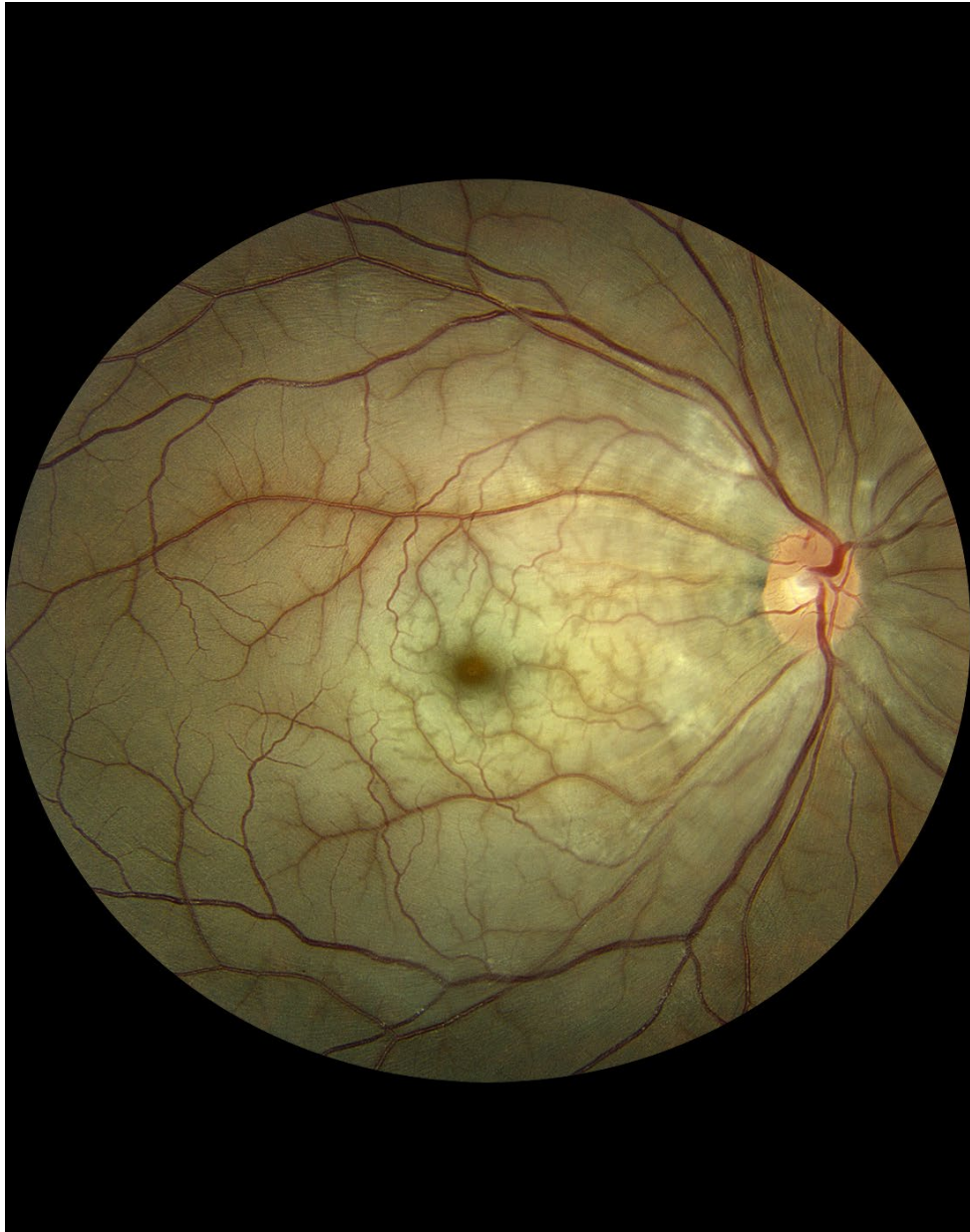
By: Prasanna
Venkatesh Ramesh
Mahathma Eye
Hospital Private
Limited

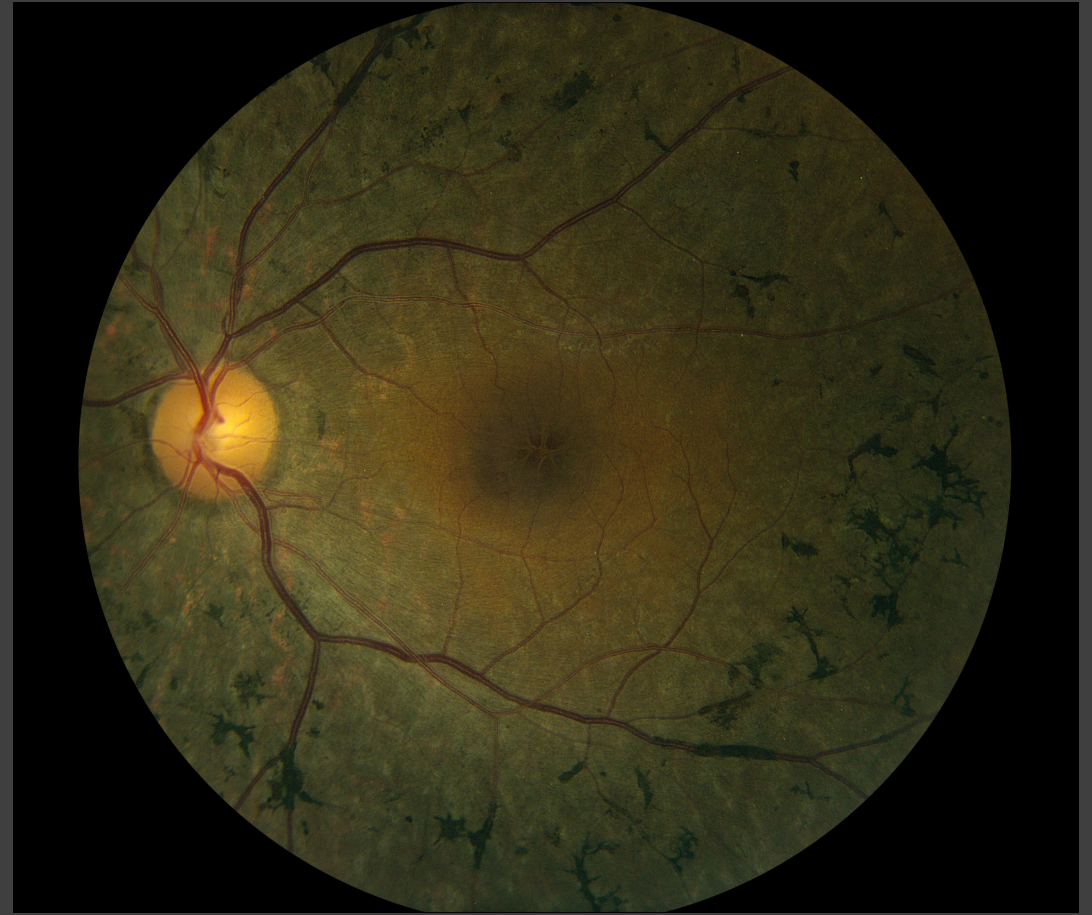
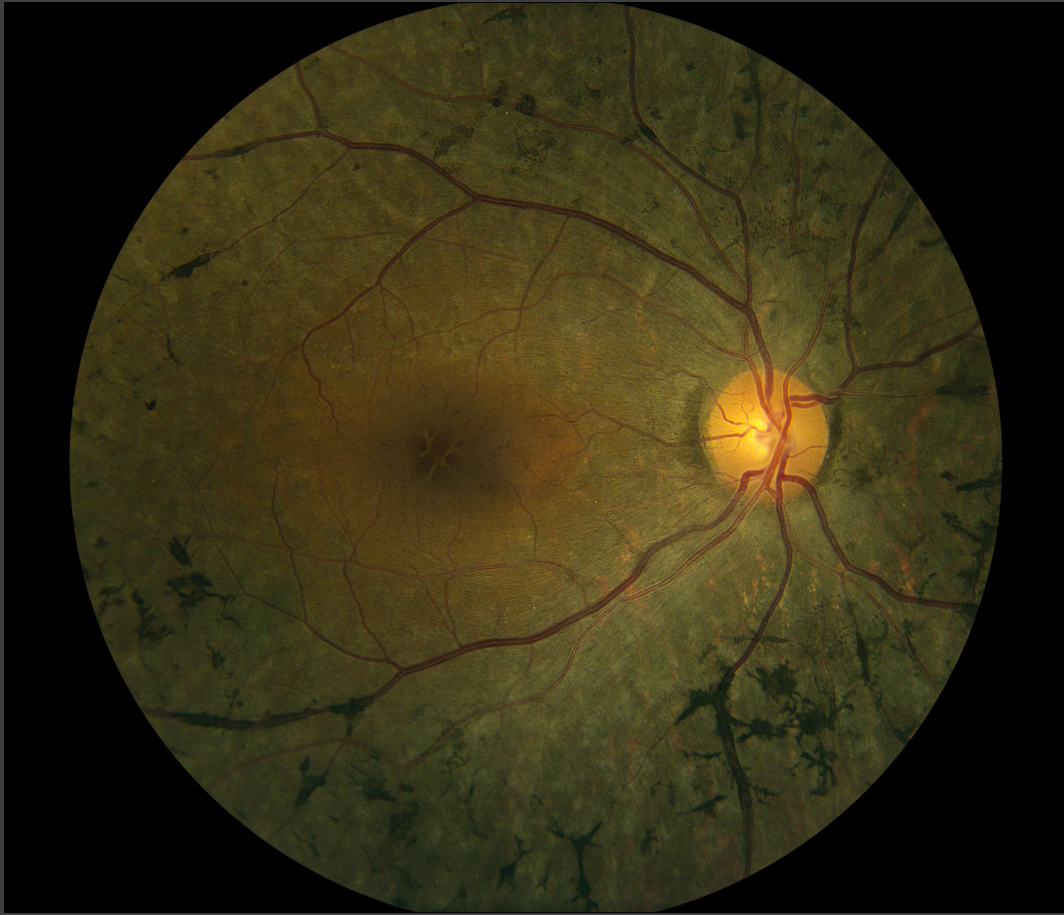
Fundus Photography, Wide Angle, 45°+

Central Retinal Artery Occlusion

By: Jody Troyer, CRA
University of Iowa Hospitals
and Clinics Department of
Ophthalmology



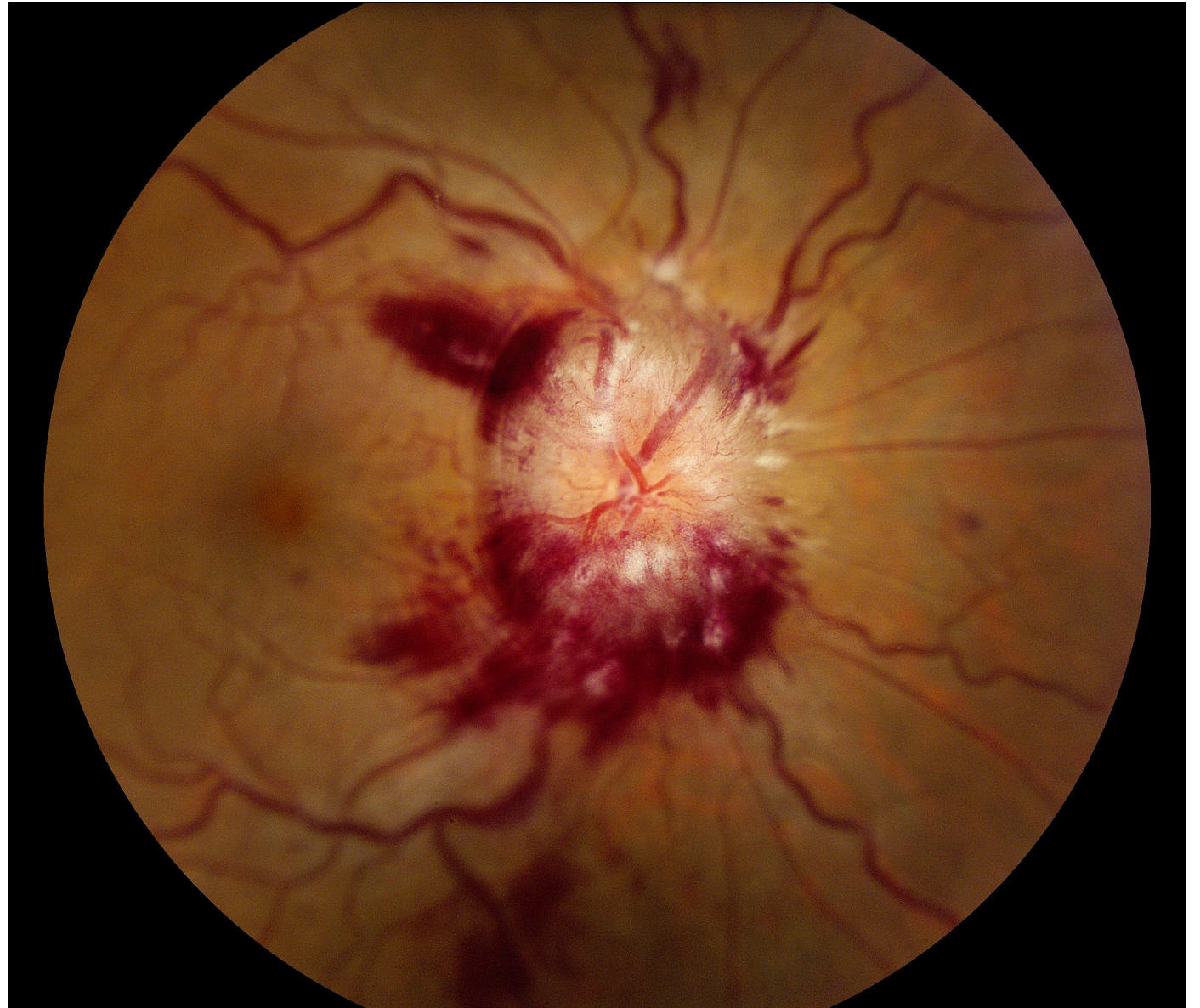

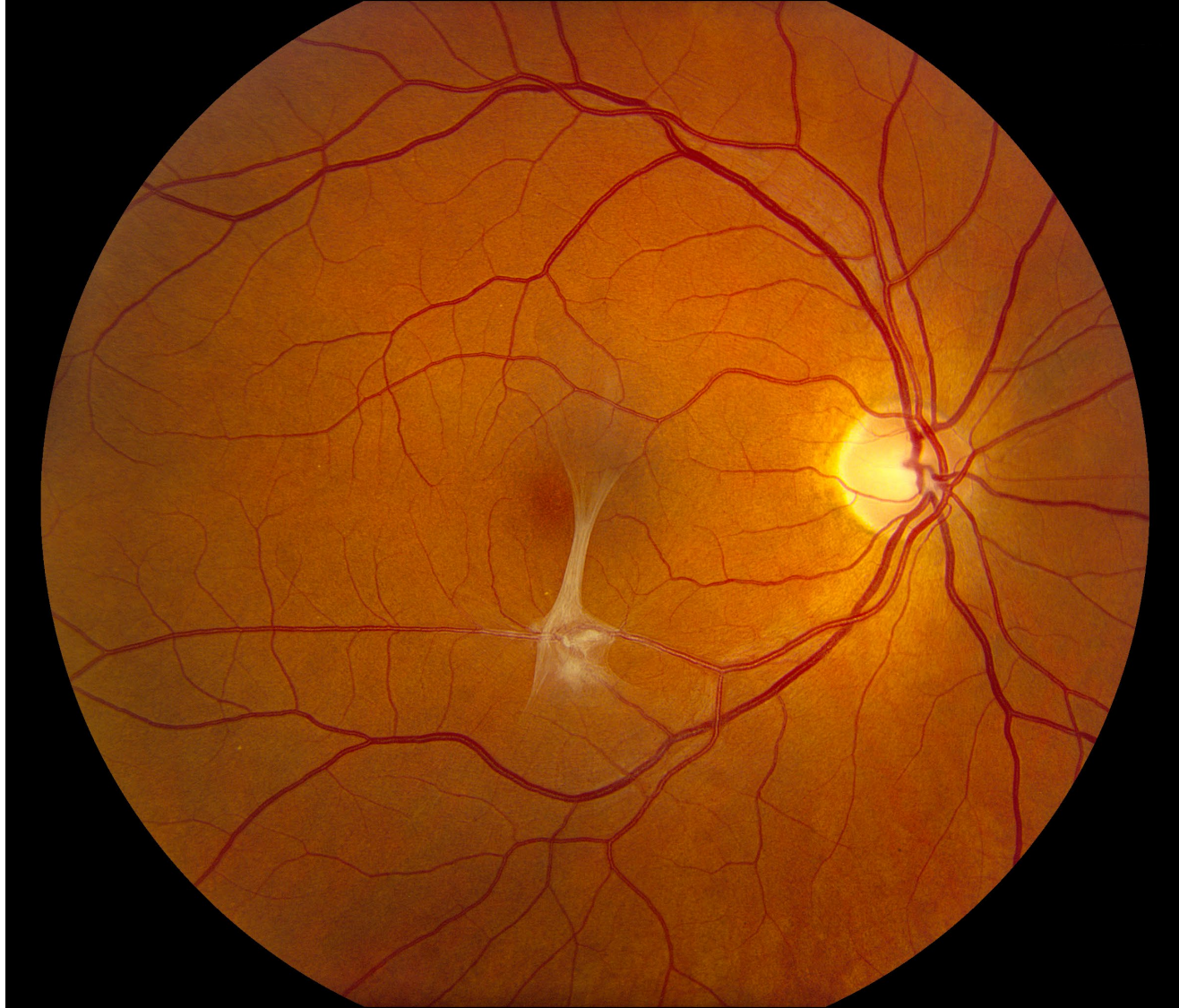
RP with CME
Tracey Troszak
Henry Ford Health System



Papilledema

By: Sarah L Skiles
University of Iowa
Hospitals and
Clinics





Vmt
By: Derick Ashley
Henry Ford Health
System

Gonio Photography



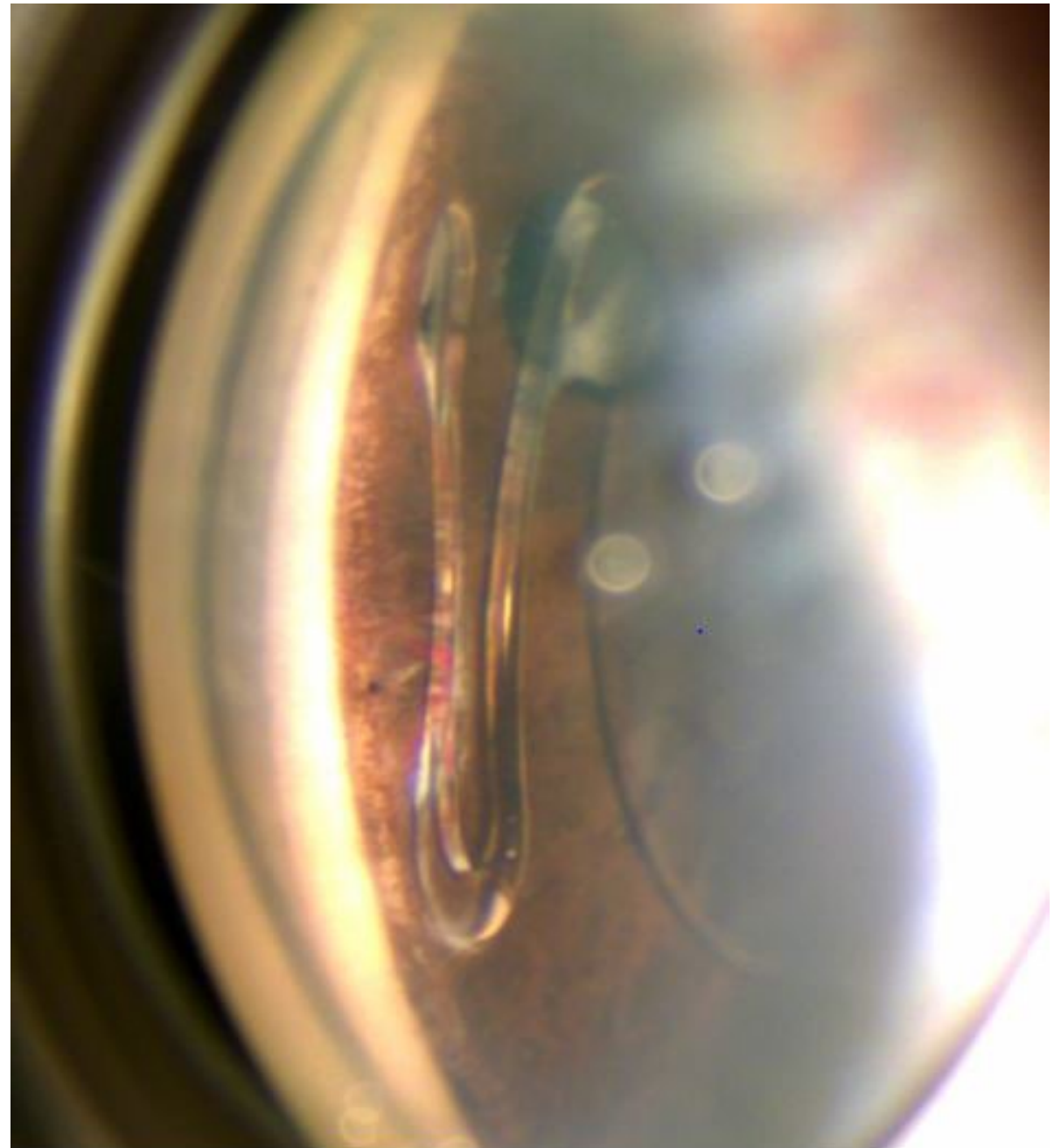
Surreal Roots of the Rudimentary Iris Stump - Aniridia

By: Prasanna
Venkatesh Ramesh
Mahathma Eye
Hospital Private
Limited



Kelman IOL with Iris Neovascularisation

By: Surinder
Kumar
Dr Haifa Eye
Hospital, Bahrain.



Gross Specimen Photography





Extruded IOL

By: Denice
Barsness
California Pacific
Medical Center
Dept. of
Ophthalmology

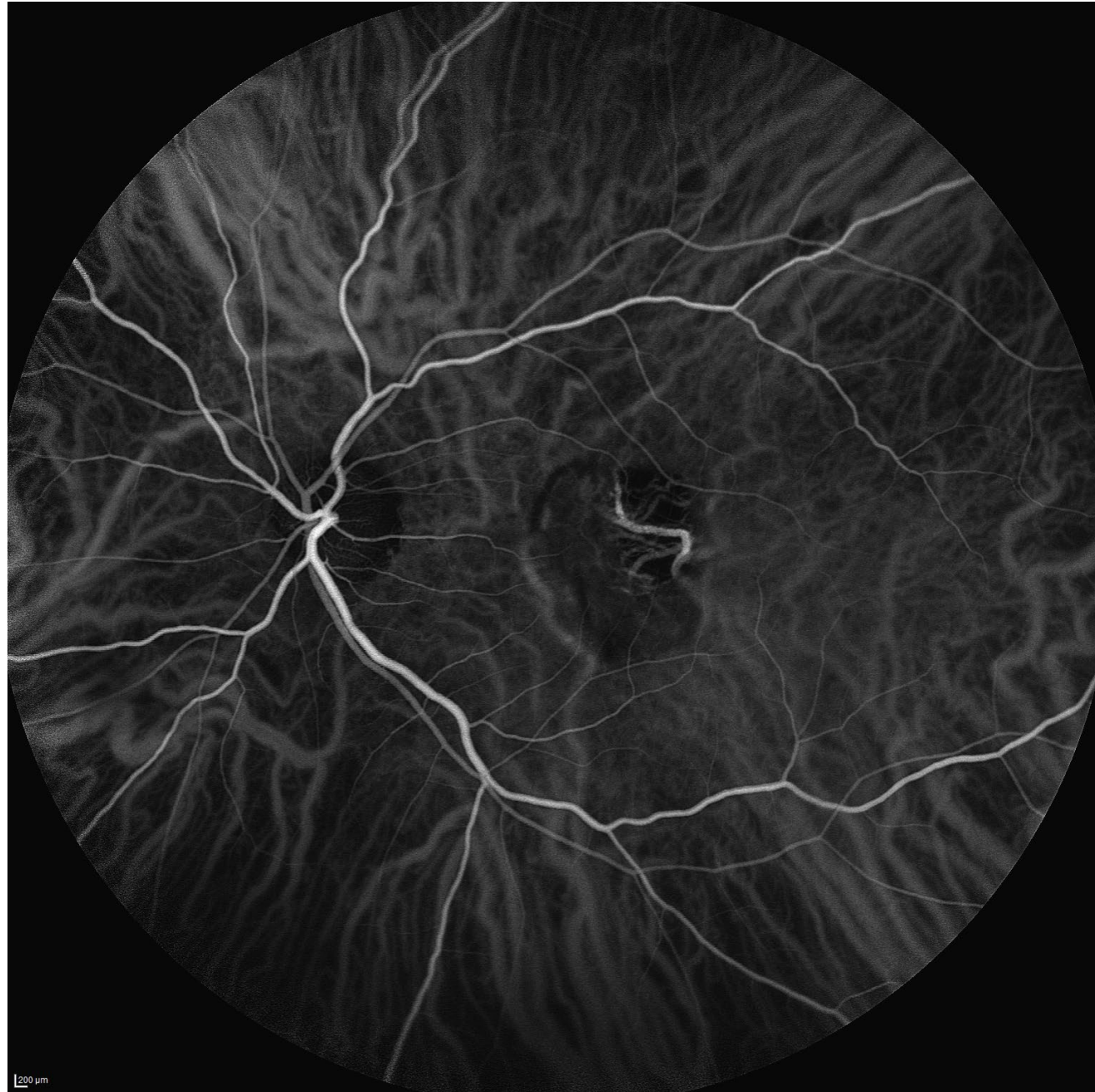

ICG Angiogram



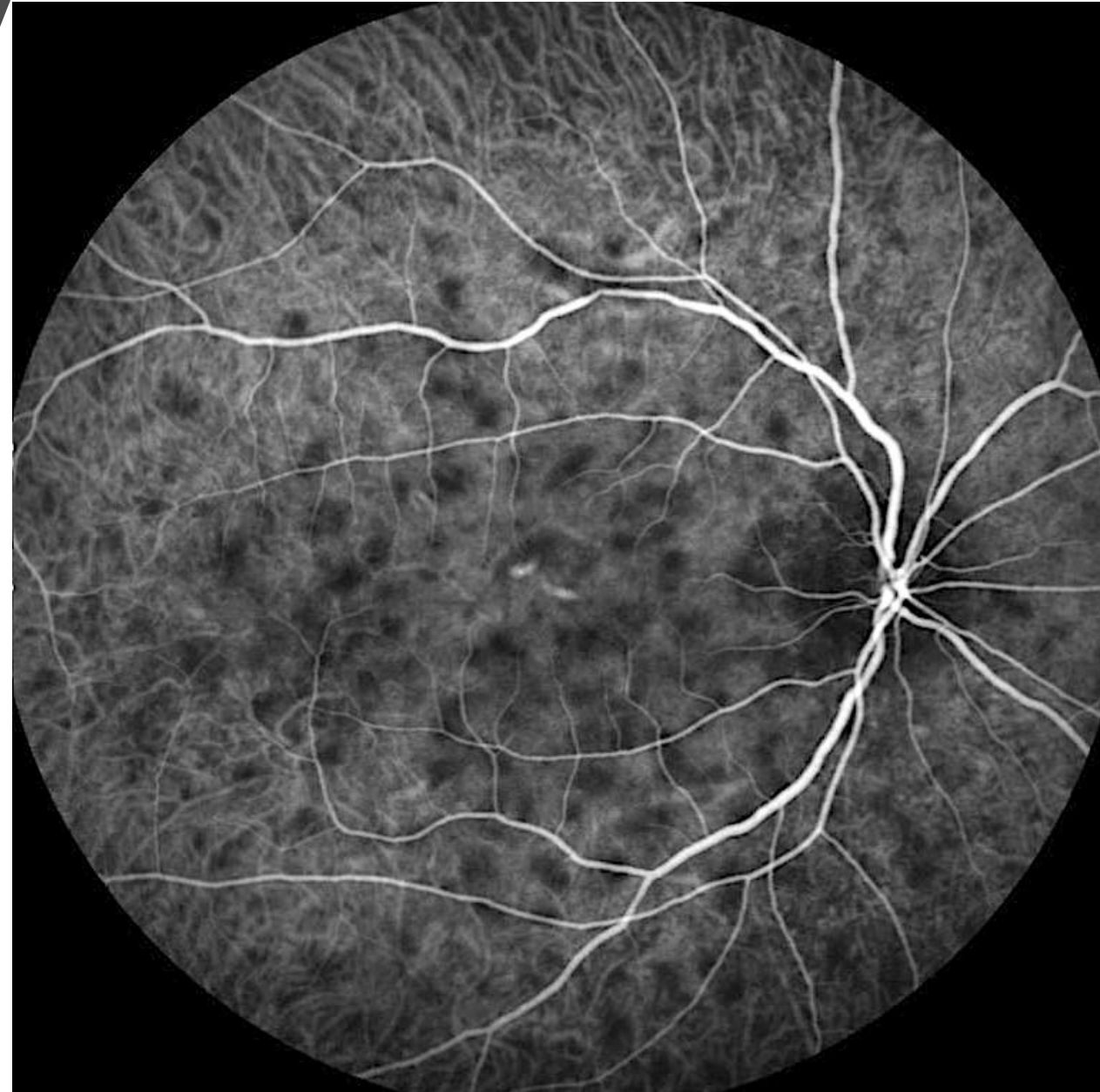
Feeder Vessel

By: Darrin A. Landry,
CRA, OCT-C
Eyecare Medical Group



Gleaming in the Gloom - Vogt-Koyanagi-Harada Disease

By: Prasanna Venkatesh Ramesh
Mahathma Eye Hospital Private Limited




Instrumentation Photography





The 3D Holographic Metaverse with Hololens 2 - Future of Ophthalmic Counseling

By: Prasanna Venkatesh
Ramesh
Mahathma Eye
Hospital Private
Limited

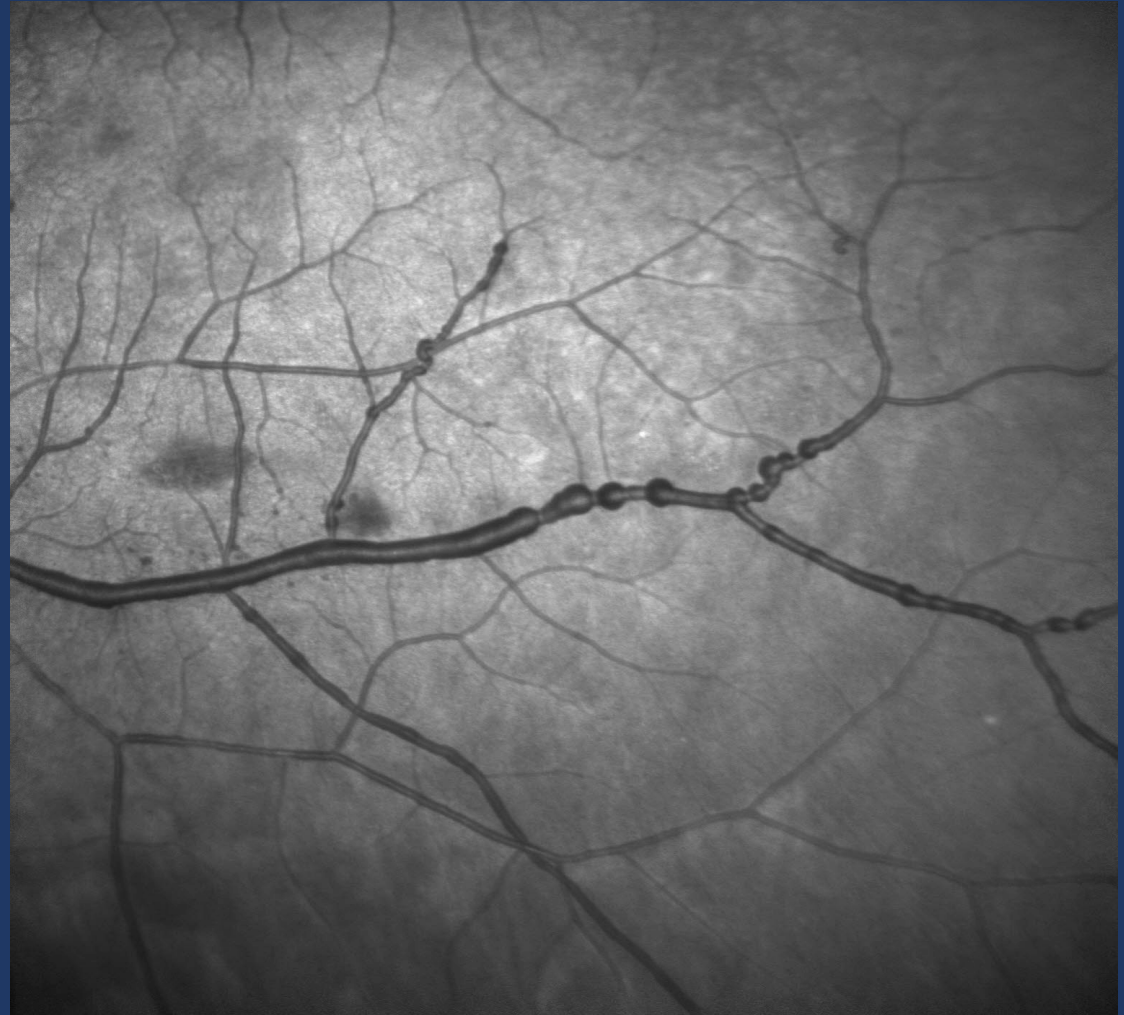

Monochromatic Photography



Vascular Beading

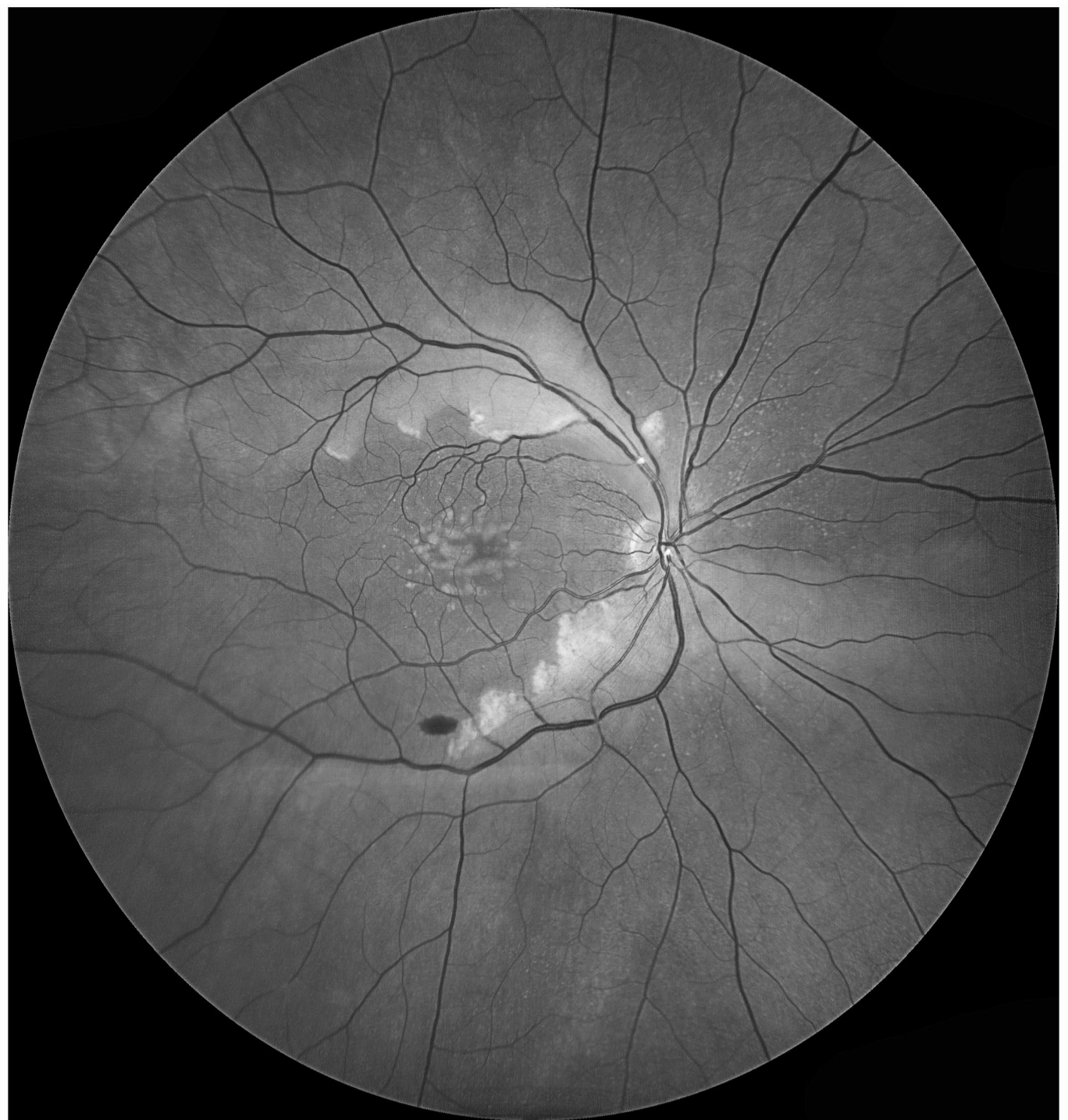By: Matt Raeber
Spokane Eye
Clinic





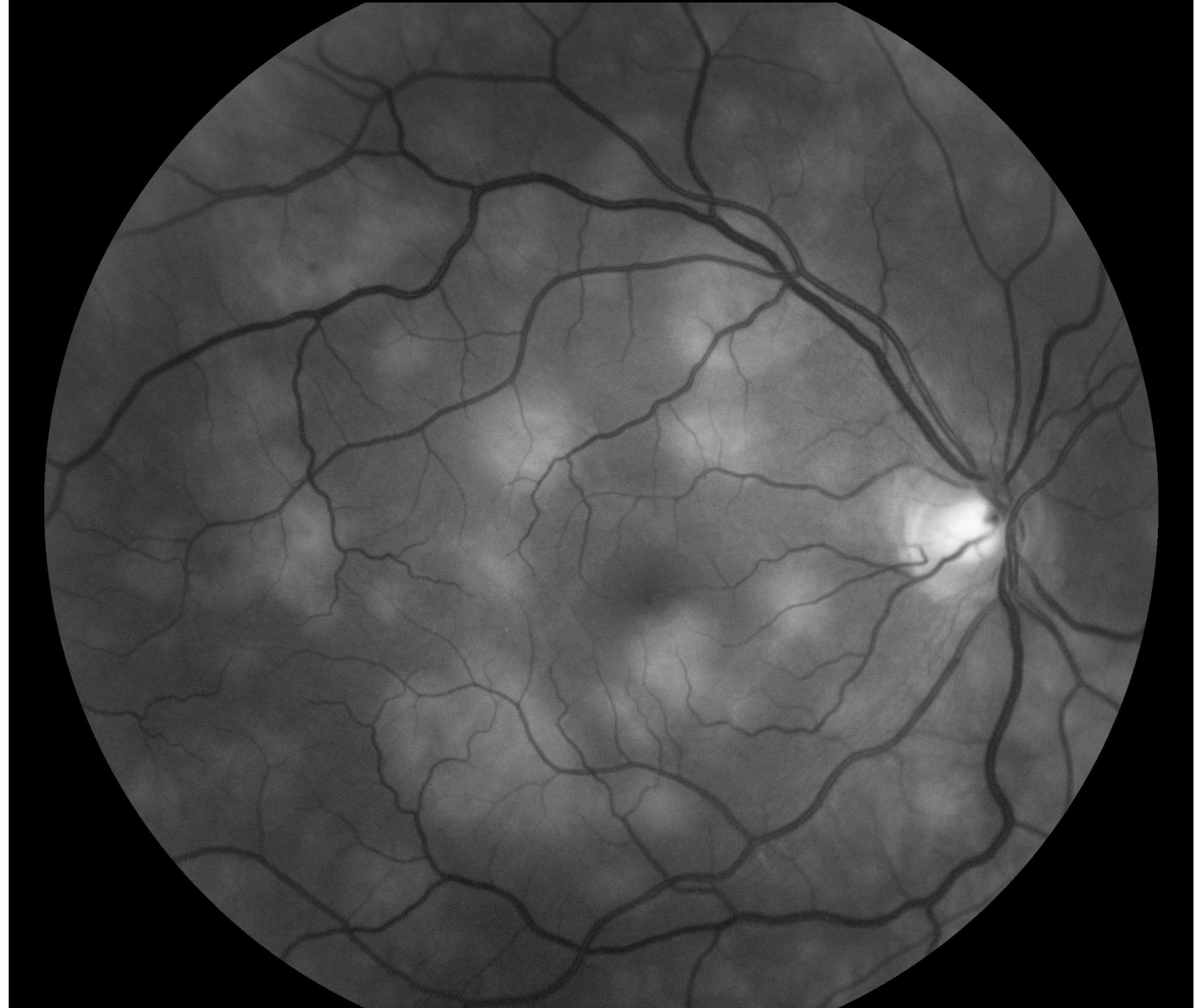Brao Redfree

By: Nicole
Mantel
Inselspital,
Bern

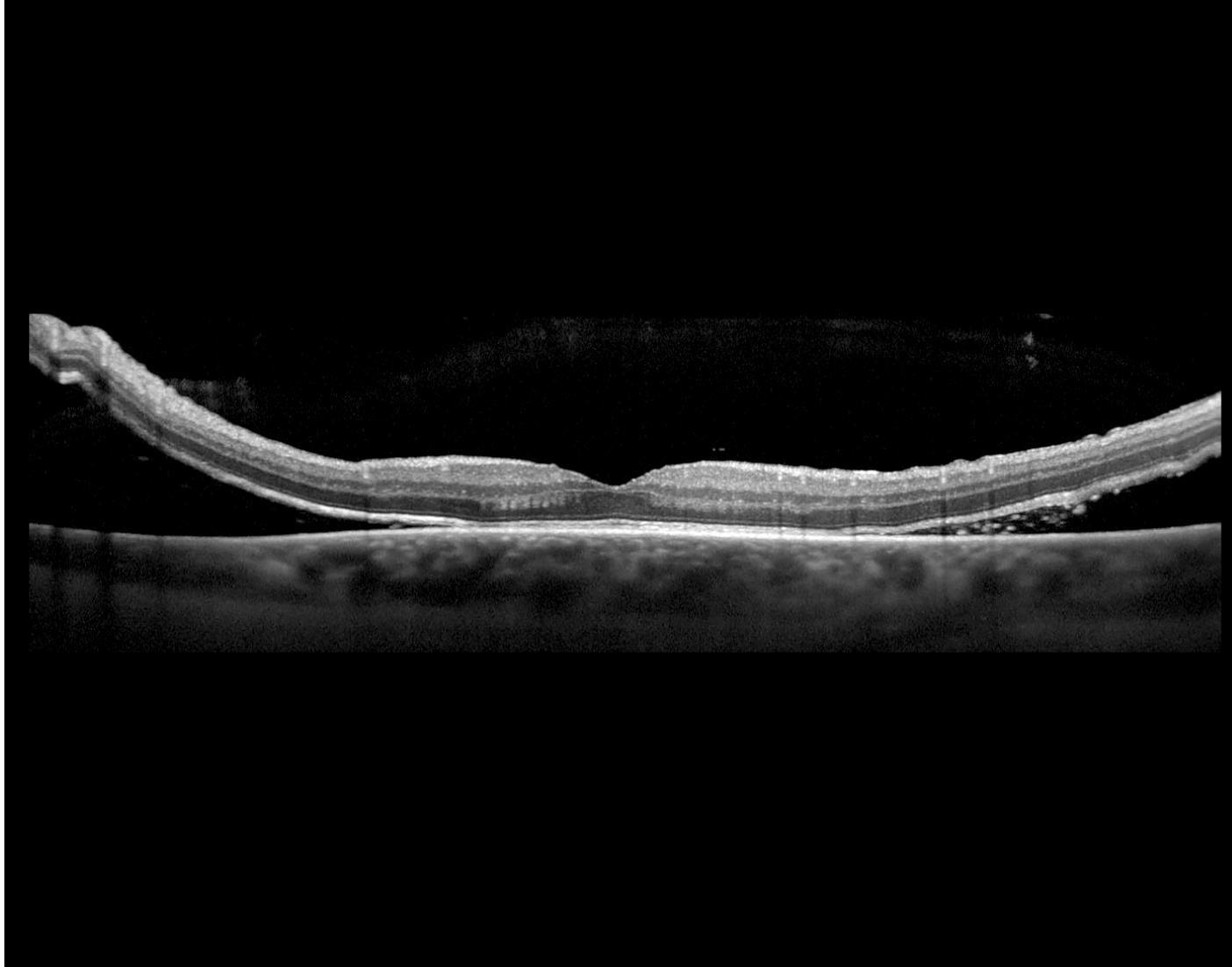


Mewds

**By: Lina K Olsauskas
Illinois Retina Associates**



Optical Coherence Tomography



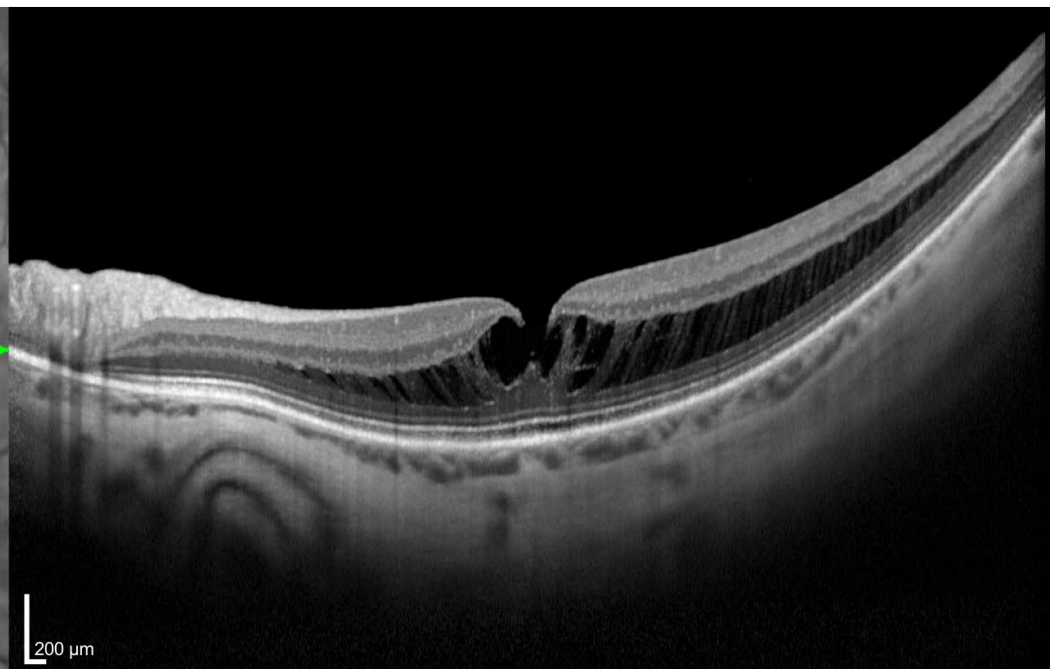
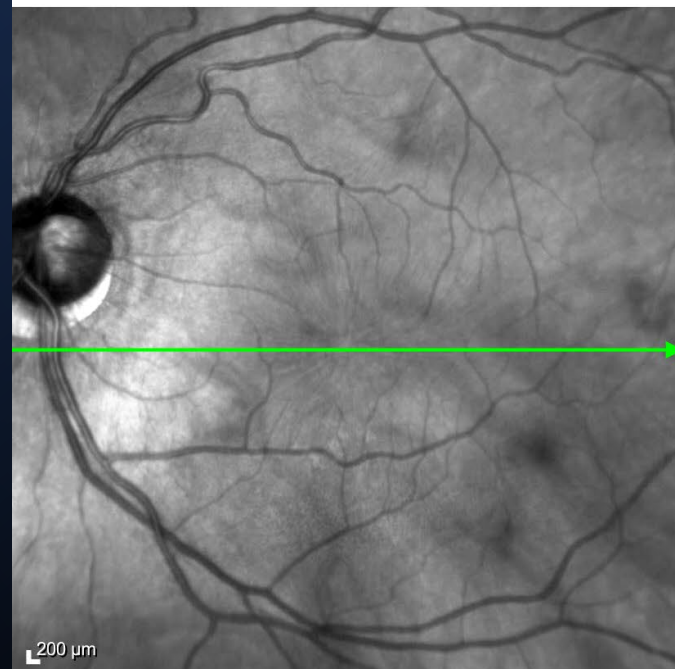
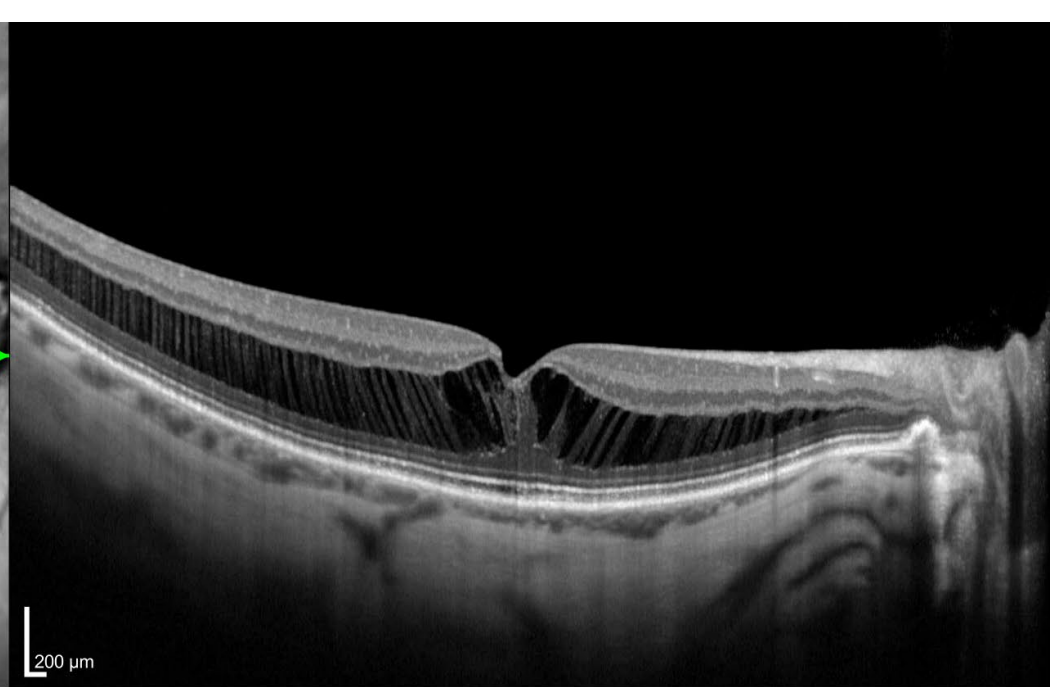
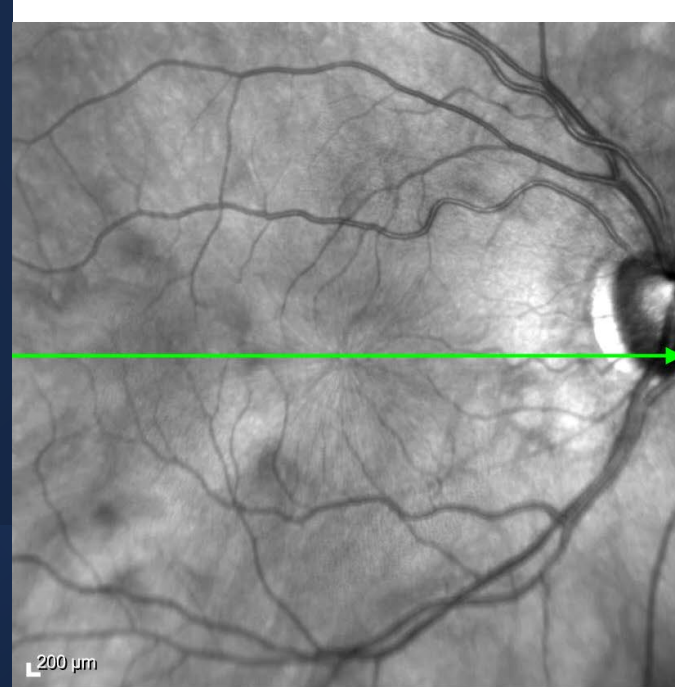
Mac-on Retinal Detachment from Multiple Directions

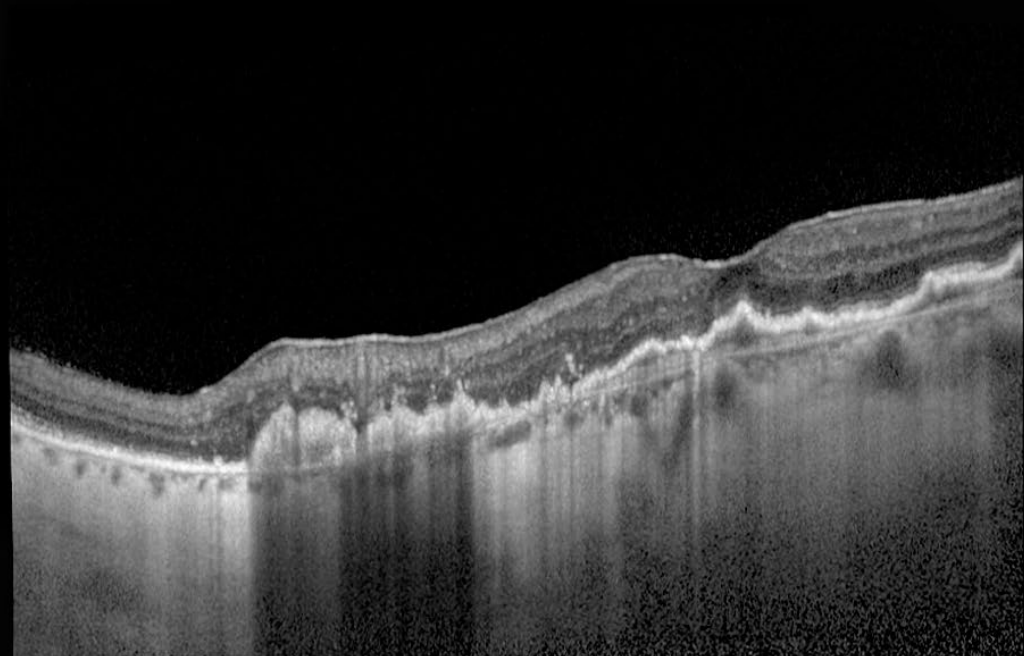
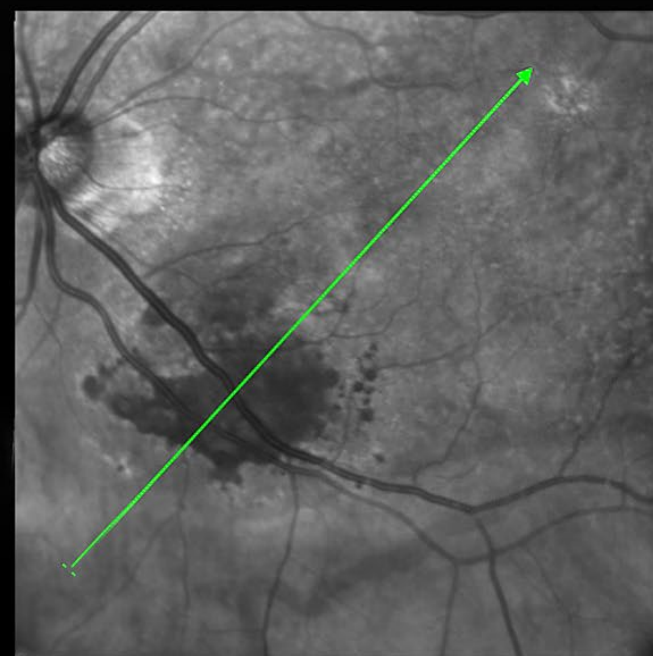
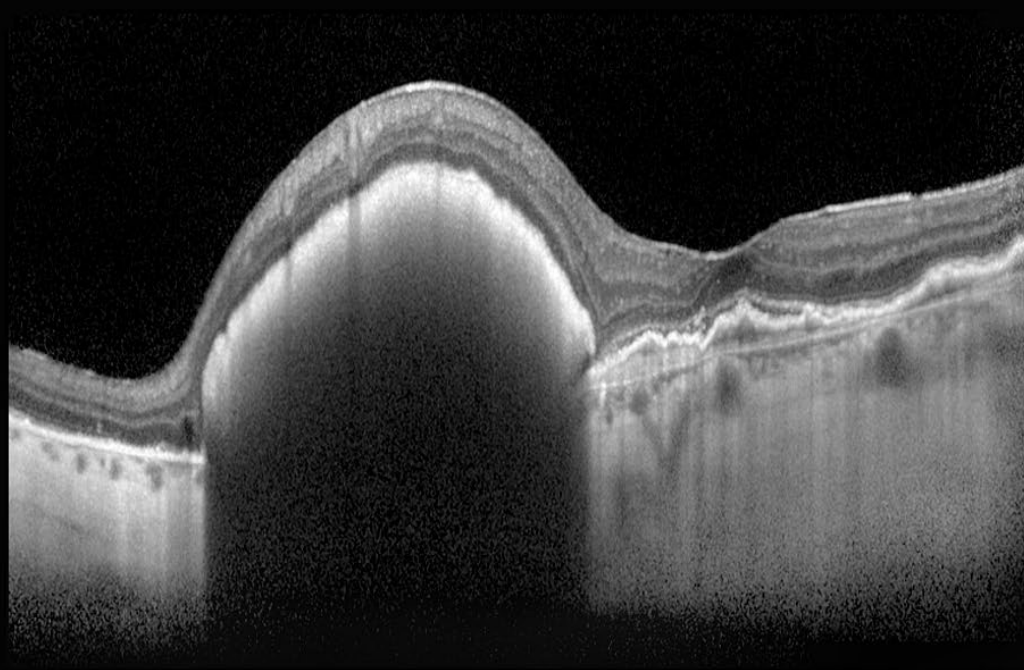
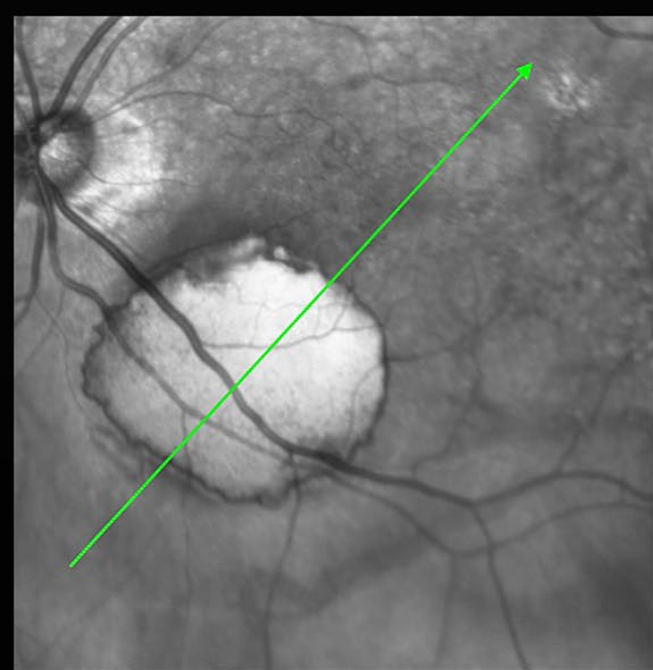
By: Jody Troyer, CRA
University of Iowa Hospitals
and Clinics Department of
Ophthalmology



Retinoschisis

By: Bradley Stern
Henry Ford
Health System



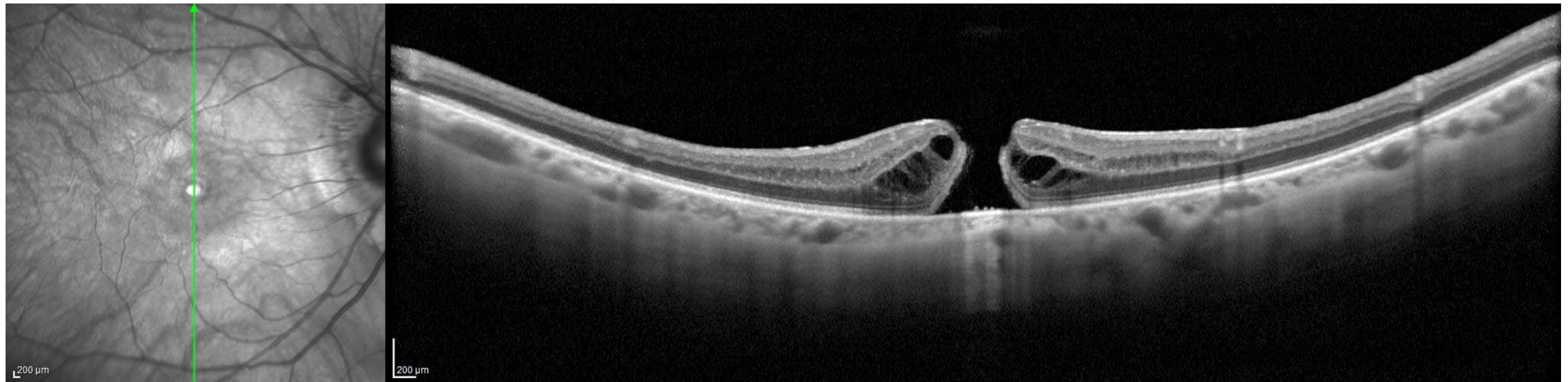


Subretinal
Hemorrhage
Resolution
By: Sean Grout,
OCT-C
UNC Hospital



Lamellar Hole

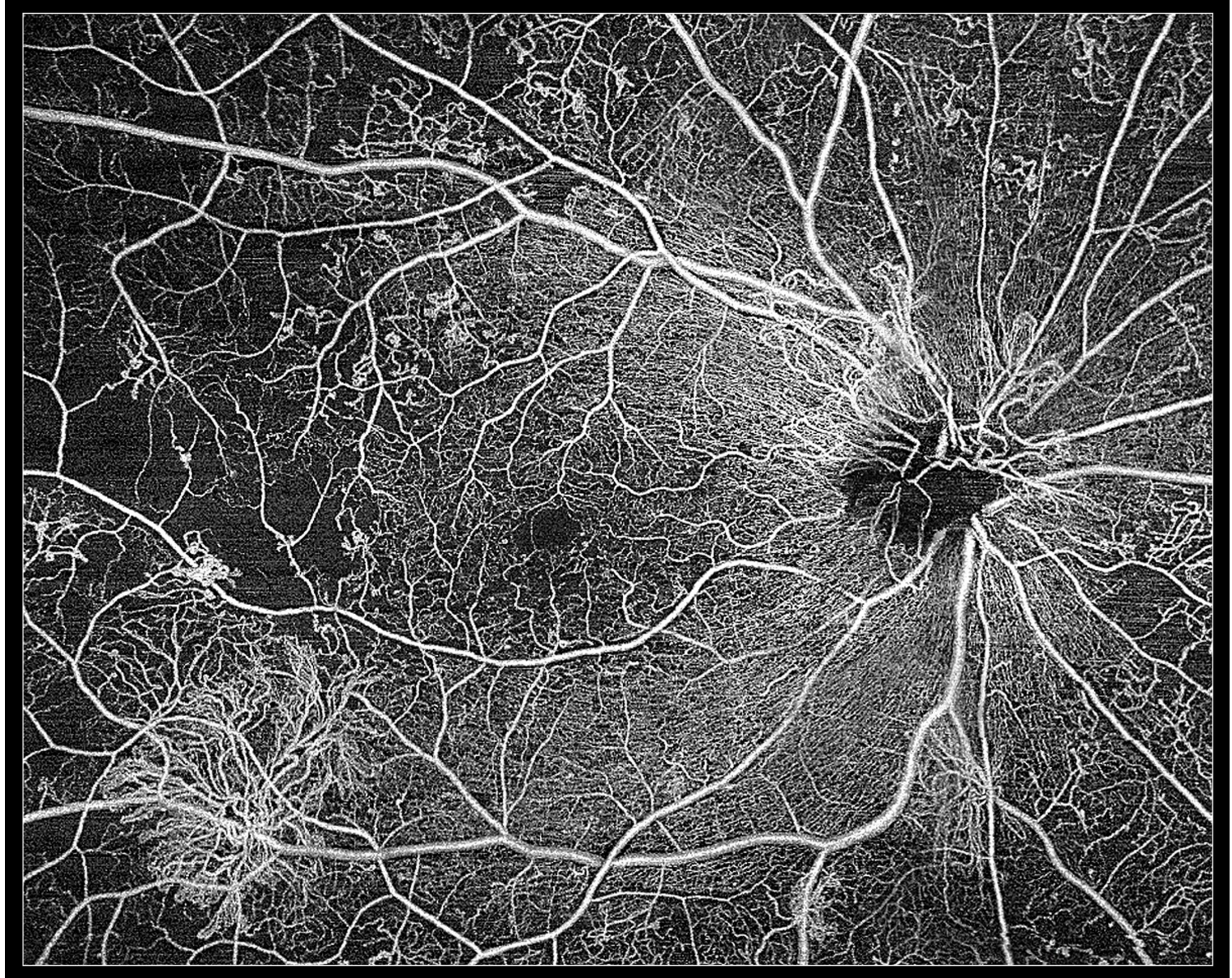
By: Anahli Jazhmin Vazquez-Galvan, OCT-C
Kresge Eye Institute



Optical Coherence Tomography Angiography

Proliferative Diabetic Retinopathy

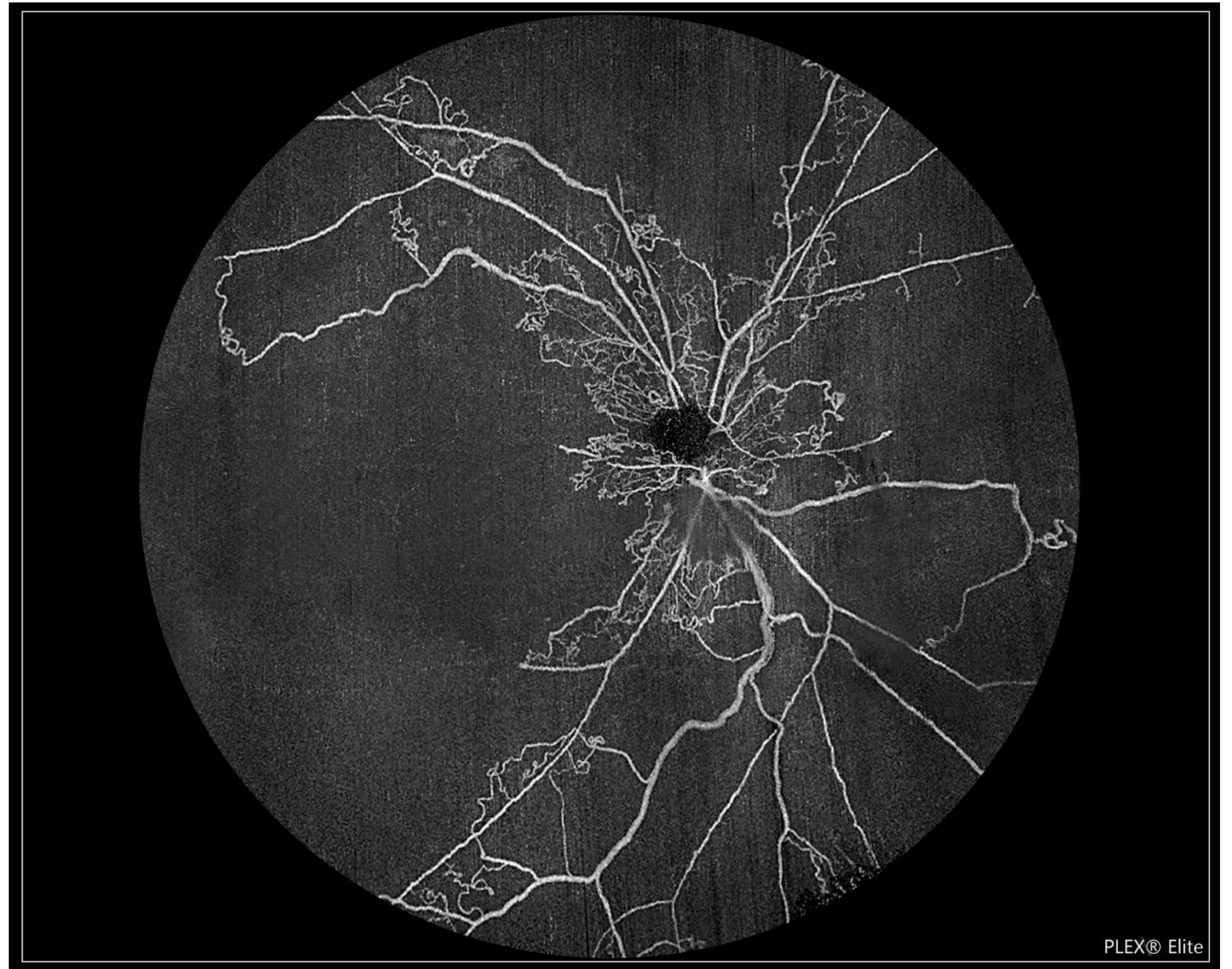
By: Kasi Sandhanam
Singapore National
Eye Center

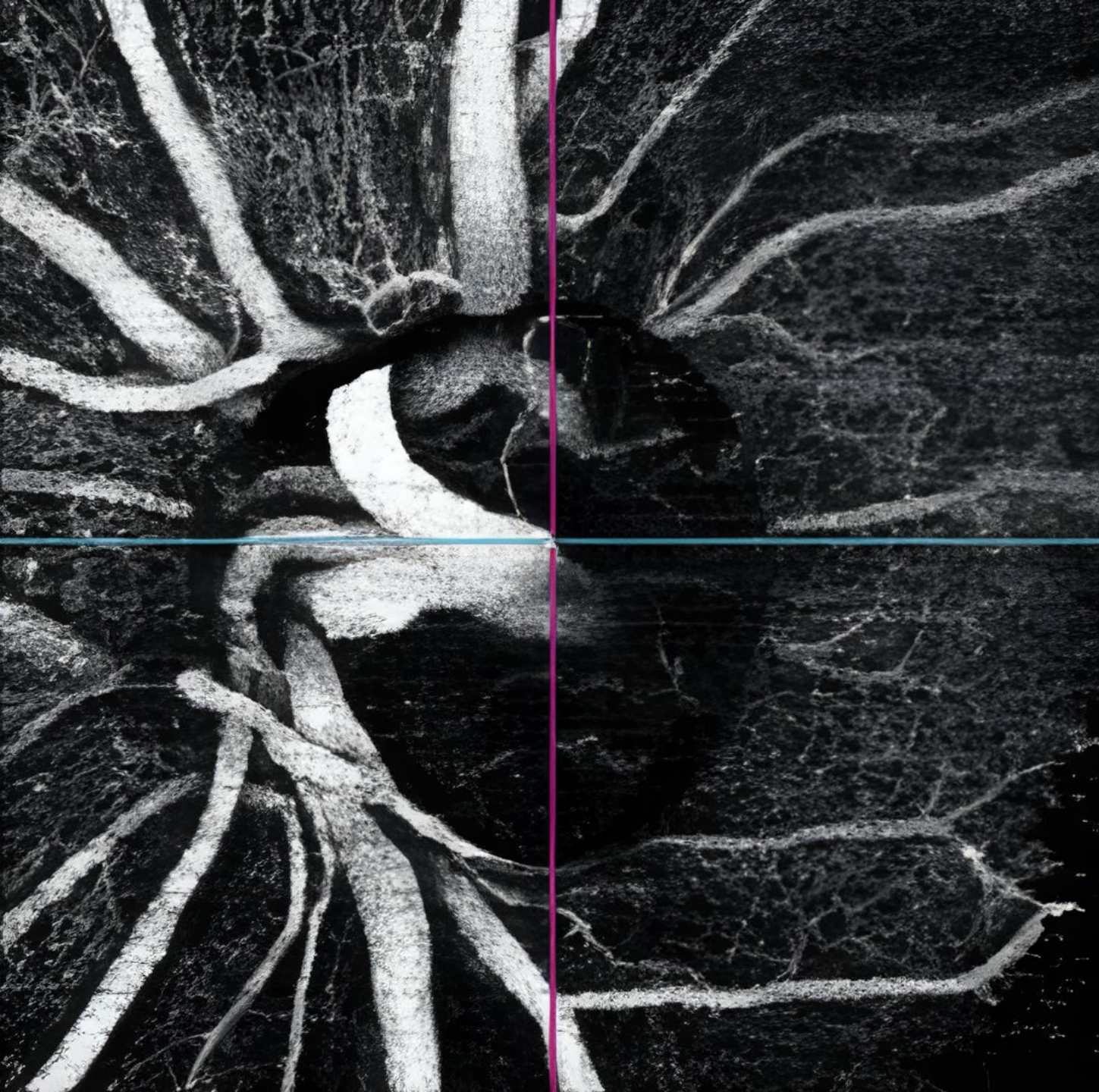




Ischemic Central Retinal Vein Occlusion

By: Kasi Sandhanam
Singapore National Eye Center





Y in the Well - Glaucomatous Optic Atrophy

By: Shruthy Vaishali
Ramesh

Mahathma Eye Hospital
Private Limited



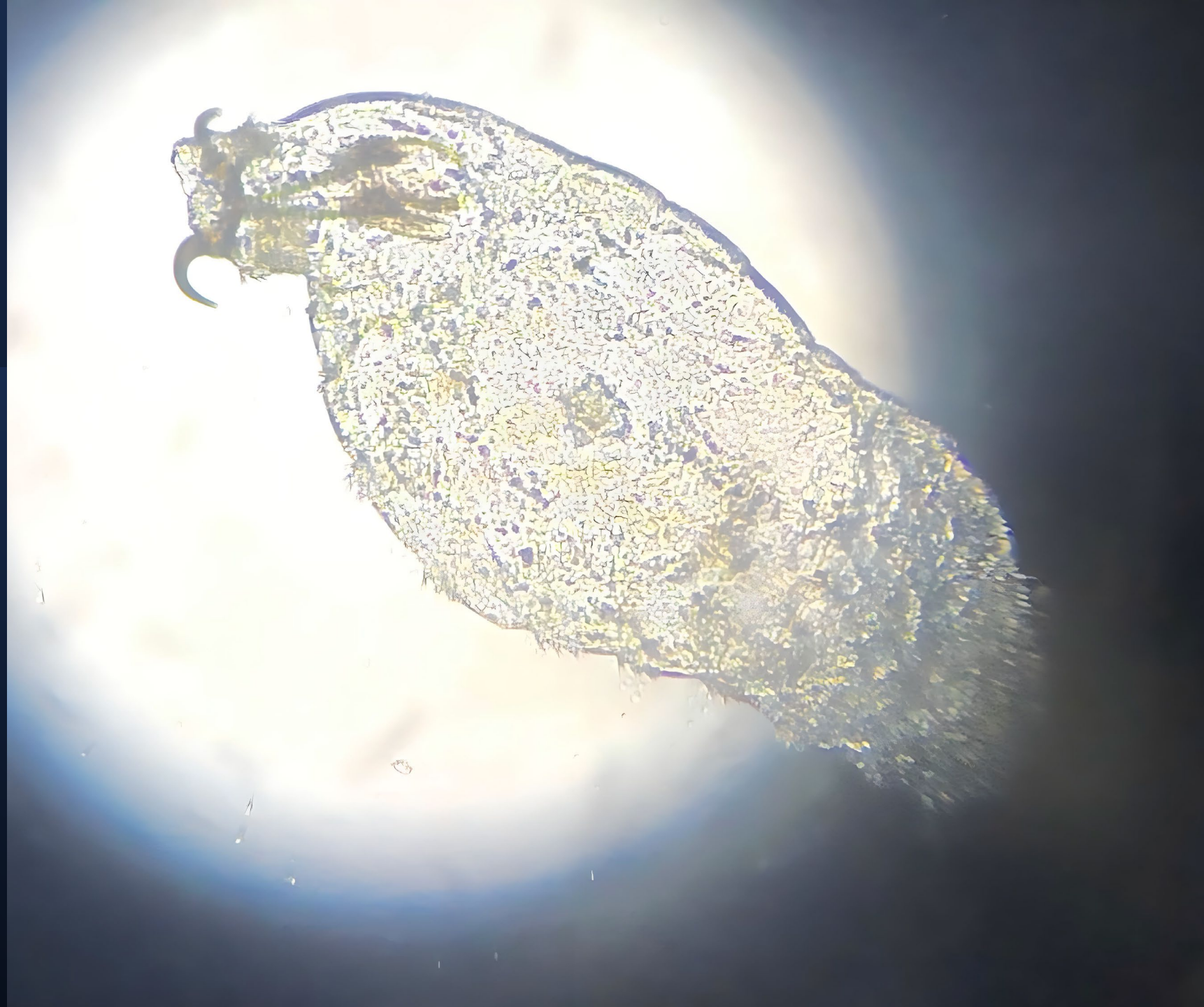Photo/Electron Micrography



Oestrus Ovis - Hook and Eye Closure

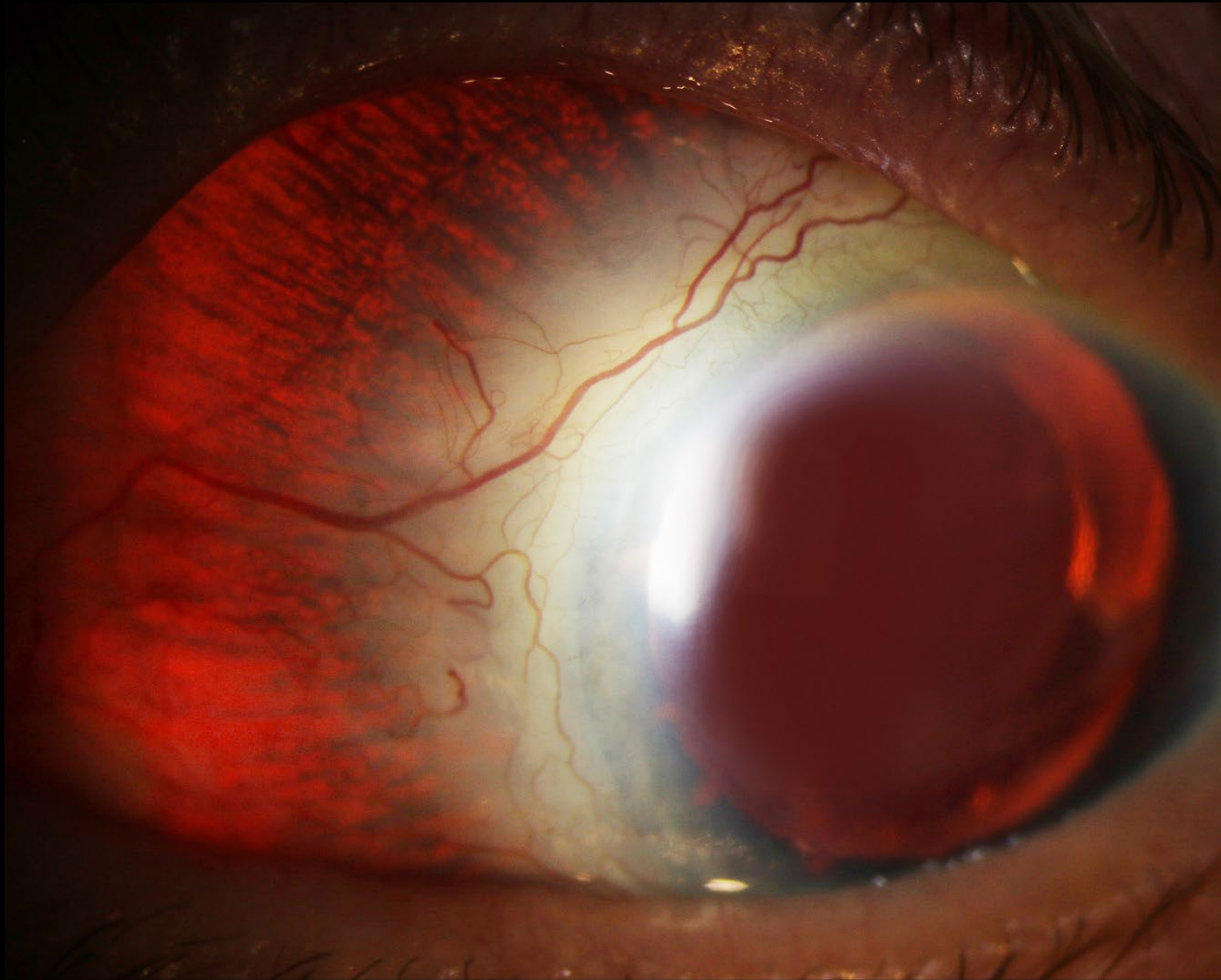
By: Prasanna Venkatesh
Ramesh

Mahathma Eye Hospital
Private Limited



Slitlamp Photography





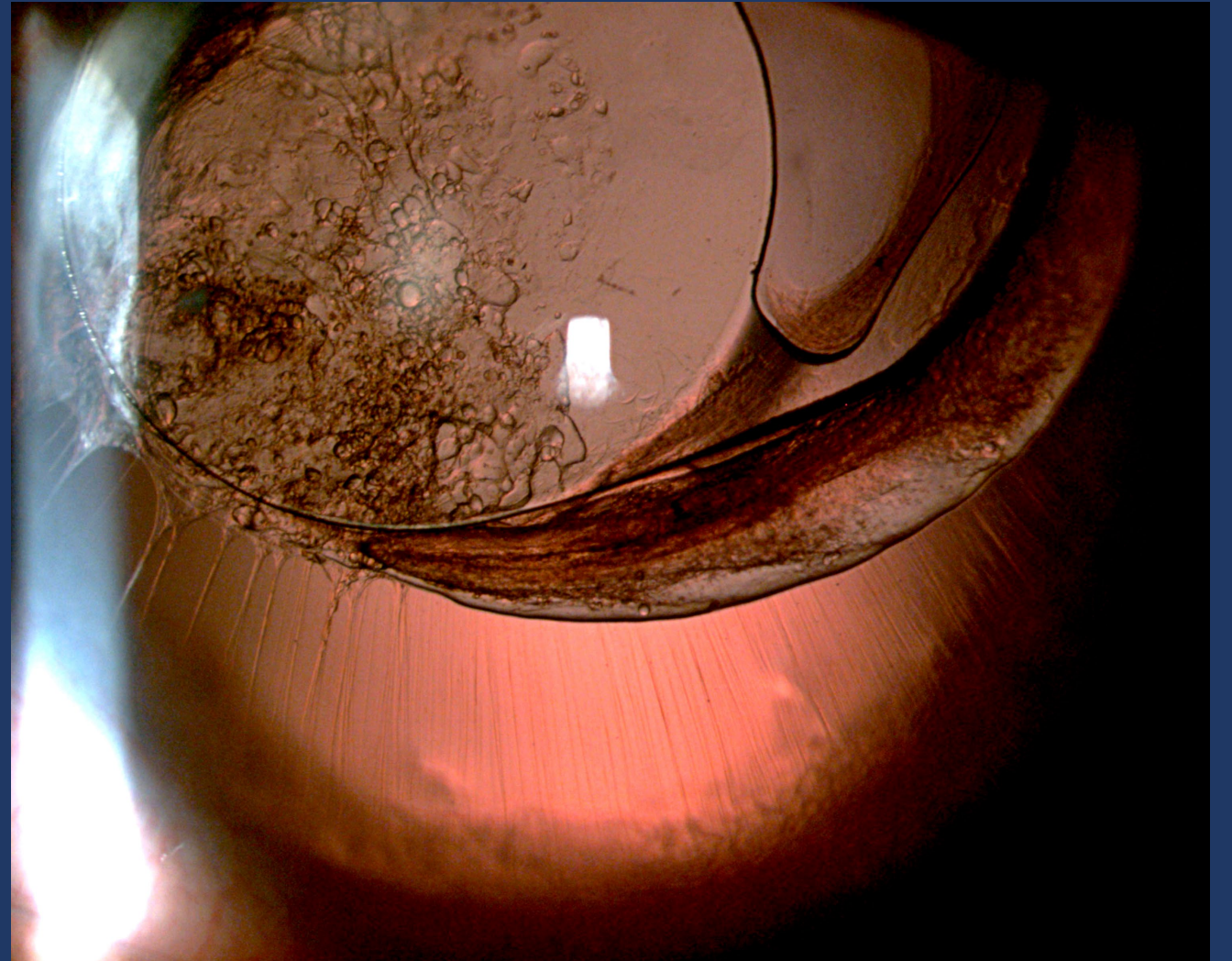
Necrotizing Scleritis

By: Veronica Jones
Duke Eye Center





Dislocated IOL in
Aniridia Eye
By: John Leo
Rajan Eye Care
Hospital Pvt Ltd






Corneal Nerves

By: Denice Barsness

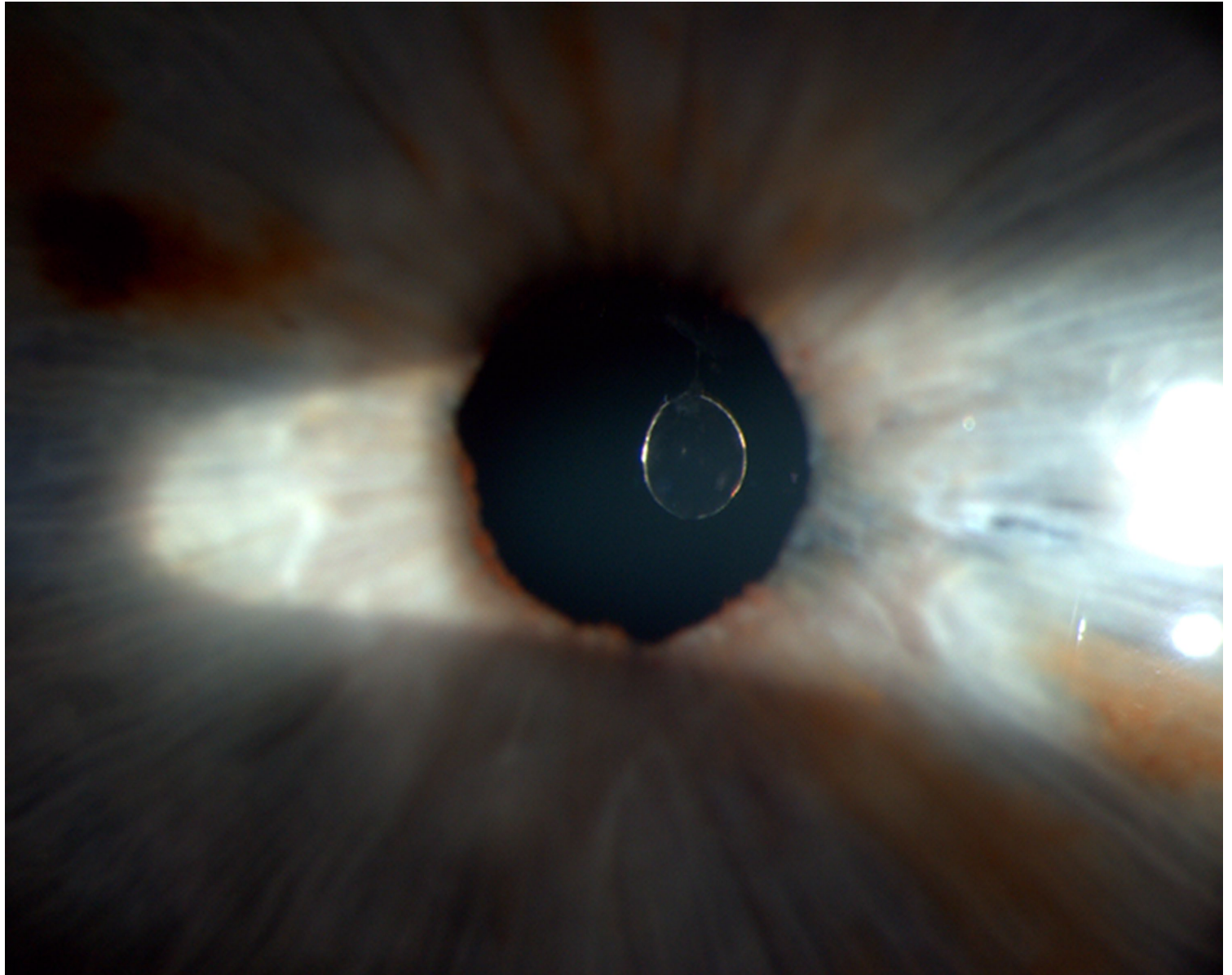
California Pacific

Medical Center Dept. of
Ophthalmology



Silicone Oil Droplet in Anterior Chamber

By: Darrin A. Landry,
CRA, OCT-C
Eyecare Medical
Group



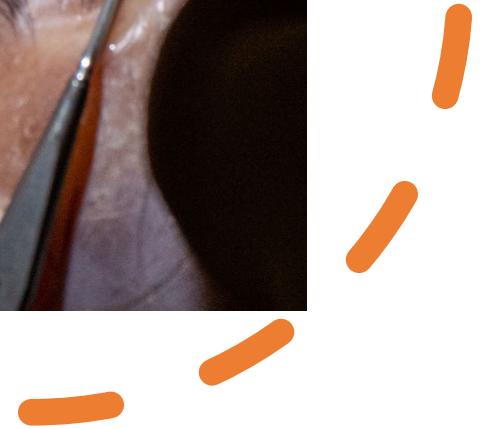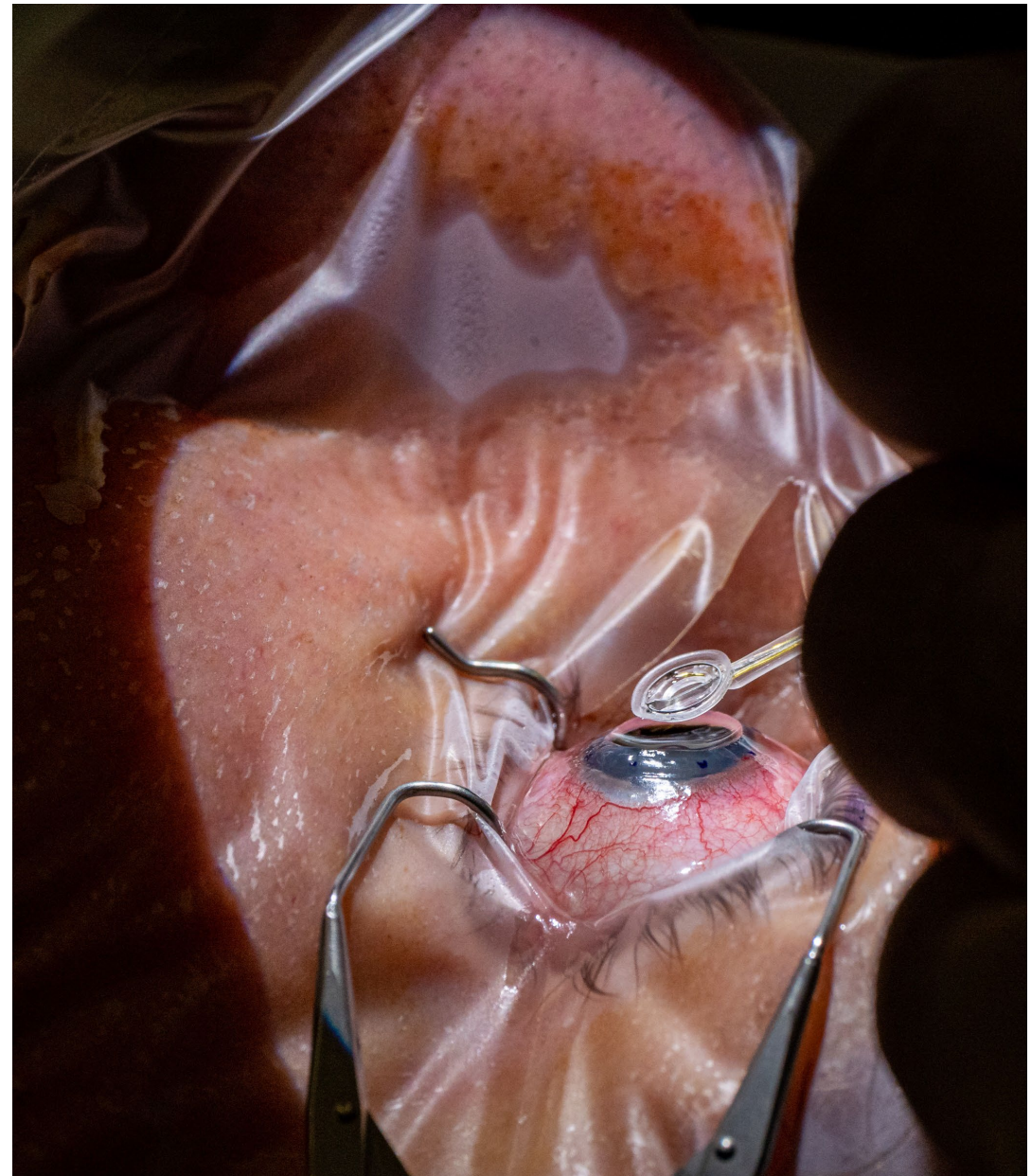Surgical Photography





Zepto Open Sky Capsulotomy

By: Mark C.
Vital, M.D.
Houston Eye
Associates



The Eye as Art



The Galactic Eye

By: Prasanna Venkatesh
Ramesh

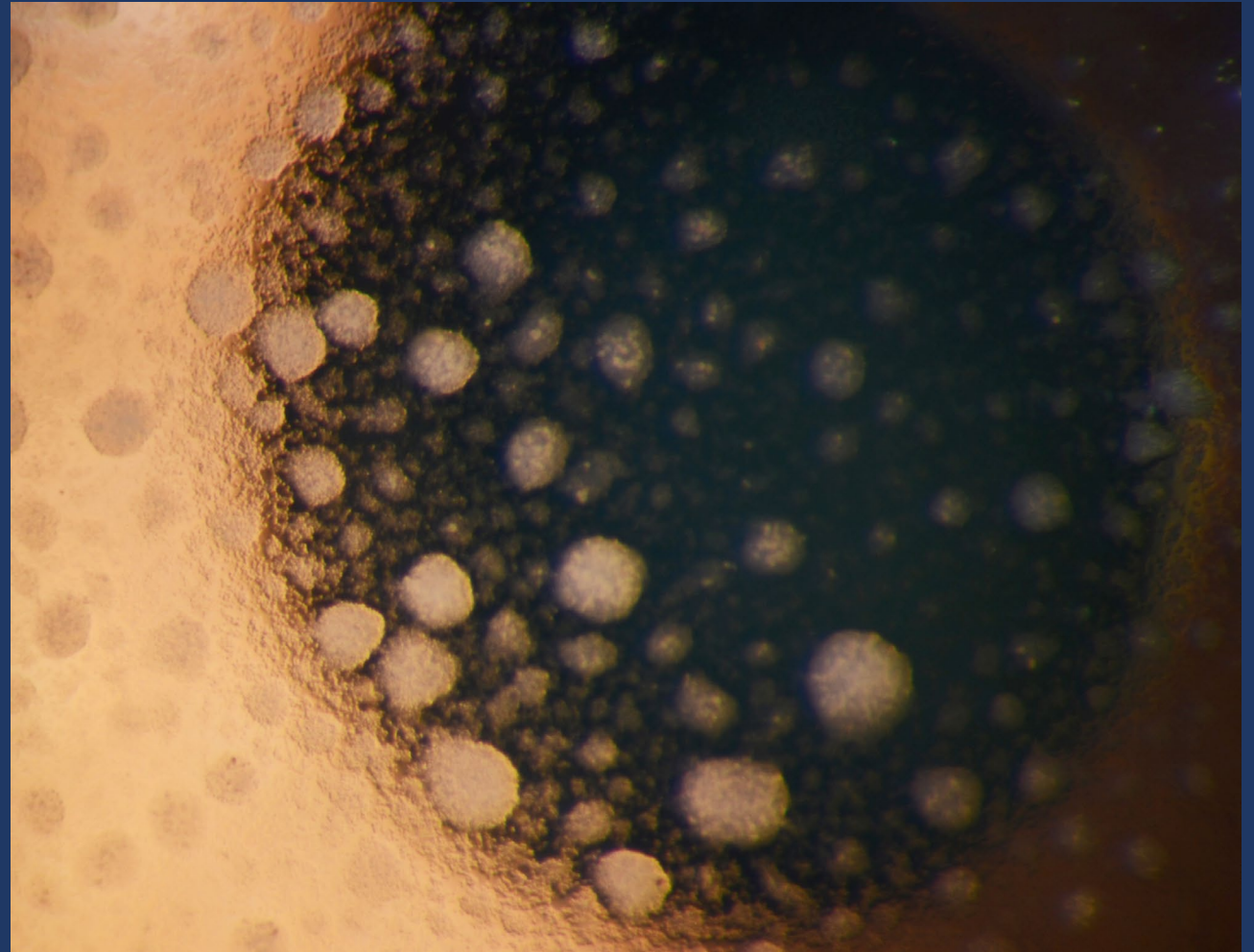
Mahathma Eye Hospital Private
Limited





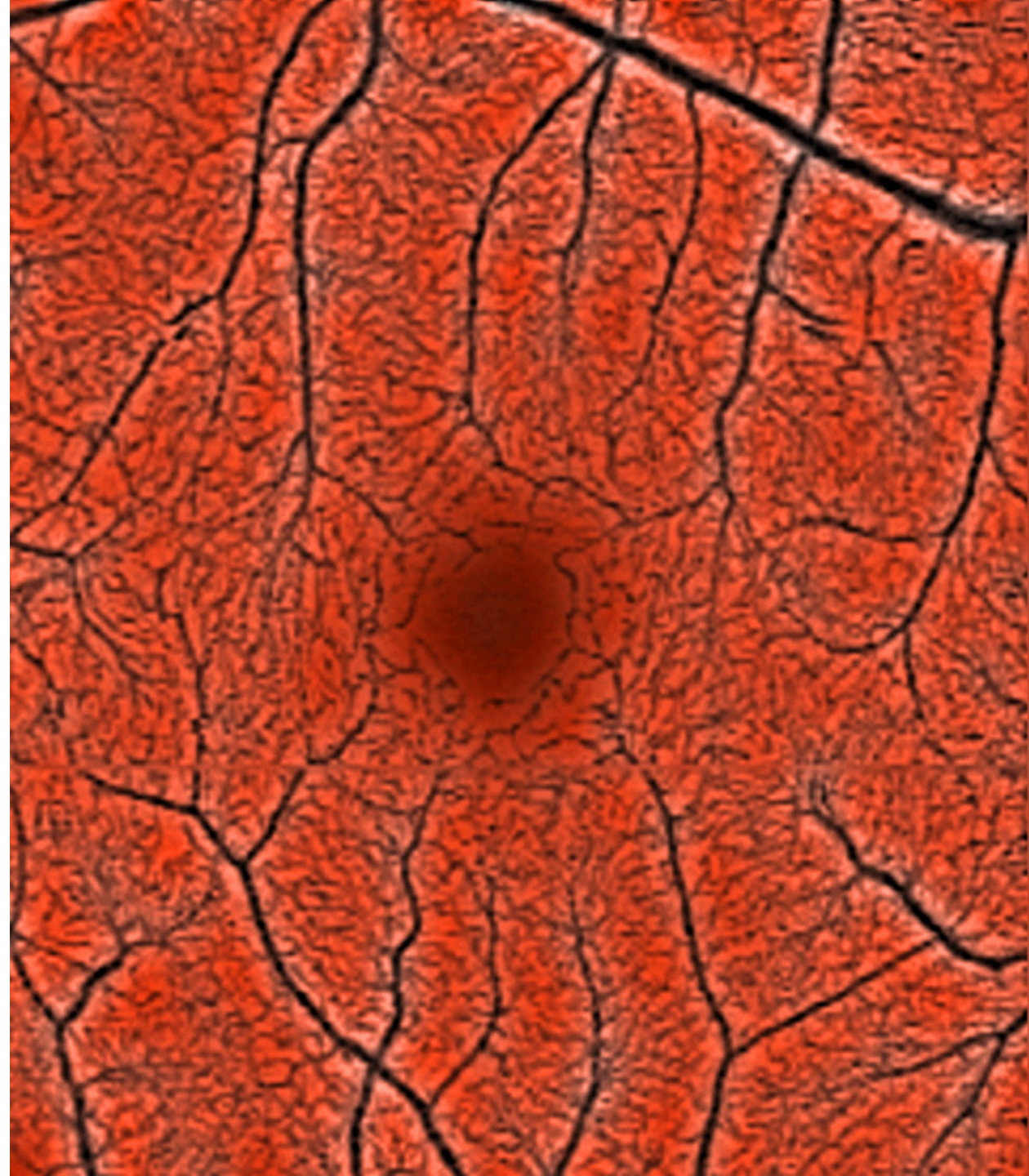
Mutton Fat


By: Denice Barsness
California Pacific
Medical Center Dept.
of Ophthalmology



Fovea

By: Darrin A.
Landry, CRA,
OCT-C
Eyecare Medical
Group





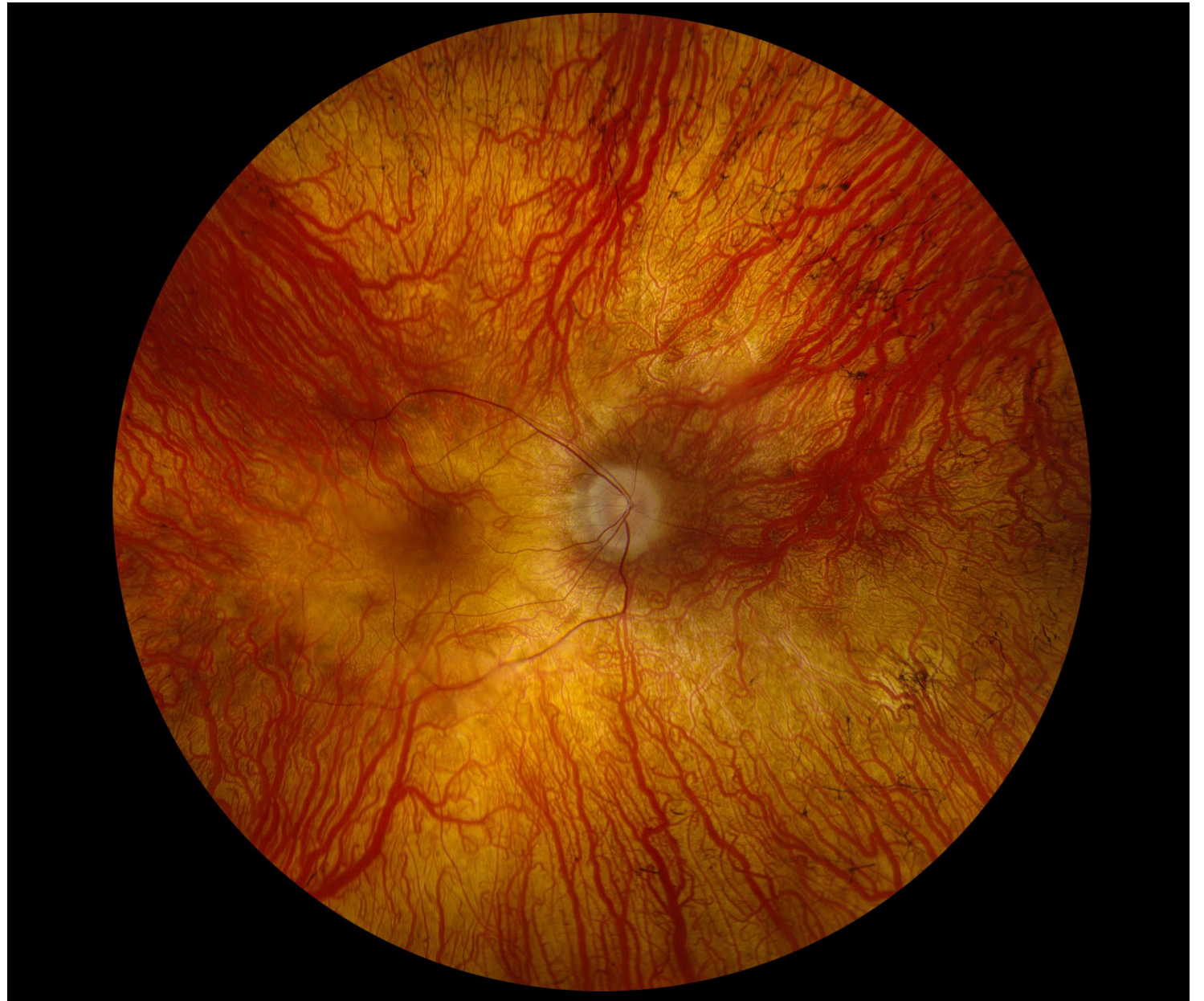The Optic Nerveheads Diagnosis: Rockeyetis

By: Sarah S Skiles
University of Iowa
Hospitals and Clinics

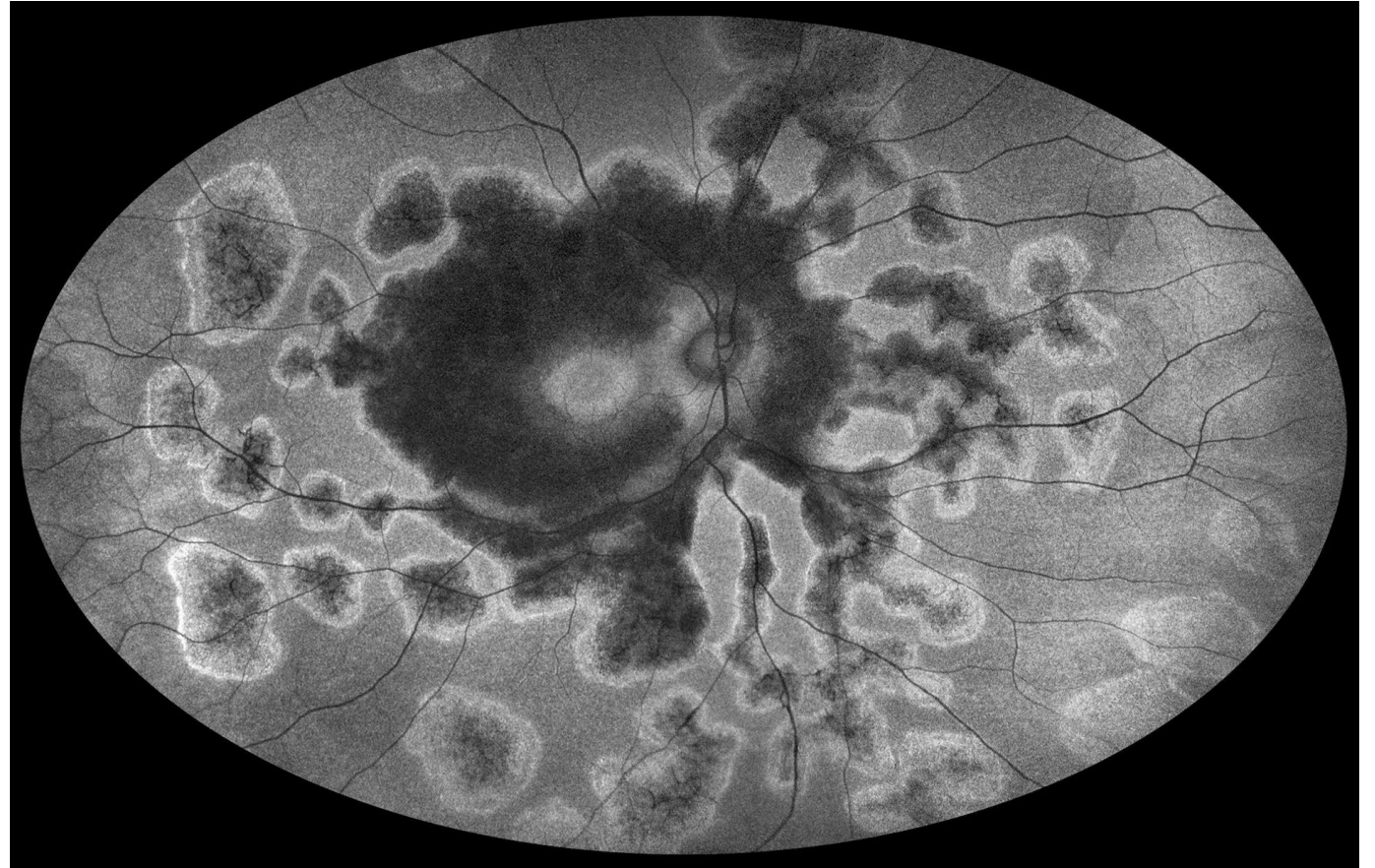

Ultra-Widefield Imaging $>60^\circ$
(all modalities)

RP
By: Tracey
Troszak
Henry Ford
Health System

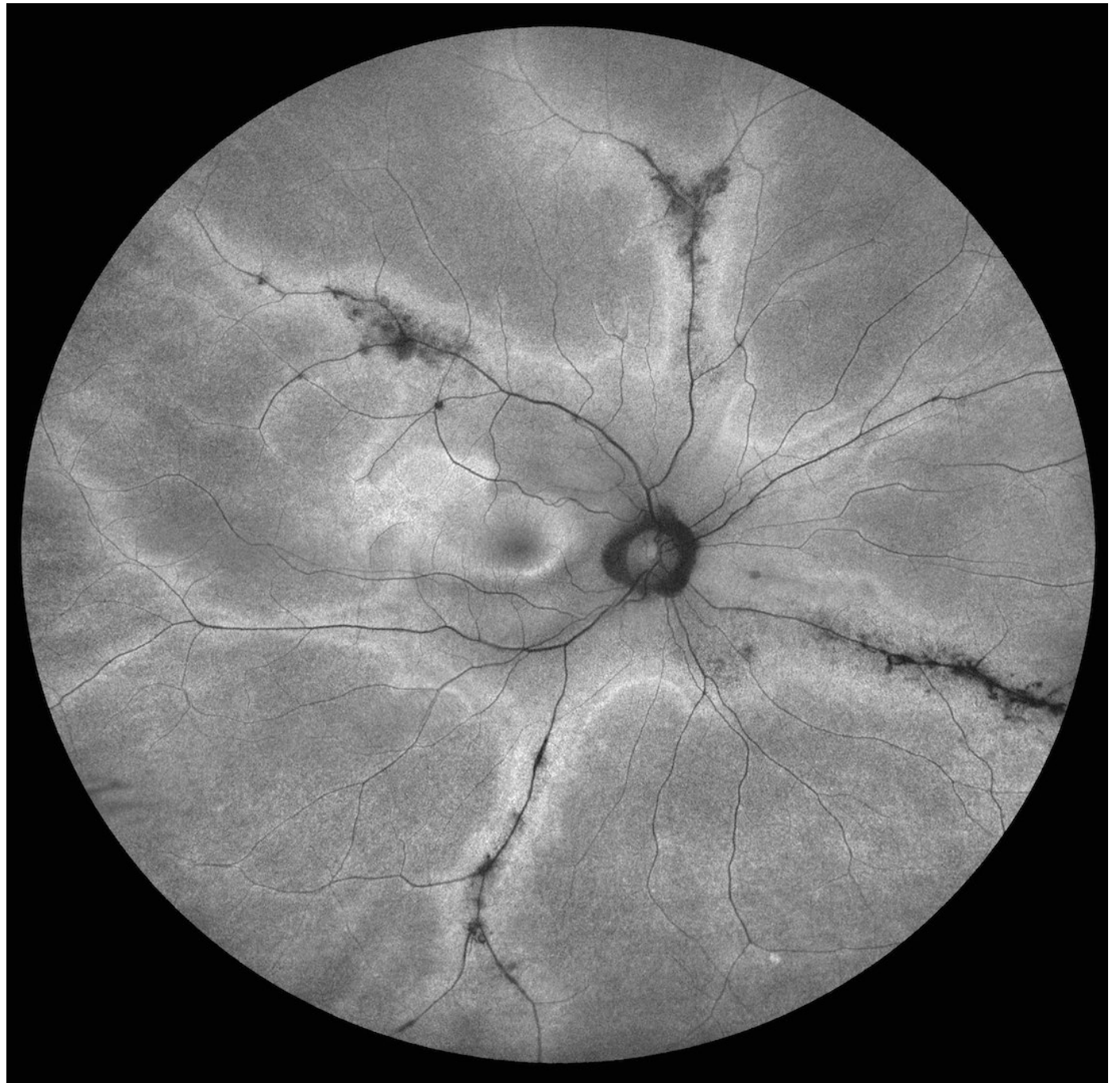


RDH12
Mutation
By: Sean Grout,
OCT-C
UNC Hospital



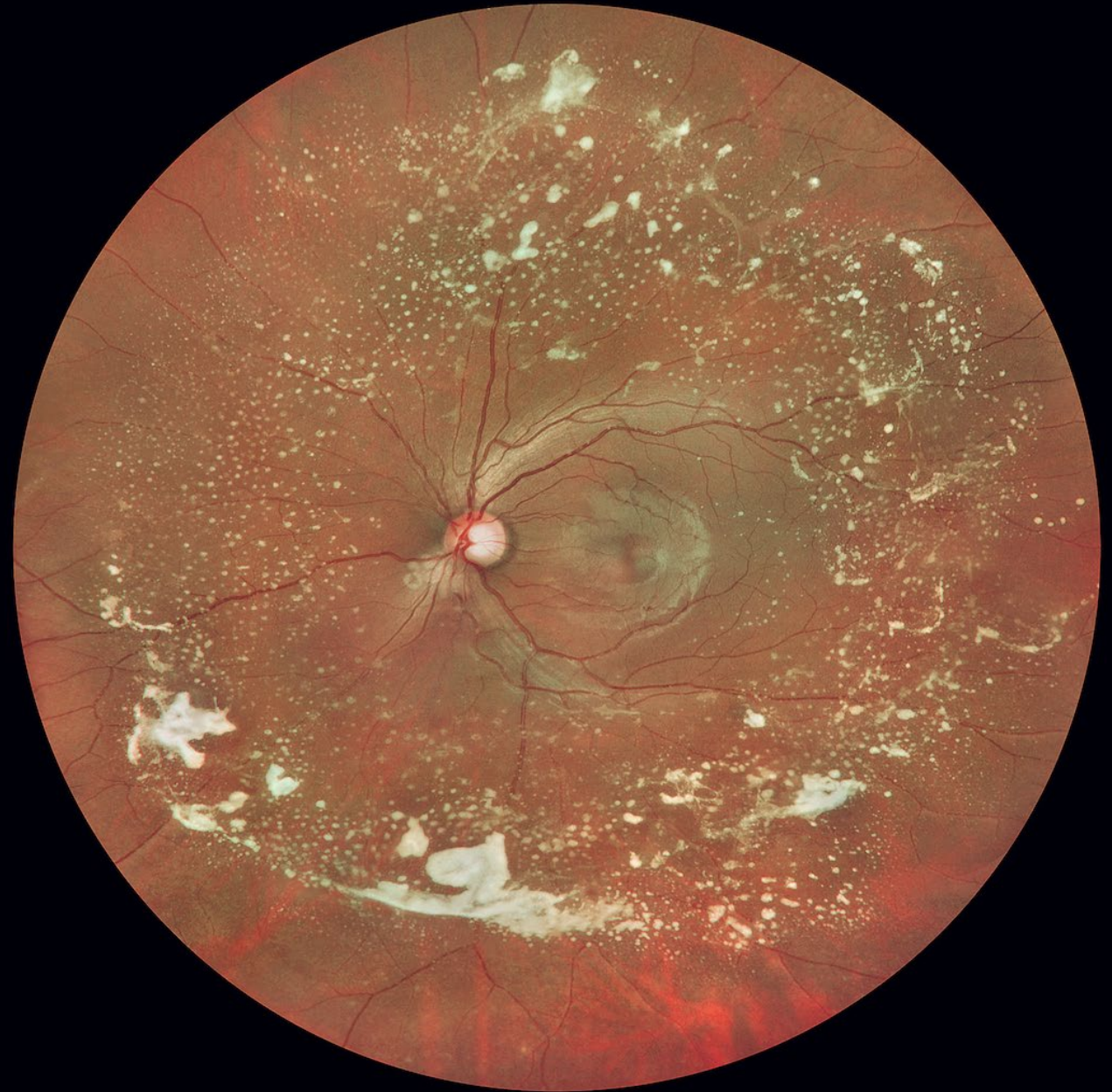
Pigmented Paravenous Retinochoroidal Atrophy

By: Sean Grout, OCT-C
UNC Hospital



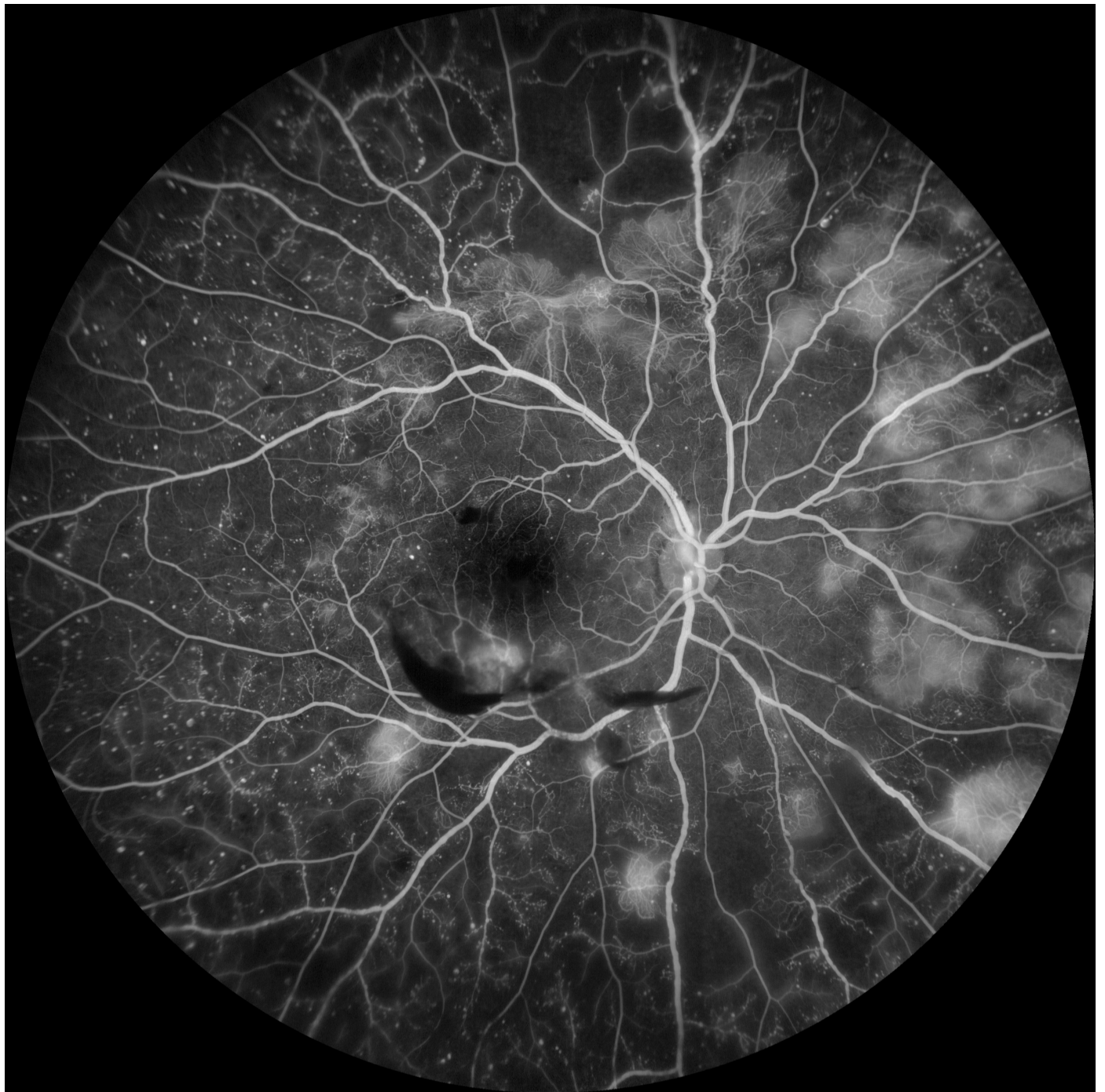
Gaucher's Disease

By: Sean Grout,
OCT-C
UNC Hospital



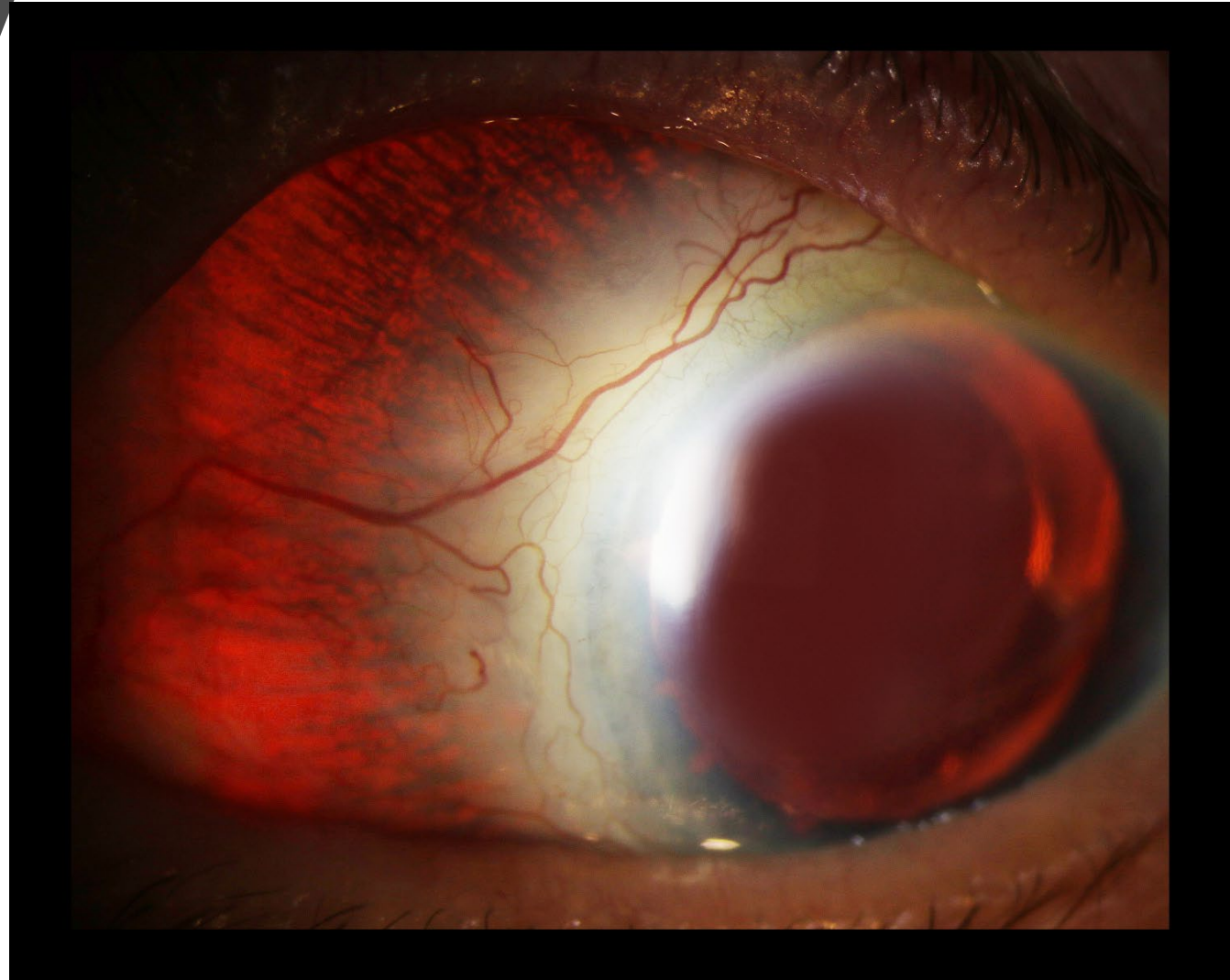
PDR

By: Bradley Stern
Henry Ford Health
System





BEST OF SHOW:
Necrotizing Scleritis
By: Veronica Jones
Duke Eye Center





OPHTHALMIC
PHOTOGRAPHERS'
SOCIETY
EYE IMAGING EXPERTS

